

CASE REPORT

Isolated sphenoid sinus lesion: A diagnostic dilemma

Sarmad Alazzawi¹, Tengku Shahrizal¹, Narayanan Prepageran¹, Jayalakshmi Pailoor²

Address for Correspondence:

Sarmad Alazzawi

¹Department of Otorhinolaryngology, Faculty of Medicine, University of Malaya, Kuala Lumpur, Malaysia

²Department of Pathology, Faculty of Medicine, University of Malaya, Kuala Lumpur, Malaysia
Email: dr.sarmad2001@yahoo.com

<http://dx.doi.org/10.5339/qmj.2014.10>

Submitted: 15 February 2014

Accepted: 22 June 2014

© 2014 Alazzawi, Shahrizal, Prepageran, Pailoor, licensee Bloomsbury Qatar Foundation Journals. This is an open access article distributed under the terms of the Creative Commons Attribution license CC BY 4.0, which permits unrestricted use, distribution and reproduction in any medium, provided the original work is properly cited.

Cite this article as: Alazzawi S, Shahrizal T, Prepageran N, Pailoor J. Isolated sphenoid sinus lesion: A diagnostic dilemma, Qatar Medical Journal 2014;10 <http://dx.doi.org/10.5339/qmj.2014.10>

ABSTRACT

Isolated sphenoid sinus lesions are an uncommon entity and present with non-specific symptoms. In this case report, the patient presented with a history of headaches for a duration of one month without sinonasal symptoms. A computed tomography scan showed a soft tissue mass occupying the sphenoid sinus. An endoscopic biopsy revealed fungal infection. Endoscopic wide sphenoidotomy with excision of the sphenoid sinus lesion was then performed however, the microbiological examination post-surgery did not show any fungal elements. Instead, *Citrobacter* species was implicated to be the cause of infection.

Keywords: sphenoid sinusitis, *Citrobacter*, sphenoid lesion, sinuses

INTRODUCTION

Isolated sphenoid sinus lesions are a relatively uncommon entity and account for 1 – 2.7% of all paranasal sinuses lesions.⁽¹⁾ Delayed diagnosis may occur due to its nonspecific symptoms. Isolated sphenoid sinus lesions most commonly present with headache, followed by ophthalmological and nasal symptoms.⁽²⁾ High index of suspicion is required for early diagnosis as endoscopic nasal examinations can be normal despite the presence of a sphenoid sinus lesion.⁽²⁾ Delayed or improper management of sphenoid sinus lesions may lead to serious complications such as orbital abscess, cavernous sinus thrombosis, meningitis, and epidural, subdural, or cerebral abscesses.⁽³⁾ This case illustrates the complexity encountered in the management of such lesions.

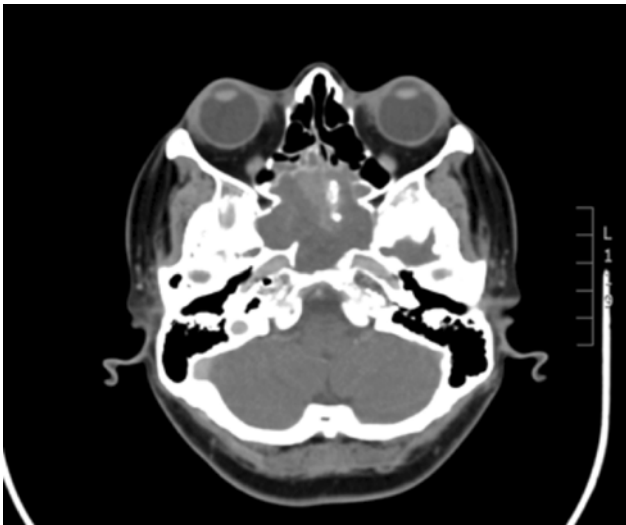


Figure 1. CT scan (with contrast) showing sphenoid sinus lesion with calcification.

CASE REPORT

A 43-year-old woman with known history of diabetes mellitus for ten years, which is poorly controlled despite being on oral hypoglycaemic medications, was referred to the Otorhinolaryngology clinic with a history of headaches for the duration of one month, which was progressively worsening over the week prior to presentation. The headache was retro-orbital extending to the occipital region. She denied sinonasal symptoms such as nasal discharge, postnasal drip or nasal obstruction and there was no history of vomiting, blurred vision, or trauma to the head. For one month prior to presentation, the patient was prescribed conventional analgesics by the general practitioner with no improvement. Physical examination did not reveal any neurological deficit and nasal endoscopy showed no evidence of sinonasal infection. A computed tomography (CT) scan was performed at the emergency unit prior to her referral to our clinic which revealed a soft tissue mass occupying the sphenoid sinus causing expansion of the sinus. The mass showed calcifications with minimal enhancement (Figure 1). A sphenoid sinus tumor was suspected and therefore magnetic resonance imaging (MRI) was carried out. This revealed the same findings with those of the CT scan, with no obvious intracranial extension.

The patient was admitted to the hospital. A biopsy was planned, and a transnasal endoscopic sphenoidotomy was carried out revealing greenish-white

material with crustation. Histopathological examination (HPE) of the biopsy specimen revealed colonies of fungi admixed with acute inflammatory cells. Minimal superficial respiratory epithelium was noted. Gomori methenamine stain showed septate thick-walled fungi resembling mucormycosis (Figure 2). Intravenous anti-fungal treatment (Amphotericin B) was started as adjuvant therapy based on the HPE result in preparation for definitive surgical debridement.

An endoscopic excision with wide sphenoidotomy was performed soon after. All the debris and crustation were cleared out (Figure 3). There was no obvious involvement of the sphenoid sinus mucosa, and all its walls appeared intact. The patient felt well and headache free in the post-operative days. Amoxicillin-clavulanate was given for two weeks as part of the post-operative medications.

Interestingly, the HPE showed inflammatory exudates and colonies of bacteria. No fungus or malignancy was noted. The microbiological examination did not show any fungal elements instead, gram-negative rods (*Citrobacter* species) were implicated to be the cause of infection and were found to be sensitive to the amoxicillin-clavulanate. Therefore, no further antibiotic therapy was given to the patient.

Repeat CT scan was performed three weeks post-operatively and a clear sphenoid sinus was seen (Figure 4). The patient was seen during follow-up and was symptom free, and nasal endoscopic examination showed clear sphenoid sinus with healthy mucosa.

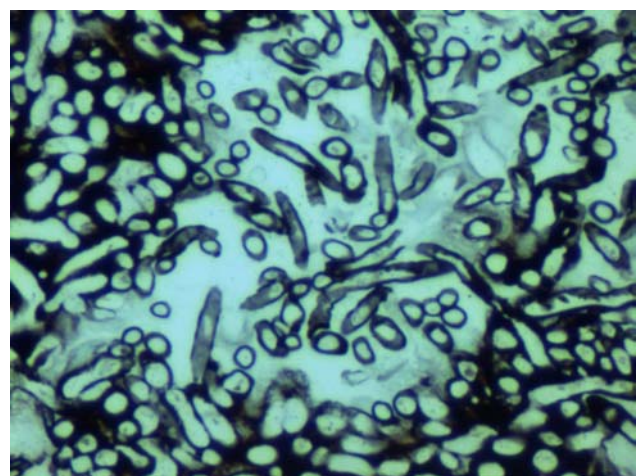


Figure 2. Septate thick-walled fungi. Gomori methanamine stain $\times 400$.

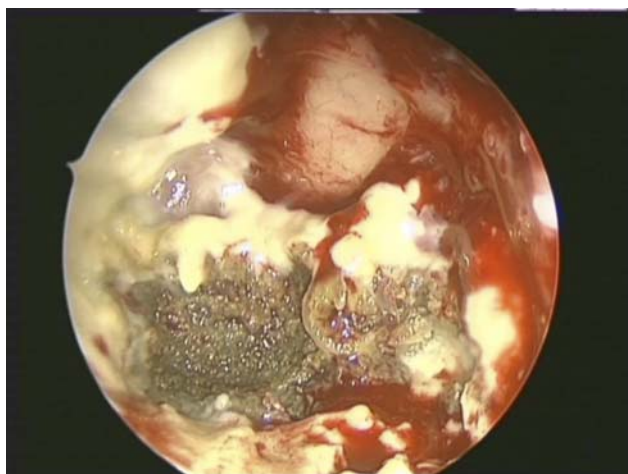


Figure 3. Endoscopic view showing infected material inside the sphenoid sinus.

DISCUSSION

Inflammatory conditions appear to be the major cause of sphenoid sinus lesions accounting for 65–72% of cases, followed by neoplasm (benign and malignant) accounting for 16–17.5%.^(2,4)

Friedman et al.⁽⁴⁾ reviewed 50 patients with isolated sphenoid sinus lesions and 72% of the cases were due to inflammatory causes which included: chronic sinusitis 34%, fungal ball 20%, mucocele 12%, acute sinusitis 4%, and chronic invasive fungal sinusitis 2%. Neoplasms were seen in 16% of patients (benign 10%, malignant 6%). Other conditions such as cerebrospinal fluid leak and fibrous dysplasia were seen in 12%. A wide variety of other organisms can cause sphenoid sinusitis. In the study by Friedman,⁽⁴⁾ twenty-five of the 29 patients with inflammatory sphenoid sinus lesions had positive cultures, 68% of the cultures were positive for bacteria with methicillin-resistant *Staphylococcus aureus* being the most common pathogen, followed by *Pseudomonas aeruginosa*. 32% of the cultures grew fungal organisms, with *Aspergillus* species being the most common.

The first HPE of the patient following the biopsy showed signs of fungal infection while the second following the endoscopic excision showed bacterial infection. This led us to two contradicting results despite having the same examiner reporting the biopsy on both occasions. It was therefore concluded that a mixed infection was the most probable cause of the lesion and that with the administration of the broad-spectrum antibiotics prescribed by the general

practitioner, this had caused suppression of the bacterial growth in the first biopsy, giving a picture of a predominantly fungal infection. However, the course of anti-fungal treatment had reversed the picture by suppressing the growth of the fungus, thus allowing the bacterial infection to predominate.

The culture in our case showed *Citrobacter* species, which are facultative anaerobic, motile, gram-negative bacilli that belong to the family Enterobacteriaceae.⁽⁵⁾ They are widely distributed in soil, food, water and the intestinal tracts of humans and animals; these bacilli were previously regarded as environmental contaminants or harmless colonizers.⁽⁵⁾ However, recent studies emphasize that they can cause serious infections, especially in neonates and immuno-compromised adults and older children.^(6,7)

In a large case series by Lawson and Reino,⁽⁸⁾ 132 cases of isolated sphenoid sinus diseases were reviewed. Headache was the most common presenting symptom, followed by visual changes and cranial nerve palsies. In our case, headache was the only presenting symptom making the diagnosis difficult.

Lee et al.⁽⁹⁾ reviewed 13 cases of isolated sphenoid sinus lesions with visual disturbances. Eight eyes had vision loss due to compressive optic neuropathy and optic neuritis; seven eyes had diplopia most commonly due to abducens nerve palsy followed by oculomotor nerve palsy.

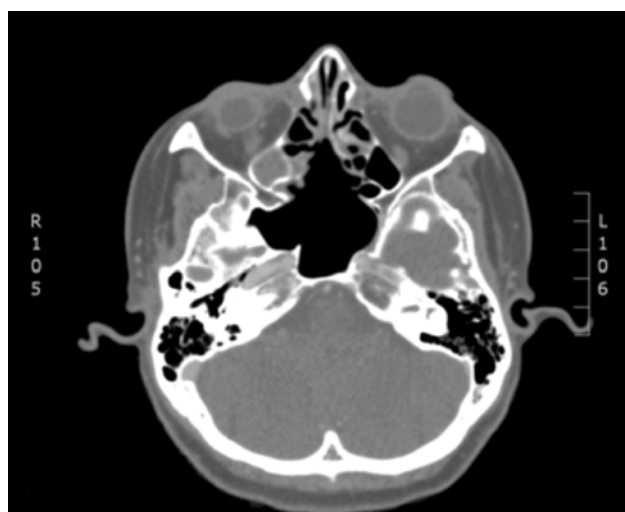


Figure 4. Post-operative CT scan (with contrast) showing clear sphenoid sinus.

The sphenoid sinus is surrounded by vital structures including the dura, pituitary, optic nerve, pterygoid canal and nerve, internal carotid artery and the cavernous sinus with its associated cranial nerves (III, IV, V1, V2, and VI).⁽¹⁰⁾ Early management of sphenoid sinus lesions is therefore crucial to prevent complications that may occur due to involvement of these structures.

CT scan images in this case showed expansion of the sphenoid sinus. However, the walls were intact and there was no sign of erosion.

Treatment options depend on the diagnosis. Medical management is advisable for infectious and inflammatory sphenoid sinusitis. While systemic antibiotics are used for bacterial causes, systemic antifungal therapy is indicated as adjuvant therapy⁽¹¹⁾ if an invasive fungal infection is the culprit. Surgical management is the treatment of choice for most sphenoid sinus lesions.^(2,4)

Nour et al.⁽²⁾ reviewed 40 patients with isolated sphenoid sinus lesions, 35 of them had undergone endoscopic surgery under general anesthesia. Three approaches were used to access the sphenoid sinus: endoscopic transnasal approach, endoscopic

transeptal approach and endoscopic transpterygoid approach.

Choosing the specific approach depends on the diagnosis, location and extent of the disease, availability of surgical equipment, and the surgical experience.⁽²⁾

An intra-operative use of image-guided surgery (IGS) can help to navigate the complex anatomy of the skull base and reduce the risk of damage to the vital surrounding structures and is therefore advisable in cases where the anatomical landmarks have been obliterated by tumour or previous surgery.⁽¹²⁾

CONCLUSION

Isolated sphenoid sinus lesions are an uncommon entity, with nonspecific clinical presentation. Early diagnosis requires a high index of suspicion, proper endoscopic examination and appropriate radiological imaging.

In cases where mixed infection is suspected, surgery is the mainstay of treatment especially with the advancement of endoscopic sinus surgery. IGS is advisable for the more complicated lesions.

REFERENCES

1. Wang ZM, Kanoh N, Dai CF, Kutler DI, Xu R, Chi FL, Tian X. Isolated sphenoid sinus disease: an analysis of 122 cases. *Ann Otol Rhinol Laryngol*. 2002;111:323–327.
2. Nour YA, Al-Madani A, El-Daly A, Gaafar A. Isolated sphenoid sinus pathology: Spectrum of diagnostic and treatment modalities. *Auris Nasus Larynx*. 2008;35:500–508.
3. Goldman A. Complications of sphenoid sinusitis. *Oper Techn Otolaryngol*. 2003;14:216–218.
4. Friedman A, Batra PS, Fakhri S, Citardi MJ, Lanza DC. Isolated sphenoid sinus disease: etiology and management. *Otolaryngol Head Neck Surg*. 2005;133:544–550.
5. Holmes B, Aucken HM. Citrobacter, Enterobacter, Klebsiella, Serratia and other members of the Enterobacteriaceae. In: Collier L, Balows A, Sussman M, eds. *Topley and Wilson's microbiology and microbial infections*, vol. 2. 9th ed. New York: Oxford University Press; 1998:999–1033.
6. Lipsky BA, Hook EW 3rd, Smith AA, Plorde JJ. Citrobacter infections in humans: experience at the Seattle Veterans Administration Medical Center and a review of the literature. *Rev Infect Dis*. 1980;2:746–760.
7. Mohanty S, Singhal R, Sood S, Dhawan B, Kapil A, Das BK. Citrobacter infections in a tertiary care hospital in Northern India. *J Infect*. 2007;54:58–64.
8. Lawson W, Reino AJ. Isolated sphenoid sinus disease: an analysis of 132 cases. *Laryngoscope*. 1997;107:1590–1595.
9. Lee LA, Huang CC, Lee TJ. Prolonged visual disturbance secondary to isolated sphenoid sinus disease. *Laryngoscope*. 2004;114:986–990.
10. Van Alyea OE. Sphenoid sinus: anatomic study with consideration of the clinical significance of the structural characteristics of the sphenoid sinus. *Arch Otolaryngol*. 1941;34:225–253.
11. Chakrabarti A, Das A, Panda NK. Overview of fungal rhinosinusitis. *Indian J Otolaryngol Head Neck Surg*. 2004;56(4):251–258.
12. Carrau RL, Snyderman CH, Curtin HD, Janecka IP, Stechison M, Weissman JL. Computer-assisted intraoperative navigation during skull base surgery. *Am J Otol*. 1996;17:95–101.