

The management of septic shock and Ludwig's angina: A case report of a life-threatening condition

SAGE Open Medical Case Reports
Volume 8: 1–5
© The Author(s) 2020
Article reuse guidelines:
sagepub.com/journals-permissions
DOI: 10.1177/2050313X20930909
journals.sagepub.com/home/sco



Endang Sjamsudin¹, Basaria Manurung¹, Asri Arumsari²
and Tantry Maulina¹ 

Abstract

Ludwig's angina is a high severity infection because of the risk of airway obstruction due to the rapid spread of the abscess into the deeper spaces. Therefore, performing the correct treatment is one of the keys to a successful result. A 44-year-old male patient came to the Emergency Unit of Hasan Sadikin Hospital, complaining of shortness of breath, severe pain, and progressive swelling. Extraoral examination showed a localized-fluctuated swelling located at the right lower jaw that extended to the chin, left lower jaw, and the frontal region of the neck region while a sequential organ failure assessment revealed a score of 2. A diagnosis of Ludwig's angina and septic shock was confirmed. Intravenous infusion of norepinephrine was administered and a tracheostomy was performed. The next treatment phase consisted of a drainage procedure, tooth extraction, and placement of the Penrose drain. The patient was discharged 10 days later with a satisfactory outcome.

Keywords

Septic shock, Ludwig's angina, Ludwig's angina management

Date received: 26 September 2019; accepted: 11 May 2020

Introduction

Ludwig's angina is a form of acute severe diffuse cellulitis of the maxillofacial region that has been described as bilateral involvement of the sublingual, submental, and submandibular spaces.^{1–3} Because the location of these spaces is inferior to the tongue base, infections in these areas can result in elevation of the floor of the mouth and posterior displacement of the tongue base into the airway,^{3,4} and could lead to death. This is one of the reasons why Ludwig's angina is considered a life-threatening condition. Not to mention that there is another complication such as septic shock.⁴ Septic shock, which is defined as "a subset of sepsis with particularly profound circulatory, cellular, and metabolic abnormalities associated with a greater risk of mortality than sepsis alone" has an in-hospital mortality rate as high as 40%.⁵

The deep neck spaces can be potentially threatening because swelling in these spaces can readily displace, efface, or obstruct the airway.^{1,6} Furthermore, infection in the deep neck spaces can rapidly spread inferiorly to threaten the mediastinum and its contents.^{1,7,8} Accurate determination of the anatomic location of the infection will allow an accurate assessment of the severity of the infection.^{1,9,10} When

assessing the severity of an infection, one must consider the infection's rate of progression.^{1,4} A case report of Ludwig's angina that required complex and immediate management due to the life-threatening condition of the patient is presented in the following section.

Case report

A 44-year-old male patient complaining of dyspnea, severe pain, and progressive swelling in his jaw and neck for the last 14 days came to our emergency unit. Due to the rapidly extending swelling, he was hospitalized for 5 days in a private hospital, where a chest X-ray, neck, and soft tissue

¹Oral and Maxillofacial Surgery Department, Faculty of Dentistry, Universitas Padjadjaran, Bandung, Indonesia

²Oral and Maxillofacial Surgery Department, Hasan Sadikin Hospital, Bandung, Indonesia

Corresponding Author:

Tantry Maulina, Oral and Maxillofacial Surgery Department, Faculty of Dentistry, Universitas Padjadjaran, Jl. Sekeloa Selatan no. 1, Bandung 40132, Indonesia.

Email: tantry.maulina@fkg.unpad.ac.id



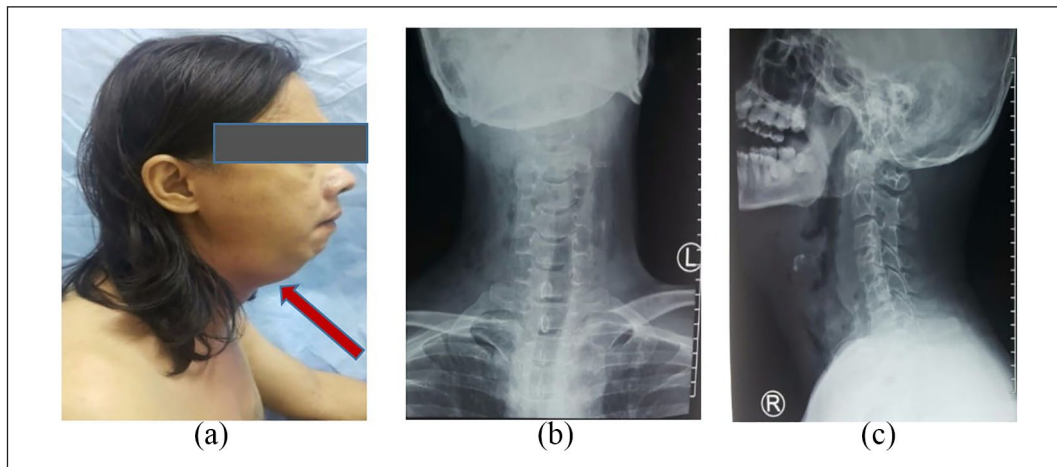


Figure 1. (a) Side view clinical appearance, and (b, c) neck and soft tissue X-ray demonstrated air bubble appearance at the anterior part of the neck and the trachea has deviated to the left, an indication of right lateral pharyngeal space abscess.

X-ray (Figure 1) and blood examinations were performed. The patient also received intravenous antibiotics (ceftriaxone, metronidazole, levofloxacin, omeprazole, and ketorolac; dosage unknown), yet, as there was no improvement to the size of the swelling, the patient was referred to our hospital.

Physical examination revealed that swelling on the right submandibular region extended to the sublingual region, submental region, and the left submandibular region (with a size of $10 \times 6 \times 2$ cm), reddish, febrile, fluctuated, and tender. The patient was febrile (38.8°C), had trismus, 102 beats per minute (bpm) pulse rate, respiratory rate is 26 breaths/minute, SpO₂ was 98.2%, and 100/60 mm Hg blood pressure. No history of asthma or allergy was reported. The HIV and tuberculosis results came back negative, and the patient had no history of a dental visit. Therefore, past medical history was considered as non-contributory. Intraoral findings revealed a gangrene pulp of the #47 tooth and pericoronitis around the #48 impacted tooth. No other cavities were detected, regardless of the poor oral hygiene. Supporting clinical and laboratory examination included sequential organ failure assessment (SOFA), complete blood count, blood gas analysis, chest AP Lateral X-ray, and neck and soft tissue X-ray. The Erythrocyte Sedimentation Rate (ESR) test was not performed. Once the laboratory results were obtained (Table 1), a diagnosis of Ludwig's angina and septic shock was confirmed. In regard to the septic shock management, the patient received an infusion of norepinephrine.

The patient was taken to the operating room immediately. A tracheostomy, emergency drainage, and tooth extraction (47, 48) were performed. Culture and sensitivity tests of blood and pus were performed but yielded a negative outcome. To allow further drainage, a Penrose drain was placed at the submandibular area, submental area, and (posterior) sublingual area (Figure 2). The patient was admitted for 10 days and received intravenous meropenem

(1 g, three times per day), cefotaxime (1 g, three times per day), and metronidazole (500 mg, three times per day) as his antibiotics regimen. Another blood test was performed on the 5th and 10th day after the surgery, while another thorax X-ray was performed on the 10th day. The tracheostomy tube was removed on the eighth day. The patient was discharged on the 10th day following clinical improvement (significant reduction of the swellings in all regions: submandibular, sublingual, and submental), pus production was less than 5 cc/day, mouth opening was more than 3 cm, the patient no longer experienced swallowing difficulty, and vital signs were normal. The blood test results (except for the white blood count that was slightly higher than normal value: $14.930/\text{mm}^3$) and thorax photo results were in favor of this decision.

Discussion

Odontogenic infection, the main cause of Ludwig's angina and septic shock, has been known as the most common cause of orofacial infection. In a study conducted by Rahman et al.,¹¹ in Malaysia, odontogenic infection was found as the most common cause of orofacial infection in 263 patients out of 416 patients being investigated. And in a study conducted at Hasan Sadikin Hospital, Indonesia, for a duration of 1 year (2015–2016), 16 cases of Ludwig's angina were revealed. Out of the 16 cases, 11 patients had sepsis or septic shock as a complication, and mortality occurred in two cases.¹² Furthermore, severe odontogenic infections such as Ludwig's angina have been reported to have considerable mortality rate,^{13,14} thereby making prompt and thorough responses crucial to their management.

The management of Ludwig's angina requires efficacy and efficiency due to the rapid progression of the infection. Another factor that increases the mortality rate is the difficulty in maintaining airway patency, which, in 8% to 10% of patients, resulted in asphyxiation and death.^{4,15} In the

Table 1. Laboratory findings before emergency tracheostomy and drainage procedure.

No.	Hematology	Result	Reference range	Unit
1.	PT	13.50	9.1–13.1	s
2.	INR	1.26	0.8–1.2	s
3.	APTT	34	14.2–34.2	s
4.	Hemoglobin	13.3	M (14–17.4)	g/dL
5.	Hematocrit	38.1	40–52	%
6.	Leukocytes	30.640	4.400–11.300	/mm ³
7.	Erythrocytes	4.06	3.5–5.8	million/ μ L
8.	Platelet	470,000	150,000–450,000	/mm
No.	Chemical blood components			
1.	AST (SGOT)	32	<37	U/L 37°C
2.	AST (SGPT)	45	<41	U/L 37°C
3.	Urea	77	15–50	mg/dL
4.	Creatinine	1.2	0.7–1.3	mg/dL
5.	Timely blood glucose	93	<140	mg/dL
6.	Sodium (Na)	123	135–145	mEq/L
7.	Potassium (K)	4.2	3.6–5.5	mEq/L
8.	Lactate	1.5	0.7–2.5	mmol/L
9.	Albumin	1.9	3.4–5.0	g/dL
No.	Blood gas analysis			
1.	pH	7.509	7.34–7.45	
2.	PCO ₂	23.1	35–45	mm Hg
3.	PO ₂	89.2	83–108	mm Hg
4.	HCO ₃	18.5	21–28	mEq/L
5.	TCO ₂	19.2	22–29	mmol/L
6.	Base excess	-2.0	(-2)–(+3)	mEq/L
7.	O ₂ saturation	98.2	95–98	%
8.	HBsAg chrome	Non-reactive		
9.	Anti-HIV	Non-reactive		

Bold-faced values indicate abnormal results.

PT: Prothrombin time; INR: International normalized ratio; APTT: Activated partial thromboplastin time; AST: Aspartate Aminotransferase; SGOT: serum glutamic oxaloacetic transaminase; SGPT: Serum glutamic pyruvic transaminase; HBsAg: Hepatitis B Surface Antigen.

case where a septic shock is present as a complication of Ludwig's angina, the management is even more complicated as it might lead to death as reported by Chequetto et al.,¹⁶ and therefore, the management should be thorough and as early as possible. In the current case, the antibiotics given served as therapeutic tools for the odontogenic infection that caused Ludwig's angina as well as the septic shock. The patient also received intravenous norepinephrine to manage the septic shock, as per standardized procedure.⁵ Vasoactive agents are required in septic shock management to prevent prolonged hypotension which might impair tissue perfusion, and one of the most recommended vasoactive agents is norepinephrine.¹⁷

In comparison to therapy, a case reported by Fellini et al., about the management of Ludwig's angina patient with similar symptoms to the patient reported in the current case report, a slightly different approach was performed. As the septic shock was not suspected, the patient did not receive vasopressor infusion. Unfortunately, the patient did develop a septic

shock on the sixth day and passed away due to the septic shock.⁴ In another case report about the management of Ludwig's angina reported by Candamourty et al.,¹³ regardless of the similar symptoms to the patient in our case report, the medication given consisted "only" of intravenous cefotaxime, gentamicin, metrogyl, and decadron. No vasopressor was given, and the patient showed good improvement, and the recovery was satisfactory.

Regardless of the similar symptoms showed by patients, different approaches were chosen by the managing clinicians. Interestingly, different outcomes were shown by the patient, indicating that a case-per-case approach with consideration to the patient's response to medication is always the most suitable approach.

Conclusion

Accurate clinical assessment and immediate-goal-oriented therapy are the key factors for the successful treatment of

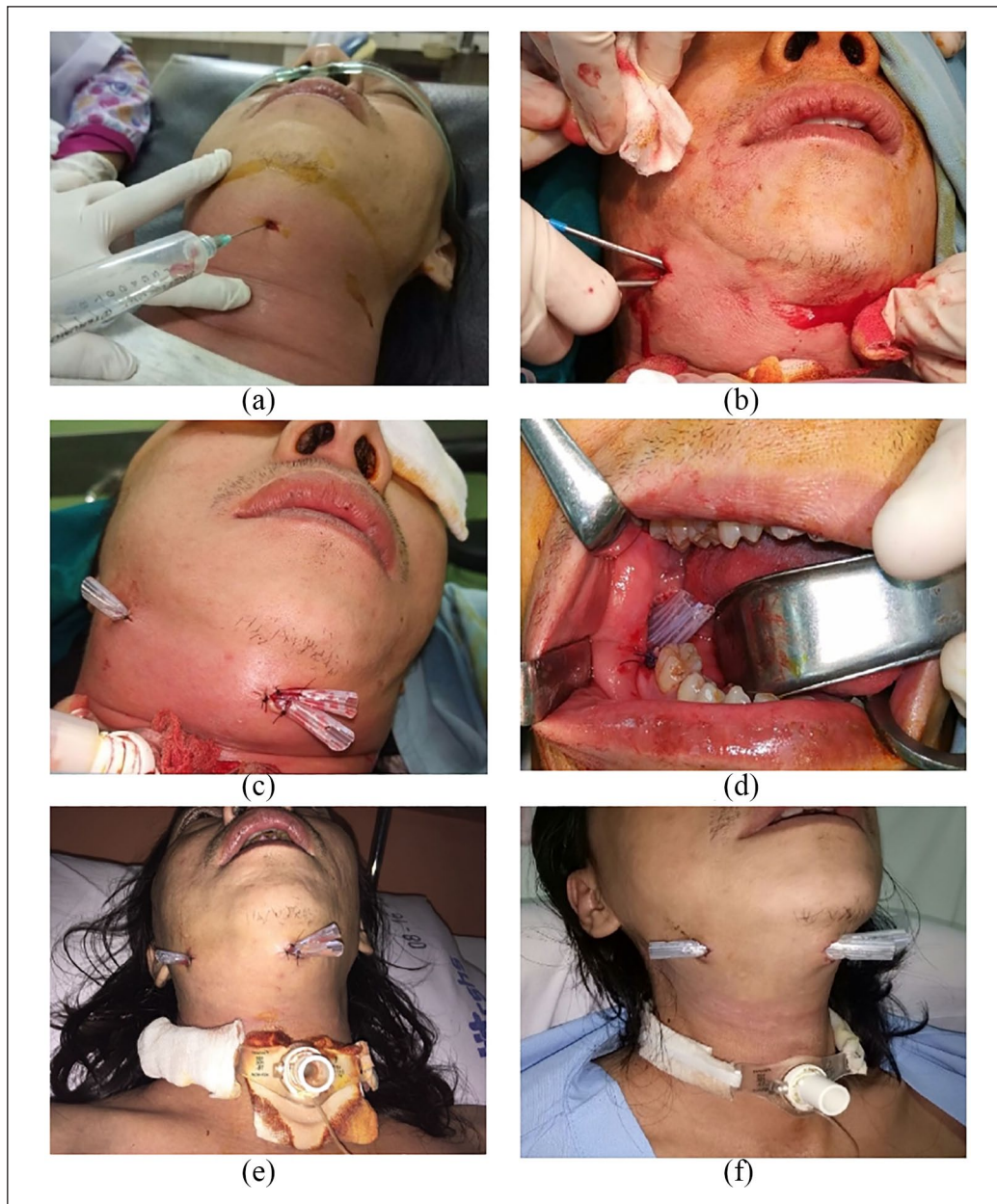

Figure 2. (a) Pus needle aspiration, (b) bilateral incision and drainage, (c) Penrose drain placement at submandibular and submental area, (d) Penrose drain placement at sublingual area, (e) postoperative condition—day 1, and (f) postoperative condition—day 5.

Ludwig's angina, especially when another fatal complication such as septic shock is present.

Acknowledgements

All authors would like to acknowledge all the doctors from the following departments: the Ear, Nose, and Throat (ENT) department; the Internal Disease department; and the Anesthesia and Reanimation department.

Declaration of conflicting interests

The author(s) declared no potential conflicts of interest with respect to the research, authorship, and/or publication of this article.

Ethical approval

Our institution does not require ethical approval for reporting individual cases or case series.


Funding

The author(s) received no financial support for the research, authorship, and/or publication of this article.

Informed consent

Written informed consent was obtained from the patient(s) for their anonymized information to be published in this article.

ORCID iD

Tantry Maulina  <https://orcid.org/0000-0002-6975-990X>

References

1. Hupp JR and Ferneini EM. *Head, neck, and orofacial infections: an interdisciplinary approach*. St Louis, MO: Elsevier, 2016.
2. Topazian RG, Goldberg MH and Hupp JR. *Oral and maxillofacial infections*. 4th ed. Philadelphia, PA: WB Saunders Company, 2002.
3. Ghali GE, Larsen PE and Waite DP. *Peterson's principles of oral and maxillofacial surgery*. 2nd ed. Hamilton, ON, Canada; London: BC Decker, 2004.
4. Fellini RT, Volquind D, Schnor OH, et al. Airway management in Ludwig's angina—a challenge: case report. *Rev Bras Anesthesiol* 2017; 67: 637–640.
5. Keeley A, Hine P and Nsutebu E. The recognition and management of sepsis and septic shock: a guide for non-intensivists. *Postgrad Med J* 2017; 93: 626–634.
6. Alotaibi N, Cloutier L, Khaldoun E, et al. Criteria for admission of odontogenic infections at high risk of deep neck space infection. *Eur Ann Otorhinolaryngol Head Neck Dis* 2015; 132: 261–264.
7. Sjamsudin E, Masri L and Arumsari A. Correlation between spatial involvement and systemic disease with the length of hospital stay in odontogenic maxillofacial infection patients. *Int J Sci Res* 2018; 7: 1698–1700.
8. Ismi O, Yesilova M, Özcan C, et al. Difficult cases of odontogenic neck infections: a report of three patients. *Balkan Med J* 2017; 34: 172–179.
9. Balasubramanian S, Elavenil P, Shanmugasundaram S, et al. Ludwig's angina: a case report and review of management. *SRM J Res Dent Sci* 2014; 5: 211–214.
10. Alimin NA and Syamsudin E. Emergency management of Ludwig's angina: a case report. *J Dentomaxillofac Sci* 2017; 2: 201–204.
11. Rahman ZAA, Hamimah H and Bunyarit SS. Clinical patterns of orofacial infections. *Annal Dent Univ Malaya* 2005; 12: 18–23.
12. Muharty A, Nurwiadh A, Sjamsudin E, et al. Ludwig's angina: an analysis of sixteen cases at Hasan Sadikin Hospital, Bandung, Indonesia. *Int J Oral Maxillofac Surg* 2017; 46: 147.
13. Candamourty R, Venkatachalam S, Babu MRR, et al. Ludwig's angina—an emergency: a case report with literature review. *J Nat Sci Biol Med* 2012; 3: 206–208.
14. Costain N and Marrie TJ. Ludwig's angina. *Am J Med* 2011; 124: 115–117.
15. Fritsch DE and Klein DG. Curriculum in critical care: Ludwig's angina. *Heart Lung: J Crit Care* 1992; 1: 39–47.
16. Chechetto T, Serafini F, Ruivo G, et al. Septic shock secondary to mediastinitis due to Ludwig angina after dental abscess: a case report. *Int Arch Otorhinolaryngol* 2014; 18: a2335.
17. De Backer D, Aldecoa C, Nijmi H, et al. Dopamine versus norepinephrine in the treatment of septic shock: a meta-analysis. *Crit Care Med* 2012; 40: 725–730.