

Received: 12th March 2014 Accepted: 9th June 2014 Conflict of Interest: None

Case Report

Source of Support: Nil

A Labially Positioned Mesiodens and Its Repositioning as a Missing Central Incisor

Rena Ephraim¹, N C Dilna², S Sreedevi³, M Shubha⁴

Contributors:

¹Professor and Head, Department of Pedodontics and Preventive Dentistry, Mahe Institute of Dental Sciences, Mahe, UT of Puducherry, India; ²Reader, Department of Pedodontics and Preventive Dentistry, Pariyaram Dental College, Kannur, Kerala, India; ³Professor, Department of Pedodontics and Preventive Dentistry, Mahe Institute of Dental Sciences, Mahe, UT of Puducherry, India; ⁴Reader, Department of Pedodontics and Preventive Dentistry, Mahe Institute of Dental Sciences, Mahe, UT of Puducherry, India.

Correspondence:

Dr. Ephraim R. Department of Pedodontics and Preventive Dentistry, Mahe Institute of Dental Sciences, Mahe - 673 310, UT of Puducherry, India. Email: dr.rena.ephraim@gmail.com

How to cite the article:

Ephraim R, Dilna NC, Sreedevi S, Shubha M. A labially positioned mesiodens and its repositioning as a missing central incisor. J Int Oral Health 2014;6(5):114-7.

Abstract:

Hyperdontia is an increased number of teeth within the dental arches. This is of particular interest to pediatric dentists who commonly make the initial diagnosis. Most often a large portion of these teeth is completely embedded or impacted within the jaws and can be viewed only radiographically. Hyperdontia can occur on virtually every tooth-bearing surface. However, the most frequent is the mesiodens, in the anterior maxillary region. Anterior maxillary teeth are one of the most important features contributing to aesthetics of an individual. Missing anterior teeth can cause undue psychological stress in children, during their growing years. Most of the literature available show that the mesiodens are situated on the palatal aspect of the permanent incisors. Their treatment frequently involves an early recognition, extraction through a traditional palatal technique and guiding the associated permanent tooth to its original position. The purpose of this article is to enlighten the clinician of the need of deviating from the traditional approach of early extraction in particular situations and to conserve the mesiodens if favorable as an alternative treatment to a malformed permanent tooth, which may fail to erupt. This report describes a successful multidisciplinary approach to treatment of a unerupted, labially placed mesiodens in conjunction with a dilacerated and impacted permanent tooth, in a child with a missing left central incisor. Treatment consisted of localizing and confirming the placement of the mesiodens to be labial, surgically exposing the crown of the mesiodens through a labial surgical approach, orthodontically guiding it to the position of the missing central incisor, extracting the malformed permanent incisor, and restoring the mesiodens to the required anatomy with composites, to establish aesthetics and function of the affected region.

Key Words: Dilacerated, impacted, mesiodens, successor, traction, unerupted

Introduction

Hyperdontia or supernumerary teeth are of special interest to the pediatric dentist because they commonly encounter this particular situation initially. In the vast majority of cases, this extra tooth is impacted and obscured from view, only to be visible radiographically.^{1,2} Hyperdontia can occur on virtually every tooth-bearing surface. However, the occurrence in anterior maxillary regions is the most predominant and the most traumatic to the child patient. An extra or supernumerary tooth located in the premaxillary midline region between the maxillary central incisors is termed mesiodens.³⁻⁵ The etiology of mesiodens being unclear, the most popular theory includes intrusion injuries to deciduous teeth, genetic predilection and hyperactivity of the dental lamina.^{1,6-8} The tooth morphology of mesiodens is often characterized by a conical crown and short root. A few cases of a tuberculum like shape has been reported with an occasional invagination.¹ Occasionally a mesiodens resembles a permanent tooth in anatomy and is called a supplementary tooth. About 90% of the mesiodens reported are situated palatal to the associated permanent tooth.⁴ Very rarely a mesiodens is encountered on the labial aspect of the permanent tooth. A mesiodens that are intimately positioned to the permanent tooth bud may alter the bud, impede eruption, alter root development or resorb root of the existing regular incisors.⁵ Few reports of acute intrusive trauma to the primary teeth showing the presence of mesiodens in the region of the trauma, in conjunction with developmentally defective permanent successors has led to the belief that trauma can also result in the formation of a supernumerary.⁸ In all the cases of detection of a mesiodens the treatment has been extraction, earlier or later, of the mesiodens in question to avoid further mal-alignment of the permanent teeth associated with it.

Dilaceration is a condition in which the roots of the teeth are abruptly curved from the cervix of the tooth and directed labially or palatal. It is believed to be the result of disturbances in growth of Hertwig's epithelial root sheath by such factors as clefting, trauma, displacement of nutrient vessels, ankylosis and supernumerary teeth.⁹⁻¹² Dilacerations occur frequently due to the nonaxial displacement of the already formed hard tissue portion of the developing crown. Depending on the degree of dilaceration, these teeth may partially erupt or fail to erupt into the oral cavity and have to be surgically removed.⁸ Depending upon the age of the child at the time of injury, the direction and severity of the intrusion, and the presence of alveolar bone fracture the degree of dilaceration

of the permanent tooth root in the region may vary from cessation of root formation to mild to severe deviation from the long axis.⁹

As teeth erupt, a general guideline is that contralateral teeth usually erupt within 6 months of one another. When a patient has such a delay in the eruption, of more than 6 months, intra-oral periapical radiograph or panoramic radiograph should be made to assess the condition. The radiograph may show no permanent successor, a tooth that is close to eruption, a tooth that is ectopically erupting or the presence of a supernumerary which impede eruption of the permanent successor.^{10,11} The management requires a multidisciplinary approach between a number of specialists. In a mixed dentition, the premature loss of a primary anterior tooth with a missing or impacted permanent successor can quickly lead to mesial tipping or migration of the adjacent erupting permanent teeth.^{13,14} This paper is unique in that a very rarely seen labially placed mesiodens could be detected and positioned favorably to replace a missing central incisor.

Case Report

The case we present here is about a 10-year-old girl reported to the Department of Pedodontics in a Dental College in Kerala, India with the complaint of a missing upper left central incisor. She was a normal healthy child with a noncontributory medical history. However, she gave a dental history of trauma at the age of 4 years and loss of her left deciduous central incisor. She presented with a middle mixed dentition with normal overjet and overbite and an end-to-end molar relationship. Anterior incisor space was reduced due to the mesial drift of the erupted permanent left lateral incisor. The right central and lateral incisors had erupted at the appropriate time. Clinical examination, including labial and palatal palpation was performed. Intraoral radiographs were advised which revealed the presence of a mesiodens and a central incisor crown. For higher accuracy of localizing the position of the mesiodens and the root of the permanent tooth, vertical and horizontal shift radiographic views and a maxillary anterior occlusal radiograph were advised. These radiographic series indicated the presence of a well formed, labially placed mesiodens, with its long axis vertical in the alveolus, high in the anterior space. The root of the mesiodens was in close approximation to the permanent tooth crown. Placed high in the alveolar bone was a malformed central incisor, with a rudimentary root, placed at an angle to the crown. The unerupted mesiodens showed a sufficiently long and straight root with a fairly flat crown favorably positioned for guiding into position (Figure 1).

Considering the age of the patient, clinical and radiographic findings, and the following treatment was decided upon. Guiding the mesiodens to the edentulous area could provide a unique advantage of bridging the anterior space and

prevention of the use of a prosthesis at such a young age. The procedure was explained to the parents and the patient, and their approval sought. After routine blood examination, using a labial approach, surgical exposure of the labial aspect of the supernumerary tooth was attempted. A closed exposure of the mesiodens was preferred to enable an orthodontic eruption along with its periodontal attachment. The mesiodens revealed a flat labial surface of mesiodistal width of approximately 6 mm, with 3-4 mammelon like structures at its incisal edge. Simultaneous bonding of an orthodontic bracket to the exposed labial aspect was found appropriate (Figure 2). A surgical approach, at this juncture, for the removal of the permanent tooth, could jeopardize the root of the mesiodens and impede proper alignment and cause bone loss in that region. Using light traction with elastics, the mesiodens was gradually guided to the position of the missing central incisor (Figures 3 and 4). After the root of the mesiodens had descended, the child was subjected to surgical extraction of the malformed permanent tooth, under local anesthesia. As

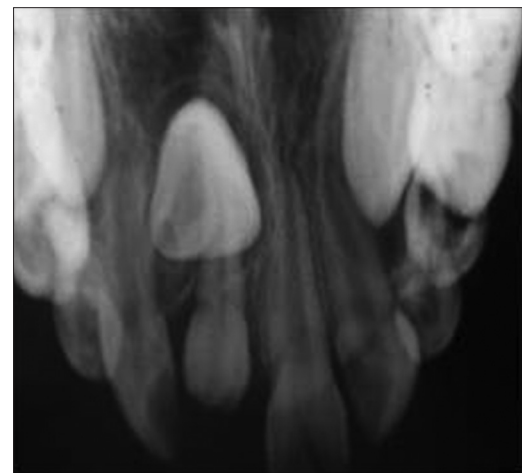


Figure 1: The unerupted mesiodens showing a sufficiently long and straight root with a fairly flat crown favorably positioned for guiding into position.

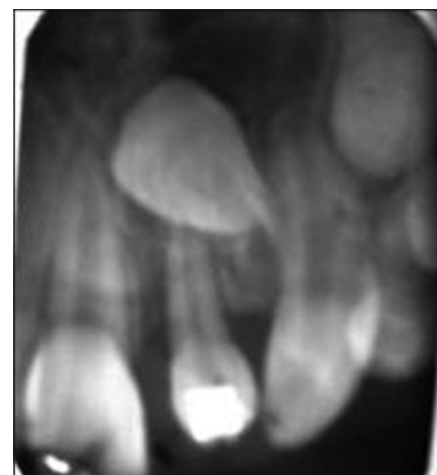


Figure 2: Simultaneous bonding of an orthodontic bracket to the exposed labial aspect.

rightfully assessed in the radiographic series, the root of the permanent incisor was rudimentary and dilacerated and narrow with a possibility of cessation. Aesthetic restoration of the mesiodens was carried out with anterior composites (Figure 5).

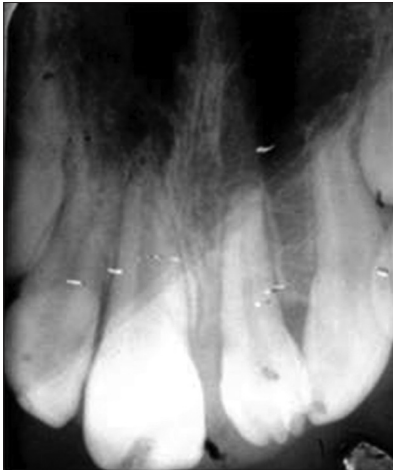

Figure 3: Using light traction with elastics, the mesiodens was gradually guided to the position of the missing central incisor.

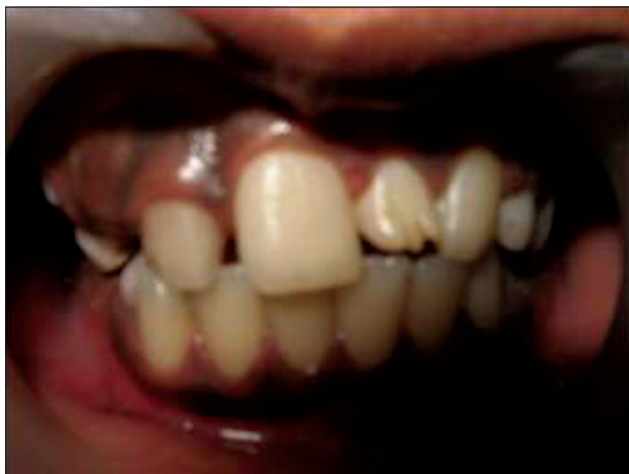

Figure 4: Using light traction with elastics, the mesiodens was gradually guided to the position of the missing central incisor.

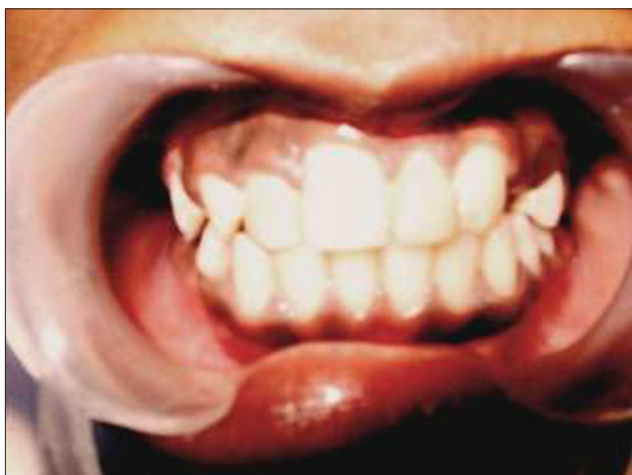

Figure 5: Aesthetic restoration of the mesiodens was carried out with anterior composites.

The patient was extremely satisfied with her appearance after the treatment. After eruption of the permanent left canine, adjunctive procedures may be appropriate to distalize the left lateral incisor with fixed orthodontic therapy to accommodate a crown as large as the adjacent central incisor, for better aesthetics.

Discussion

Mesiodens are the most common supernumerary teeth seen associated with trauma. A survey has found 23% cases of mesiodens causing delay in eruption of the permanent teeth.¹³ In 28-63% of cases mesiodens is noted to cause ectopic eruption, displacement or rotation of a permanent central incisor.¹⁵⁻¹⁸ Trauma to the primary maxillary central incisor is highly associated with developmental disturbances of the permanent tooth germ, owing to its palatal and superior position to the apex of the root of the primary tooth.^{11,12} Dilaceration is a rare condition seen in permanent maxillary incisors because they are more prone to trauma and due to their close proximity, and represents only 3% of the total injuries to the developing teeth. Teeth with dilacerated crown may either erupt with buccal or lingual displacement or remain impacted.¹¹ In a situation such as this, a mesiodens in a favorable position could be considered to replace a permanent missing tooth. Most literature available describes the need for early recognition of the mesiodens and its extraction, to avoid displacement, developmental anomalies or delay in eruption of the associated permanent tooth.^{15,16} Early extraction of a supernumerary or mesiodens in the mixed dentition is recommended, to allow for optimal yet minimal treatment for the permanent successor. However, in the event of a malformed, impacted permanent successor, similar to our situation, all efforts should be taken to analyze and identify the path of eruption and location of the impacted mesiodens relative to the adjacent structures, and development of an appropriate treatment plan evolved to preserve and guide it to the desired position. Once a mesiodens have been diagnosed, the clinician must decide on early treatment to minimize further sequelae.^{5,19}

Conclusion

Early loss of anterior teeth may lead to psychological disturbances and affect a child's self-esteem and socialization during the important phase of development and children suffer without being vocal about it. Since the incidence of mesiodens is fairly high in traumatic injuries where an associated malformed permanent tooth often fails to erupt, a thought of a mesiodens to bridge the gap in the anterior edentulous region can be seriously considered. Newer ideas and techniques can help the patient to improve aesthetics, prevent the early use of prosthesis, and restore the child's self-confidence. The present treatment plan of restoring the tooth with a composite restoration can be considered in an adult patient when time is a factor and emergency aesthetic management is necessary.

References

1. Primosch RE. Anterior supernumerary teeth – Assessment and surgical intervention in children. *Pediatr Dent* 1981;3(2):204-15.
2. Tay F, Pang A, Yuen S. Unerupted maxillary anterior supernumerary teeth: Report of 204 cases. *ASDC J Dent Child* 1984;51(4):289-94.
3. Bergström K. An orthopantomographic study of hypodontia, supernumeraries and other anomalies in school children between the ages of 8-9 years. An epidemiological study. *Swed Dent J* 1977;1:145-57.
4. Hattab FN, Yassin OM, Rawashdeh MA. Supernumerary teeth: Report of three cases and review of the literature. *ASDC J Dent Child* 1994;61(5-6):382-93.
5. Henry RJ, Post AC. A labially positioned mesiodens: Case report. *Pediatr Dent* 1989;11(1):59-63.
6. Sedano HO, Gorlin RJ. Familial occurrence of mesiodens. *Oral Surg Oral Med Oral Pathol* 1969;27(3):360-1.
7. Seddon RP, Johnstone SC, Smith PB. Mesiodentes in twins: A case report and a review of the literature. *Int J Paediatr Dent* 1997;7(3):177-84.
8. Diab M, elBadrawy HE. Intrusion injuries of primary incisors. Part III: Effects on the permanent successors. *Quintessence Int* 2000;31(6):377-84.
9. Sant'Anna EF, Marquezan M, Sant'Anna CF. Impacted incisors associated with supernumerary teeth treated with a modified Haas appliance. *Am J Orthod Dentofacial Orthop* 2012;142(6):863-71.
10. Mellara T de S, Nelson-Filho P, Queiroz AM, Santamaria Júnior M, Silva RA, Silva LA. Crown dilaceration in permanent teeth after trauma to the primary predecessors: Report of three cases. *Braz Dent J* 2012;23(5):591-6.
11. Maragakis MG. Crown dilaceration of permanent incisors following trauma to their primary predecessors. *J Clin Pediatr Dent* 1995;20:49-52.
12. Topouzelis N, Tsaousoglou P, Pisoka V, Zouloumis L. Dilaceration of maxillary central incisor: A literature review. *Dent Traumatol* 2010;26(5):427-33.
13. Khandelwal V, Nayak AU, Naveen RB, Ninawe N, Nayak PA, Sai Prasad SV. Prevalence of mesiodens among six- to seventeen-year-old school going children of Indore. *J Indian Soc Pedod Prev Dent* 2011;29(4):288-93.
14. Howard RD. The unerupted incisor. A study of the postoperative eruptive history of incisors delayed in their eruption by supernumerary teeth. *Dent Pract Dent Rec* 1967;17(9):332-41.
15. Rotberg SJ, Kopel HM. Early versus late removal of mesiodens: A clinical study of 375 children. *Compend Contin Educ Dent* 1984;2:115-20.
16. Nazif MM, Ruffalo RC, Zullo T. Impacted supernumerary teeth: A survey of 50 cases. *J Am Dent Assoc* 1983;106(2):201-4.
17. von Arx T. Developmental disturbances of permanent teeth following trauma to the primary dentition. *Aust Dent J* 1993;38(1):1-10.
18. Gardiner JH. Supernumerary teeth. *Dent Pract* 1961;12:63-73.
19. Russell KA, Folwarczna MA. Mesiodens – Diagnosis and management of a common supernumerary tooth. *J Can Dent Assoc* 2003;69(6):362-6.