

Multiple pterygoid approach: A novel technique with single-piece implants

ABSTRACT

The intended target site to engage a fixture distal into the tuberosity is the pterygoid apophysis that comprises the maxillary tuberosity, pyramidal process of the palatine bone, and the pterygoid process of the sphenoid bone. Pterygoid implants are incorrectly labeled in literature owing to the fact that they are actually root form conventional implants and should hence be termed as 'tubero-ptyergoid implant'. An implant engaging the pterygoid apophysis/pillar taking distal maxillary support and avoiding successfully the cantilever situation is called a pterygoid implant. It essentially does not acquire primary with support of distal maxilla initially from the tuberosity. Instead, it makes its way into the apophysis and sometimes via a transsinus approach. A tubero-ptyergoid implant, because of the root form screw shape fixture that is wide at the crestal aspect and converging toward the apex, takes the primary support from the tuberosity and engages the pterygoid pillar apically, thus allowing more bone to implant contact but has its limitation in deficient/atrophied tuberosity.

Keywords: Pterygoid implant, single-piece implant, tubero-ptyergoid implant

INTRODUCTION

Primum non nocere or "First, do no harm" should be kept in mind before planning rehabilitation for the needed patient. Patients always appreciate the non or minimal invasive, minimal time demanding comprising less appointments, least expensive, and long-term answerable treatment option, preferably without cantilever with maximum chewing surfaces presented for them. Immediate functional loading prosthetic rehabilitation of the lost stomatognathic structure of the jaws with flapless procedure is the concept surgeons always aim, if possible, to achieve for the best comfort of their patients. Dental implant-supported prosthesis^[1-9] has been a proven treatment modality for quite a long time to achieve functional rehabilitation of the jaws. Many authors^[10-22] have shown the possibility of loading implants immediately like. Of all the factors involved, primary stability seems to be the most important determining factor on immediate implant loading. Clinically, host bone density plays an important role, an implant placed in compact dense bone is more likely to ensure initial stability and to sustain immediate forces.

The skull presents a series of dense bony buttresses that form a protective frame around the different craniofacial cavities. Anterior buttresses (frontomaxillary and frontozygomatic) and posterior buttress (ptyergomaxillary) are the dense columns of bone in maxilla, which supports the fixture with high stability. When cross arch fixated, they can provide a long-term solution for maxillary prosthesis by avoiding a cantilever.^[23-26] Utilizing the pterygoid or ptyergomaxillary region for the stable retention of the fixture was introduced

VIVEK GAUR, ANITA GALA DOSHI¹, LUKASZ R. PALKA²

Department of Oral-Maxillofacial Surgery, Jaipur Dental College, Maharaj Vinayak Global University, Jaipur,

¹Department of Prosthodontics, Sankalchand Patel University, Visnagar, Gujrat, India, ²Private Practice, Zary, Poland


Address for correspondence: Dr. Vivek Gaur, 417, K M Trade Tower, Adjacent Radisson Blu Hotel, Kaushambi, Ghaziabad, Uttar Pradesh, India. E-mail: drvivekgaur@yahoo.co.in

Received: 02 July 2020, **Accepted in Revised Form:** 27 September 2020, **Published:** 20 August 2022

This is an open access journal, and articles are distributed under the terms of the Creative Commons Attribution-NonCommercial-ShareAlike 4.0 License, which allows others to remix, tweak, and build upon the work non-commercially, as long as appropriate credit is given and the new creations are licensed under the identical terms.

For reprints contact: WKHLRPMedknow_reprints@wolterskluwer.com

How to cite this article: Gaur V, Doshi AG, Palka LR. Multiple ptyergoid approach: A novel technique with single-piece implants. Natl J Maxillofac Surg 2022;13:S228-36.

Access this article online	
Website: www.njms.in	Quick Response Code 
DOI: 10.4103/njms.NJMS_137_20	

by Tulasne.^[27] Tulasne^[27] credited Paul Tessier for proposing an idea of placing implants in the pterygoid region, which was then a rescue implant case. The intended target site to engage fixture distal to tuberosity is the pterygoid apophysis comprising the maxillary tuberosity, pyramidal process of the palatine bone, and the pterygoid process of the sphenoid bone [Figure 1a and b].

The senior author with his experience for the past decade of engaging single-piece implants in the pterygoid apophysis with flapless approach defined pterygoid implant as an implant engaging the pterygoid apophysis/pillar with support of the distal maxilla and successfully avoiding the cantilever situation is called a pterygoid implant. It essentially does not take primary support initially from the tuberosity but makes its way for apophysis and sometimes trans-sinus approach. A tubero-ptyergoid implant, which because of root form screw shape fixture wide at crestal and converging to apex, takes the primary support from the tuberosity and engages the pterygoid pillar apically and achieving more bone to implant contact but has its limitation in deficient/atrophied tuberosity.

APPLIED ANATOMY

Pterygoid pillar is the junction of maxillary tuberosity, the pterygoid apophysis of the sphenoid bone, and pyramidal apophysis of the palatine bone.^[28] The upper limit of the junction is the pterygomaxillary fissure. The height of the maxillary tuberosity ranges from 1.23 mm to 13.95 mm with the mean value of 7.45 mm; width of the maxillary tuberosity distal to upper 3rd molar ranges from 11.02 mm to 22.61 mm with the mean value of 16.52 mm; width of pterygoid process ranges from 7.30 mm to 15.68 mm with the mean value of 11.60 mm; and length of posterior maxilla which extends from the lateral margin of pterygomaxillary junction till the root of zygoma ranges from 21.94 mm to 32.77 mm with a mean value of 27.18 mm. Root of zygoma falls at the level of pterygomaxillary fissure sagittally [Figure 2]. Width of pterygoid process or pterygoid pillar is a column of dense

bone between the medial and lateral wing of sphenoid bone where the pterygoid implant apically need to be engaged. The dimensions mentioned above are of great importance regarding the length and number of implants that can be engaged in the pterygoid pillar or apophysis, thus ensuring that there is always room comfortably for the single or multiple pterygoid implants.

Flapless pterygoid approach for implant engagement demands thorough knowledge of the structures around and the bony landmarks which acts as reference points guiding the approach. The relationship of neurovascular bundle with pterygomaxillary fissure, the muscles specially lateral and medial pterygoid, the hamular process, hamular notch and the greater palatine foramen need to be considered. The pterygomaxillary fissure is the communication between infratemporal fossa and pterygopalatine fossa, former being laterally placed, and later medially to the fissure. Contents of the pterygomaxillary fossa are divided into two distinct layers: an anterior one, which contains all the vessels, and the posterior one, which contains all the nerves. Thus, the vascular contents are of importance regarding the pterygomaxillary fissure, lateral to the fissure at infratemporal fossa, pterygoid venous plexus is situated, and the major vessel in question is internal maxillary artery which passes through the pterygomaxillary fissure toward sphenopalatine foramen.^[24]

The internal maxillary artery emerges from the external carotid artery at the subcondylar level and passes into the anteromedial region deep into the condylar neck of the mandible into the infratemporal fossa. It is divided into three parts as of its course and relationship to the anatomical structures: the mandibular as 1st part, the pterygoid as 2nd part, and sphenopalatine as the 3rd part [Figure 3]. The information and knowledge regarding the course of the pterygoid part of maxillary artery and its relationship with lateral pterygoid muscle is of great significance to avoid accident for the pterygoid implant placement.^[29]

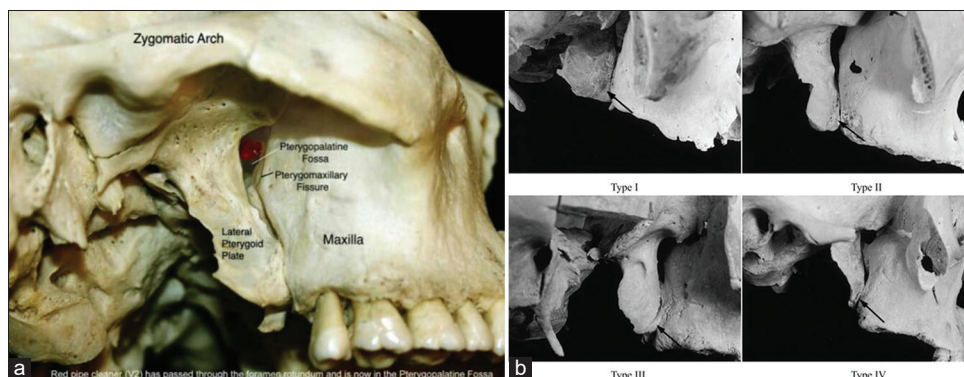


Figure 1: (a) Pterygoid pillar. (b) Classification of pterygoid apophysis (Lee et al. J Oral Rehabil 2001;28:125-32)

Pterygoid muscles, especially the lateral pterygoid muscle, have its importance regarding the course of internal maxillary artery, which is the most potent bleeder of the region in question. Medial pterygoid muscle consists of two heads, superficial and deep. The deep part forms the bulk of the muscle and originate from the medial surface of the lateral pterygoid plate of the sphenoid bone and insert at medial surface of the angle and ramus of the mandible. Lateral pterygoid muscle is the key muscle of the infratemporal region as the vessels and nerves are explained in relation to the lateral pterygoid muscle. Lateral pterygoid muscle comprises two heads, upper and lower. The upper head arises from the infratemporal surface and infratemporal crest of the greater wing of sphenoid. The lower head arises from the lateral surface of the lateral pterygoid plate. The fibers of lateral pterygoid muscle proceed backward and laterally to get inserted onto the disc–capsule complex of temporomandibular joint. 90% of the second part of the internal maxillary artery coursed lateral to the lateral pterygoid muscle, 7.5% deep/medial to the lateral pterygoid muscle, and 2.5% along the lower border of the lateral pterygoid muscle to enter the pterygomaxillary fissure.^[30] The internal maxillary artery courses superior and lateral to the pterygomaxillary fissure and terminate in the sphenopalatine fossa; it crosses at least 1 cm superior to the pterygomaxillary fissure.^[25,31,32]

The hamular process is the most prominent part of the medial pterygoid plate, which is easily palpable in the oropharynx. The hamular notch is a groove between the maxillary tuberosity and the hamular process; it is the posterior limit of the maxilla and is directed medially toward the pterygoid pillar, bony column between the medial and lateral pterygoid plates. The greater palatine foramen is located posterior-medial of the tuberosity which transmit descending palatine vessels and greater palatine nerve. There is always an undercut at the alveo-palatine junction at the medial aspect of the upper 3rd molar because of the greater palatine foramen [Figure 4].

SURGICAL TECHNIQUE REGARDING SINGLE, DOUBLE, AND TRIPLE PTERYGOID IMPLANTS

The surgical technique has been designed from the author's experience and after a decade of successful results with the technique. The technique with the flapless approach is based on osteotome, but when in doubt, the flap is raised for better visualization. Local anesthesia is administered during the chair side technique and the posterior superior alveolar nerve block and the palatal block is recommended. Preoperative preparations regarding the flapless approach are made by

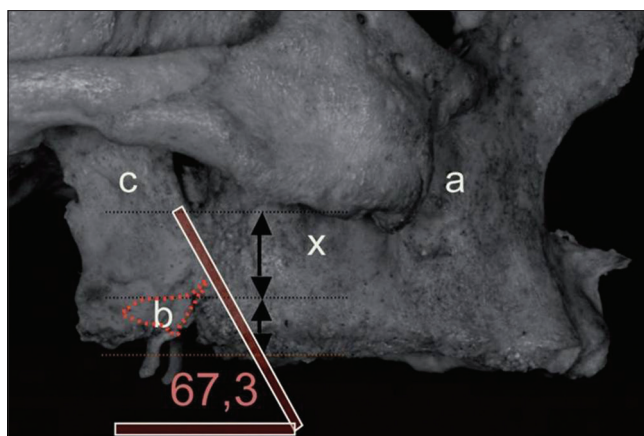


Figure 2: Pterygomaxillary fissure in relation to root of zygoma (X. Rodriguez-Ciurana y cols)

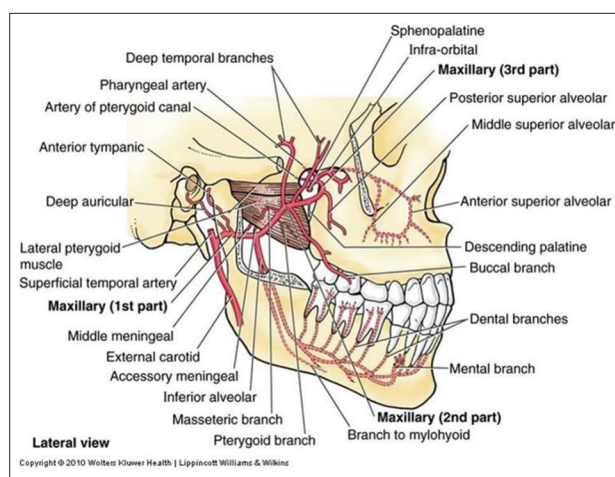


Figure 3: Internal maxillary artery course

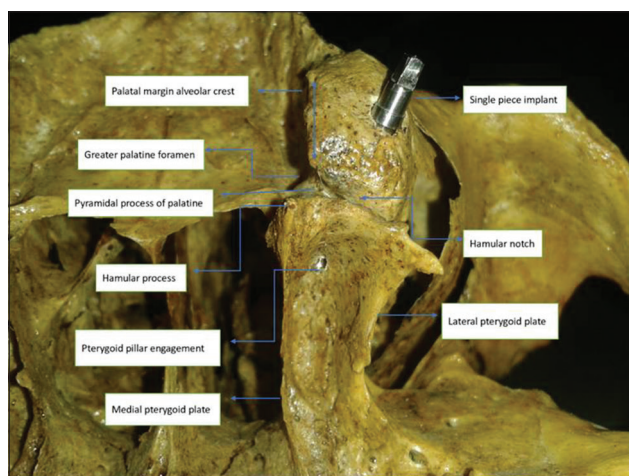


Figure 4: Landmarks in relation to pterygoid implant

observation of the hamular notch on the diagnostic cast and radiological evaluation of the pterygomaxillary fissure and its distance from the tuberosity. Long pathfinder drill attached to hand held instrument like BCD adapter® (Simpladent®, Switzerland) is advised for the initial osteotomy by tapping

it gently by an elevator such as Bein® elevator till the mineralized bone is felt by bell sound as pathfinder comes in contact with mineralized bone. The initial point of purchase should be at least 5 mm away from the palatal margin toward the mid of alveolar crest and the direction is always toward the hamular notch. Second osteotomy in sequence is done with straight handpiece 1:1 reduction preferably by 2 mm twist drill having defined markings of the length. Osteotomy with external irrigation is done with in and out motion facilitating the exodus of the necrotic bone and heat, bone is perforated at the other end of the drill observing the marking on the drill, and the same length implant is placed and engaged at the pterygoid apophysis obliquely toward the hamular notch. The first osteotomy is preferred for the distal most implant; the second implant osteotomy is been kept 5 mm away mesial to first one but apically angulating obliquely toward the first pterygoid implant already been placed. By engagement of the screw shaped single-piece implant obliquely at pterygoid apophysis, the amount of engaged bone is always more of the available pterygoid thickness anteroposteriorly. Single-piece screw design implants are placed preferably by the hand held adapter as recommended by the manufacturer to have tactile input and control of direction by the operator confirming the mineralized bone engagement with implant self-threading the under osteotomy path.

Available size and shape of maxillary tuberosity define the site of initial osteotomy and the direction with respect to Frankfurt plane;^[25] direction of osteotomy is always toward the hamular notch. When a single pterygoid implant is planned or in case of an overhanging tuberosity, the implant is engaged superiorly mid of the pterygoid apophysis or near the pterygomaxillary fissure.^[33,34] Implant osteotomy is done preferably around the second molar region lest it get short of pterygoid pillar as of excess tuberosity. With resorbed tuberosity and profound distal maxillary atrophy, the direction of implant is less in relation to Frankfurt plane and the implant engagement is more coronal but shorter in length, giving space for additional longer implant placement cranial to the distalmost apically at pterygoid apophysis. Implant osteotomy site is brought near to hamular notch as the tuberosity is atrophied but never posterior of hamular notch. Implant position gets changed in buccopalatal direction regarding the bulk of tuberosity available; straighter the resorbed distal maxilla, more straight is the direction of the implant head in line of the hamular notch. Anthropometrically, the angulation and the placement site of implant on alveolar crest changes with respect to relation of the tuberosity and the pterygoid apophysis, more the atrophy, shorter the implant in length, less the angulation with Frankfurt plane and straighter in line with hamular notch

and alveolar crest. Additional implants placed at pterygoid apophysis are mesial to distal most, apically converging to distal most, lengthier to its distal implant, and more cranially placed but short of pterygomaxillary fissure. Most of the time, additional implants in the atrophied tuberosity following a transsinus approach demand a surgical expertise. The implants like BECES® (Simpladent®, Switzerland) have bendable core body to bring the abutment at prosthetic desired location [Figure 5]. The technique of single, double, and triple implants placement at pterygoid pillar with site of emergence crestal of tuberosity and angulation is explained with pictures [Figures 6-8]. When more than one implants are placed in the pterygoid apophysis, the mesial should be placed obliquely toward the distal. It should converge apically otherwise it will slip into the maxillary sinus [Figure 9]. As the author mentions above, if an operator is in doubt or uncertain regarding structures, it is advisable to raise flap for visualization as in cases of upper 3rd molar impacted/submerged where it is needed to be removed by open approach; the technique is explained in Figure 10. After full-thickness flap is reflected and the removal of impacted/submerged molar, periosteal elevator is guided distal to hamular notch to be rested at pyramidal process of palatine providing the direction for the osteotomy, which is just mesial to the periosteal elevator but lateral to hamular notch.

DISCUSSION

The posterior maxilla frequently is a challenging site in terms of implant placement. The deficient available bone qualitatively and quantitatively makes the longterm prognosis of the fixture questionable. Schnitman^[35] demonstrated that the posterior maxilla was the least successful area for osseointegration with merely a 72% success rate. Classification of edentulous jaws proposed by Cawood and Howell^[36] concluded that, in general, changes of shape of the alveolar bone follow a predictable pattern. Alveolar bone changes the shape of anterior and posterior maxilla significantly in both horizontal and vertical axis. The pattern of resorption of alveolar bone in maxilla is from

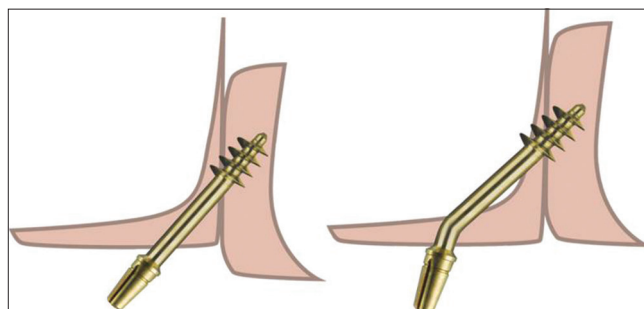


Figure 5: Schematic picture of bended pterygoid implant

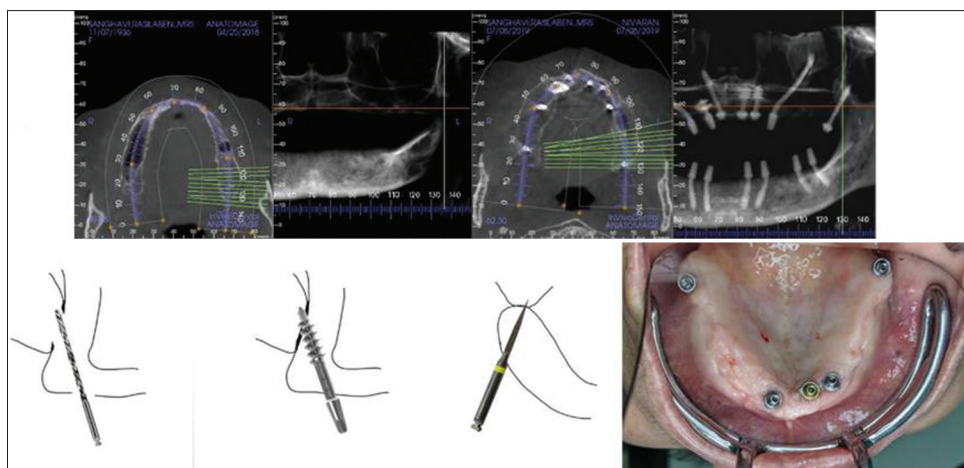


Figure 6: Single pterygoid approach

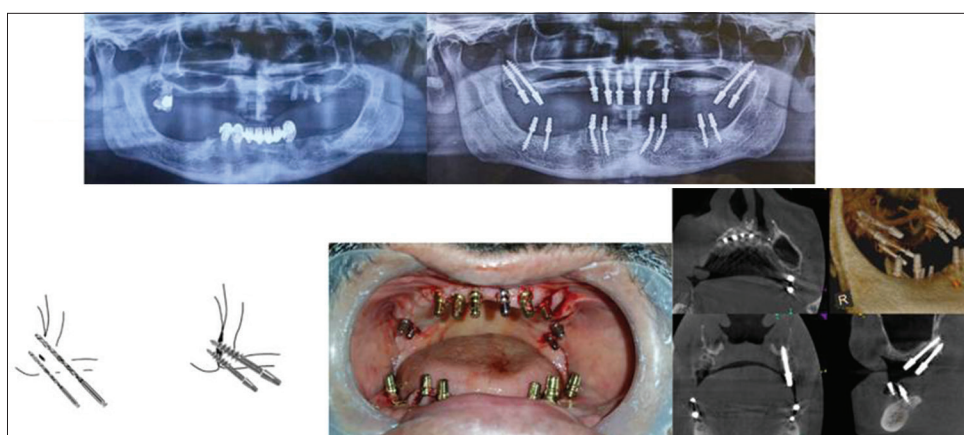


Figure 7: Double pterygoid approach

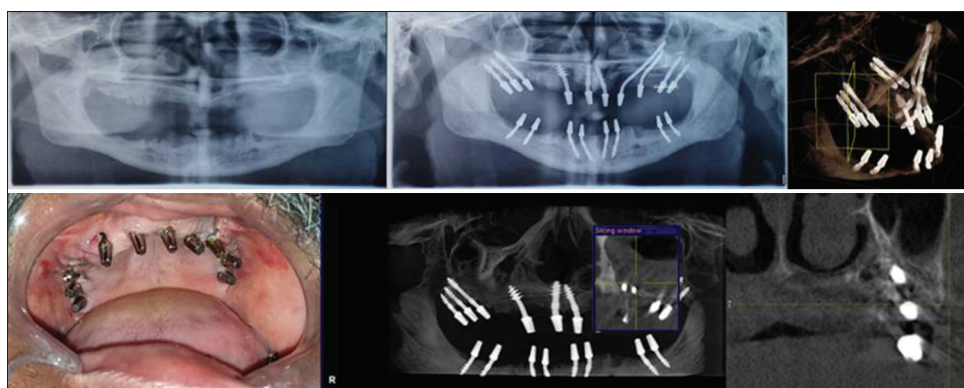


Figure 8: Triple pterygoid approach with flapless double zygomas

class 4 to class 6 ranging from the knife edge ridge form being adequate in height and inadequate in width to a flat ridge form, inadequate in height and width and leading to depressed ridge form. Luis *et al.*^[37] proposed the classification pterygoid anatomic radiographic prediction for the difficulty implied by implantology in the pterygoid region as well as the appropriate choice of the type of implant and length with which to approach it based on the sinus invasion obtained

after a three-dimensional computerized tomography. They concluded in a majority of cases of the large sinus invasion, leaving the remaining bone smaller than 5 mm, the possibility of using long pterygoid implants or opting for other surgical approaches can be evaluated. For conventional root form implants, the need to have crestal bone width is mandatory for the surgical placement. Since the posterior of maxillary arch undergoes centripetal resorption and with prolonged

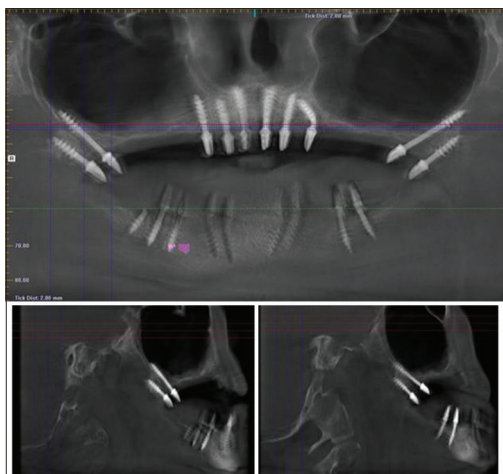


Figure 9: Left side double pterygoid implants demonstrating perfect pterygoid apophysis anchorage

edentulism, the frequent appearance of fatty degeneration in the posterior maxilla probably contributes to its lowest composite apparent density and relatively high Hardness (H) indicating low fracture toughness.^[38] Density in the tuberosity area ranged from 285.8 to 329.1 DV units and density in the pterygoid plate area from 602.9 to 661.2 DV units. Moreover, the density in the pterygoid area was 139.2% greater than the tuberosity zone.^[39] This leads to relatively easy fracture of distal maxillary bone during surgical drilling and implant insertion, making it prone to crestal bone resorption of an implant exposing the rough surface leading to delayed complication like peri-implantitis even if the fixture survives initially because of high primary stability achieved from pterygoid apophysis anchorage.

A single piece smooth surface bicortical implant based on Toulouse lag screw design with a different apical thread diameter and core diameter was used. Later, a smaller core than the thread diameter is implemented to overcome the restriction regarding crestal bone width being faced when placing conventional rough surface root form design fixtures in atrophic distal maxillary.^[40] These implants are placed flapless with ease without dependence of the crestal bone width or the 1st cortical to get anchored in 2nd or 3rd corticals of the jaw bone.^[41] They come under the classification of corticobasal jaw implants.^[41] One-piece or single implants are defined in the literature as implants in which the anchorage unit and the contiguous transmucosal component are manufactured in one piece.^[42,43] Any surface of implants having roughness more than 0.2 microns and high surface energy facilitate the biofilm formation over the fixture surface. Biofilm is a microbial-derived sessile community characterized by cells that are irreversibly attached to a substratum or interface to each other, embedded in a matrix of extracellular polymeric substance produced by microbes.

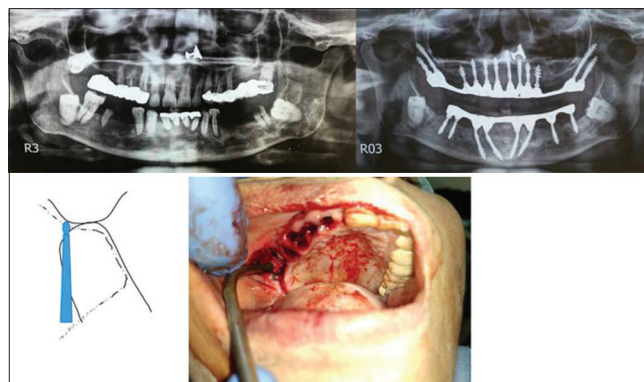


Figure 10: Pterygoid approach by open method

Biofilm attracts the plaque and so does the bacterial colonization which exhibit clinically as reversible mucositis and irreversible peri-implantitis, which is one of the most common cause of osseointegrated surface treated implant failures and late complications.^[44] The biological seal that is formed by the mucosa surrounding smooth surface dental implants is established to provide protection against the microbial invasion.^[45,46] Zhong *et al.*^[47] in their study observed direct attachment of sinus membrane to the implant, forming the barrier to the sinus cavity. Petruson^[48] used sinuscopy of the maxillary sinuses of 14 patients with machined surface zygomatic implants, placed with no particular care regarding whether or not membrane disruption occurred, and found no signs of adverse reactions. Petruson^[49] reported no increased risk of inflammatory reactions in the normal nasal and maxillary mucosa in regions where the titanium implant would pass through. The nitric oxide produced in the maxillary sinuses may therefore be another important explanation of why no infections are found around titanium implants.^[50,51] The resorption of the tuberosity does not have adverse effect on the exposed smooth surface of bicortical implant^[52] as the apical threads are anchored in the pterygoid apophysis and the smooth surface titanium core body when placed trans-sinus for pterygoid apophysis placement doesn't create adverse reaction from the Schneiderian membrane. Gapski *et al.*^[23] suggested the initial mechanical interlocking between threads and dense bone like of pterygoid apophysis, may overcome the beneficial properties that each coating type provide, thus the surface treated implants does not hold any benefit in high mineralized bone when the delayed complication like peri-implantitis is to be taken account.

Primary stability can be enhanced when cross-arch implant splinting is performed. Cantilevers were advised to be avoided in the fixed implant restorations since they increase load to the terminal fixture by 2-fold. Complications associated with posterior cantilevers include screw loosening and fracture, bone loss around the distal fixtures, and loss of osseointegration.^[53-55]

Zygomatic implants have been popularized for avoiding cantilever failed to do so completely.^[56] Pterygoid approach is the only way avoiding cantilevers in prosthetic rehabilitation.

There are surgical advantages involved in both the single stage guided surgery and single stage free hand approaches. The freehand techniques allow the ability to adjust or re-angle the osteotomy site based on what the surgeon encounters. In addition, the free-hand technique offers better firsthand visualization of the surgical site and the opportunity to alter bone or soft tissue while the mucosa is reflected when necessary.^[57] Rodriguez *et al.*^[53] observed average length from the tuberosity to the most apical point of the pterygoid apophysis was 22.5 +_ 4.8 mm. Tuberosity area has thicker mucosa in the range of 3 to 7 mm. Thus, for single piece implant, endosseous and mucosal length is calculated as a whole and the length of the pterygoid implant is comfortable until 29 mm. Moon *et al.*^[57] calculated the mean angular error between the preoperative planned and postoperative placed implant as $3.84^\circ \pm 1.49^\circ$ and Di Giacomo *et al.*^[58] calculated an angular error of $7.25^\circ \pm 2.67^\circ$. Particularly for an angular error, the utilization of surgical guides as a tooth support was reported to result in a smaller angular error than that of bone support and a mucosa support. The longer implants with such angular error may lead to apical deviation and may miss the intended anchorage site, hence the author prefers the free hand placement based on tactile perception rather than the computerized tomogram guided surgical guide, but it's the individual's preference based on the experience. Plenty of literature supported the computerized tomogram-based surgical guide for the flapless implant placement.

Mastication dynamics also effect the long-term stability of the implants placed in the posterior maxilla. At incisor region, masticatory forces are reported of 155N, and at premolar and molar, forces exhibited are 288N and 565N, respectively. Parafunction can increase these forces as much as three-fold, applying significant stress to the bone-implant interface and the component hardware.^[37] Thus, multiple implants in pterygoid apophysis, especially in post ablative surgical cases, are always advantageous with cross-arch rigid fixation. Not all the pterygoids engaged at pterygoid pillar achieve similar insertion torque as of variated anatomical shapes of the targeted site [Figure 1b; Lee *et al.* classification] and not all the individuals has the uniform pterygoid implant torque value as of their variated bone density because of age and disease related osteoporosis and osteopenia;^[59] insertion of an implant triggers reparative osteogenesis resulting in shaping of bone through reabsorption and consolidation, which leads to mature bone formation as the fixtures being in function.^[60]

CONCLUSION

Single-piece bicortical implants with flapless approach for pterygoid anchorage does have an advantage over surface-treated conventional root form design in overcoming the limitations regarding atrophied tuberosity with pneumatized maxillary sinus expanded distally, as the primary retention of the fixture is not dependent on the crestal bone at tuberosity but the sheer engagement of pterygoid pillar. The advantage is clearly reflected in case where pterygoid implant is placed after 3rd molar deimpaction with immediate placement and loading. The senior author has marked the difference between the pterygoid and tuberopterygoid implant by definition.

TAKE-AWAY POINTS

Pterygoid implant needs to engage, through apical threads via the highly mineralized bony column, into the pterygoid pillar. The direction is toward the hamular notch but lateral to the Hamular process. A safe distance of 5 mm should be kept for the purchase point of the osteotomy away from the palatal margin of the alveolar crest around the tuberosity, least the implant slips toward the undercut of the palatal foramen traumatizing the emerging neurovascular bundle. When the osteotomy is directed toward the hamular notch and medial of hamular process it is always at a safe distance medial to the lateral pterygoid plate and its muscular attachment, thus keeping safe from the branches of the internal maxillary artery and the pterygoid plexus situated laterally of pterygoid plates in infratemporal fossa [Figure 4]. If the osteotomy slips medially, the bleeding from the palatine vessel can be easily controlled by pressing the thick palatal mucosa against the palatal vault. If osteotomy slips lateral to the hamular notch or the bleeding incident from the osteotomy opening occurs, which may be from arteriovenous supply of the pterygoid muscle, by pressing two fingers vestibular and palatal of the pterygomaxillary fissure, it's easily controlled. The author advices first to arrest bleeding and then to proceed with the implant placement in order to avoid retrograde hematoma formation.

Financial support and sponsorship

Nil.

Conflicts of interest

There are no conflicts of interest.

REFERENCES

1. Brånemark PI, Adell R, Breine U, Hansson BO, Lindström J, Ohlsson A. Intra-osseous anchorage of dental prostheses. I. Experimental studies. *Scand J Plast Reconstr Surg* 1969;3:81-100.

2. Brånemark PI, Hansson BO, Adell R, Breine U, Lindström J, Hallén O, *et al.* Osseointegrated implants in the treatment of the edentulous jaw. Experience from a 10-year period. *Scand J Plast Reconstr Surg Suppl* 1977;16:1-132. PMID: 356184.
3. Adell R, Lekholm U, Rockler B, Brånemark PI. A 15-year study of osseointegrated implants in the treatment of the edentulous jaw. *Int J Oral Surg* 1981;10:387-416.
4. Albrektsson T, Zarb G, Worthington P, Eriksson AR. The long-term efficacy of currently used dental implants: A review and proposed criteria of success. *Int J Oral Maxillofac Implants* 1986;1:11-25.
5. Albrektsson T, Jansson T, Lekholm U. Osseointegrated dental implants. *Dent Clin North Am* 1986;30:151-74.
6. Albrektsson T, Zarb GA. Current interpretations of the osseointegrated response: Clinical significance. *Int J Prosthodont* 1993;6:95-105.
7. Albrektsson T. On long-term maintenance of the osseointegrated response. *Aust Prosthodont J* 1993;7 Suppl: 15-24.
8. Arvidson K, Bystedt H, Frykholm A, von Konow L, Lothigius E. A 3-year clinical study of Astra dental implants in the treatment of edentulous mandibles. *Int J Oral Maxillofac Implants* 1992;7:321-9.
9. Astrand P, Almfeldt I, Brunell G, Hamp SE, Hellem S, Karlsson U. Non-submerged implants in the treatment of the edentulous lower jaw. A 2-year longitudinal study. *Clin Oral Implants Res* 1996;7:337-44.
10. Buser DA, Schroeder A, Sutter F, Lang NP. The new concept of ITI hollow-cylinder and hollow-screw implants: Part 2. Clinical aspects, indications, and early clinical results. *Int J Oral Maxillofac Implants* 1988;3:173-81.
11. Buser D, Brägger U, Lang NP. Implantology. Implantological care of the free-end situation in the mandible. *Schweiz Monatsschr Zahnmed* 1988;98:746-57.
12. Piattelli A, Ruggeri A, Franchi M, Romasco N, Trisi P. An histologic and histomorphometric study of bone reactions to unloaded and loaded non-submerged single implants in monkeys: A pilot study. *J Oral Implantol* 1993;19:314-20.
13. Henry P, Rosenberg I. Single-stage surgery for rehabilitation of the edentulous mandible: Preliminary results. *Pract Periodontics Aesthet Dent* 1994;6:15-22.
14. Salama H. A multidisciplinary approach to implant dentistry: Prosthodontics, periodontics, orthodontics-Part II. *Dent Implantol Update* 1995;6:77-9.
15. Salama H. Prosthodontics, periodontics, and orthodontics: A multidisciplinary approach to implant dentistry-Part I. *Dent Implantol Update* 1995;6:65-8.
16. Chiapasco M, Gatti C, Rossi E, Haefliger W, Markwalder TH. Implant-retained mandibular overdentures with immediate loading. A retrospective multicenter study on 226 consecutive cases. *Clin Oral Implants Res* 1997;8:48-57.
17. Tarnow DP, Emtiaz S, Classi A. Immediate loading of threaded implants at stage 1 surgery in edentulous arches: Ten consecutive case reports with 1- to 5-year data. *Int J Oral Maxillofac Implants* 1997;12:319-24.
18. Randow K, Ericsson I, Nilner K, Petersson A, Glantz PO. Immediate functional loading of Brånemark dental implants. An 18-month clinical follow-up study. *Clin Oral Implants Res* 1999;10:8-15.
19. Scortecchi G. Immediate function of cortically anchored disk-design implants without bone augmentation in moderately to severely resorbed completely edentulous maxillae. *J Oral Implantol* 1999;25:70-9.
20. Maló P, Rangert B, Dvårsäter L. Immediate function of Brånemark implants in the esthetic zone: A retrospective clinical study with 6 months to 4 years of follow-up. *Clin Implant Dent Relat Res* 2000;2:138-46.
21. Ihde S, Kopp S, Maier T. Comparison of implant survival with implants placed in acceptable and compromised bone: A literature review. *J Maxillofac Oral Surg* 2009;8:1-7.
22. Shan L, Zhou G, Li X, Qie H, Dong F. Mini-implant stability analysis at different healing times before loading. *Hua Xi Kou Qiang Yi Xue Za Zhi* 2013;31:557-60.
23. Gapski R, Wang HL, Mascarenhas P, Lang NP. Critical review of immediate implant loading. *Clin Oral Implants Res* 2003;14:515-27.
24. Sorni M, Guarinos J, Peñarrocha M. Implants in anatomical buttresses of the upper jaw. *Med Oral Patol Oral Cir Bucal* 2005;10:163-8.
25. Krekmanov L, Kahn M, Rangert B, Lindström H. Tilting of posterior mandibular and maxillary implants for improved prosthesis support. *Int J Oral Maxillofac Implants* 2000;15:405-14.
26. Krekmanov L. Placement of posterior mandibular and maxillary implants in patients with severe bone deficiency: A clinical report of procedure. *Int J Oral Maxillofac Implants* 2000;15:722-30.
27. Tulasne JF. Osseointegrated fixtures in the pterygoid region. In: Worthington P, Branemark PI, editors. *Advanced Osseointegration Surgery. Applications in the Maxillofacial Region*. Chicago: Quintessence; 1992. p. 182-8.
28. Bahat O. Osseointegrated implants in the maxillary tuberosity: Report on 45 consecutive patients. *Int J Oral Maxillofac Impl* 1992;7:459-67.
29. Apinhasmit W, Chompoonong S, Methathathip D, Sangvichien S, Karuwanarint S. Clinical anatomy of the posterior maxilla pertaining to Le Fort I osteotomy in Thais. *Clin Anat* 2005;18:323-9.
30. Wentges RT. Surgical anatomy of the pterygopalatine fossa. *J Laryngol Otol*. 1975;89h:35-45. doi: 10.1017/s0022215100080051. PMID: 1113030.
31. Balcioglu HA, Kilic C, Varol A, Ozan H, Kocabiyik N, Yildirim M. A morphometric study of the maxillary artery and Lingula in relation to mandibular ramus osteotomies and TMJ surgery. *Eur J Dent* 2010;4:166-70.
32. Rajeshwari MS, Pushpa MS. Study of lateral pterygoid muscle and its relation with the maxillary artery and buccal nerve and an anatomical classification based on its insertion. *Int J Anat Res* 2015;3:1680-4.
33. Reiser GM. Implant use in the tuberosity, pterygoid, and palatine region: Anatomic and surgical considerations. In: Nevins M, Mellonig JT, editors. *Implant Therapy Clinical Approaches and Evidence of Success*. Vol. 2. Chicago: Quintessence; 1998. p. 197.
34. Gaur V, Ihde S, Sekhar R. Considerations Regarding Treatment Options and Technique for Cortically Anchored Implants in the Distal Maxilla. *IOSR-JDMS* 2019;18:28-37.
35. Schnitman P, DaSilva J, Wöhrle P, Wang H, Koch G. Influence of site on implant survival: Seven-year results [abstract 1664]. *J Dent Res* 1993;72:311.
36. Cawoodand JL, Howell RA. A classification of the edentulous jaws. *Int J Oral Maxillofac Surg* 1988;17:232-6.
37. Luis SS, de Barutell CA, Elena T. PARP: Diagnostic Prediction for the Choice of Clinical Strategies in the Pterygomaxillary Region; 2016. p. 2-11.
38. Seong WJ, Kim UK, Swift JQ, Heo YC, Hodges JS, Ko CC. Elastic properties and apparent density of human edentulous maxilla and mandible. *Int J Oral Maxillofac Surg* 2009;38:1088-93.
39. Rodríguez X, Lucas-Taulé E, Elnayef B, Altuna P, Gargallo-Albiol J, Peñarrocha Diago M, *et al.* Anatomical and radiological approach to pterygoid implants: a cross-sectional study of 202 cone beam computed tomography examinations. *Int J Oral Maxillofac Surg*. 2016;45:636-40. doi: 10.1016/j.ijom.2015.12.009. Epub 2016 Jan 4. PMID: 26768019.
40. Atlas of Craniomaxillofacial Osteosynthesis: Microplates, Miniplates, and Screws. In: Champy HF, Terry BM. 2nd ed. Stuttgart, Germany: Thieme Medical Publishers; ISBN: 9783131164926.
41. Ihde S, Ihde A, Lysenko V, Konstantinovic V, Palka L. New systematic terminology of cortical bone areas for osseofixated implants in strategic oral implantology. *J J Anatomy* 2016;1:007.
42. Ihde S. Indications and treatment modalities with corticobasal jaw implants. *Ann Maxillofac Surg* 2019;9:379-86.
43. Laney WR. Glossary of Oral and Maxillofacial Implants. Berlin: Quintessence; 2008.
44. BarrachinaDíez, Tashkandi E, Stampf S, Att W. Longterm outcome of onepiece implants. Part II: Prosthetic outcomes. A systematic

- literature review with metaanalysis. *Int J Oral Maxillofac Implants* 2013;28:147082.
45. Subramani K, Jung RE, Molenberg A, Hammerle CH. Biofilm on dental implants: A review of the literature. *Int J Oral Maxillofac Implants* 2009;24:616-26.
 46. Neiva R., Neiva K, Oh T., Wong H. Clinical and morphological aspects of the implant/soft tissue interface. *Int Chin J Dent* 2002;2:151-61.
 47. Zhong W, Chen B, Liang X, Ma G. Experimental study on penetration of dental implants into the maxillary sinus in different depths. *J Appl Oral Sci* 2013;21:560-6.
 48. Petruson B. Sinuscopy in patients with titanium implants in the nose and sinuses. *Scand J Plast Reconstr Surg Hand Surg* 2004;38:86-93.
 49. MacMicking J, Xie QW, Nathan C. Nitric oxide and macrophage function. *Annu Rev Immunol* 1997;15:323-50.
 50. Runer T, Cervin A, Lindberg S, Uddman R. Nitric oxide is a regulator of mucociliary activity in the upper respiratory tract. *Otolaryngol Head Neck Surg* 1998;119:278-87.
 51. Marrone A, Lasserre J, Bercy P, Brex MC. Prevalence and risk factors for peri-implant disease in Belgian adults. *Clin Oral Implants Res*. 2013;24:934-40. doi: 10.1111/j.1600-0501.2012.02476.x. Epub 2012 May 3. PMID: 22551347.
 52. Balshi TJ, Wolfinger GJ, Slauch RW, Balshi SF. A retrospective comparison of implants in the pterygomaxillary region: Implant placement with two-stage, single-stage, and guided surgery protocols. *Int J Oral Maxillofac Implants* 2013;28:184-9.
 53. Rodríguez X, Rambla F, De Marcos Lopez L, Méndez V, Vela X, Jiménez García J. Anatomical study of the pterygomaxillary area for implant placement: Cone beam computed tomographic scanning in 100 patients. *Int J Oral Maxillofac Implants* 2014;29:1049-52.
 54. Balshi TJ. Preventing and resolving complications with osseointegrated implants. *Dent Clin North Am* 1989;33:821-68.
 55. Shackleton JL, Carr L, Slabbert JC, Becker PJ. Survival of fixed implant-supported prostheses related to cantilever lengths. *J Prosthet Dent* 1994;71:23-6.
 56. Bothur S, Jonsson G, Sandahl L. Modified technique using multiple zygomatic implants in reconstruction of the atrophic maxilla: A technical note. *Int J Oral Maxillofac Implants* 2003;18:902-4.
 57. Moon SY, Lee KR, Kim SG, Son MK. Clinical problems of computer-guided implant surgery. *Maxillofac Plast Reconstr Surg* 2016;38:15.
 58. Di Giacomo GA, Cury PR, de Araujo NS, Sendyk WR, Sendyk CL. Clinical application of stereolithographic surgical guides for implant placement: Preliminary results. *J Periodontol* 2005;76:503-7. doi: 10.1902/jop.2005.76.4.503. PMID: 15857088.
 59. Balshi TJ, Wolfinger GJ. Management of the posterior maxilla in the compromised patient: Historical, current, and future perspectives. *Periodontol 2000* 2003;33:67-81.
 60. Zurdo J, Romá OC, Wennstro MJ. Survival and complication rates of implant-supported fixed partial dentures with cantilevers: A systematic review. *Clin Oral Impl Res* 2009;20 Suppl 4:59-66.