

Deep vein thrombosis of upper extremities due to reactive thrombocytosis in septic patients

Shakti Bedanta Mishra, Jashwini Bhojer, Mohan Gurjar, Nabeel Muzaffar, Anupam Verma¹

Abstract

Deep venous thrombosis (DVT) is not an uncommon condition in the intensive care unit (ICU), and having high morbidity and mortality. Upper limb DVT also is increasingly being recognized as a clinical entity. The presence of the indwelling catheter in neck veins is a risk for developing venous thrombus, which may be further aggravated by presence of thrombocytosis. In ICU patients with sepsis, reactive thrombocytosis has been found during the recovery phase. Here, we are presenting two cases, having thrombocytosis and central venous catheter who developed upper limb DVT.

Keywords: Central venous catheter, deep venous thrombosis, thrombocytosis

Access this article online

Website: www.ijccm.org

DOI: 10.4103/0972-5229.138162

Quick Response Code:



Introduction

Deep venous thrombosis (DVT) is a common condition that affects approximately 1 in 1000 persons/year.^[1] DVT has a prevalence of 10.5-11.9% in patients who are admitted in intensive care unit (ICU) among Indian patients.^[2] DVT was noticed in 33% of ICU admission as per international data.^[3] Upper limb DVT is increasingly being recognized as a clinical entity with potential for considerable morbidity. It usually refers to thrombosis of the axillary or subclavian veins, occurs spontaneously or sometimes develops as a complication of pacemaker use, long-term central venous catheter (CVC) use, or cancer. Approximately, 10% of all cases of deep-vein thrombosis involve the upper extremities, resulting in an annual incidence of 0.4-1 case/10,000 people.^[4] Here, we are presenting two cases who had developed upper limb DVT while resolving phase of their sepsis with reactive thrombocytosis.

Case Report

Case 1

A 37-year-old man referred to our ICU with acute respiratory distress syndrome (ARDS) and septic shock on the 23rd day of his illness. He had H1N1 influenza viral infection, confirmed by reverse transcription polymerase chain reaction method. At admission, vitals were: Heart rate 140/min, blood pressure (mean) 70 mmHg on noradrenaline infusion (20 µg/min). Arterial blood gas was pH 7.23, pO₂ 110 mmHg and pCO₂ 52 mmHg. His ventilatory requirement was positive end-expiratory pressure (PEEP) of 14 cm H₂O and FiO₂ of 0.70 with PaO₂/FiO₂ (P/F) ratio 160. His laboratory parameters on admission was hemoglobin 12 g/dl, total leukocyte count (TLC) 18,000 and platelet count of 165 (×10⁹/L). Before admission, he had platelet count ranging from 83 to 163 (×10⁹/L). Lung protective ventilation was continued and prone position ventilation sessions were given to improve P/F ratios. By day 7 of ICU stay his hemodynamics improved with no further need of vasopressor. During follow-up, he had thrombocytosis during 2nd week (622-707 × 10⁹/L). He was tracheostomized on 8th day of intubation. His coagulation profile was normal throughout his ICU stay. He was receiving DVT prophylaxis in appropriate doses. On day 14 of his stay swelling, was noted in the right upper limb. Bedside Doppler ultrasonography

From:

Departments of Critical Care Medicine and ¹Transfusion Medicine, Sanjay Gandhi Postgraduate Institute of Medical Sciences, Lucknow, Uttar Pradesh, India

Correspondence:

Dr. Mohan Gurjar, Department of Critical Care Medicine, Sanjay Gandhi Postgraduate Institute of Medical Sciences, Lucknow, Uttar Pradesh, India.
E-mail: m.gurjar@rediffmail.com

of bilateral jugular veins revealed thrombosed right internal jugular vein (IJV) suggestive of acute thrombus with no flow along entire length of cervical IJV extending into right subclavian vein. Magnetic resonance imaging venogram confirmed the findings; and thromboelastography (TEG) was done, which showed hypercoagulability [Figure 1]. He was started on injection enoxaparin 60 mg subcutaneous 12 hourly, with antiplatelet (aspirin). His clinical condition including ARDS improved over next 2 weeks. Later on, he had an uneventful course in the ICU and was discharged on oral anti-coagulant. He returned after 3 months for follow-up. The thrombus had recanalized with no residual limb edema and his platelet counts were back to normal.

Case 2

The second case is about a 29-year-old male patient who was admitted on the 12th day of his illness with acute viral encephalitis. He was from an endemic region for Japanese encephalitis. On admission in ICU, vitals were: Heart rate 110/min, mean blood pressure 82 mm of Hg (on noradrenaline infusion 10 µg/min). He required ventilatory support due to encephalopathy, and kept on synchronized intermittent mandatory ventilation mode with PEEP of 6 of cm H₂O. His arterial blood gas showed pH 7.34, pO₂ 100 mmHg and pCO₂ 42 mmHg on FiO₂ of 0.4 with P/F ratios around 250. He was fluid resuscitated along with other supportive care, which resulted in improvement in shock and stopping of vasopressor within 48 h of admission. His laboratory parameters were hemoglobin 10 g/dl, TLC 13,000, platelet 140 (×10⁹/L), creatinine 0.7 mg/dl. He continued to stay in the ICU in the view of difficult weaning due to his muscle weakness. He showed persistent thrombocytosis (537-827 × 10⁹/L) after 2 weeks of admission. On day 46th in ICU swelling was noted in his right arm. Doppler of his upper limb

showed evidence of thrombosis in both right subclavian vein and right IJV [Figure 2]. He was started on therapeutic doses of low molecular weight heparin along with aspirin. In at follow-up after 1-month, his thrombosis gradually resolved with recanalization of the vein, decrease in limb edema, and he is still on oral anti-coagulant.

Discussion

Thrombocytosis, that is, platelet count more than 450 × 10⁹/L, can be primary or reactive (secondary) in etiology. Reactive thrombocytosis is common and reported in various conditions such as inflammation, postsplenectomy, hematopoietic disorder, surgery and cancer. In these conditions, elevated endogenous levels of interleukin-6 (IL-6), interferon gamma (IFN-γ) are responsible for the thrombocytosis.^[5] IL-6 contributes to inflammatory thrombopoiesis predominantly by stimulating the hepatic production of thrombopoietin (TPO); while, IFN-γ has its effect on megakaryocytes growth. Furthermore, there is enhanced production of TPO, messenger ribonucleic acid and protein by stimulation of hepatocytes with IL-6.

In ICU patients' thrombocytosis is a commonly seen phenomenon, it's found in nearly 21% of patients admitted to an ICU.^[6] Due to relatively lesser platelet count and smaller mean platelet volume, pathologic thrombus is not so common in reactive thrombocytosis in comparison to primary thrombocytosis; unless it is aggravated by underlying disease process or any condition peculiar to the patient, e.g. atherosclerosis.^[5]

In the pathogenesis of DVT of upper extremity, presence of the indwelling catheter (CVCs, pacemaker, or defibrillator leads), cancer, surgery or trauma of the

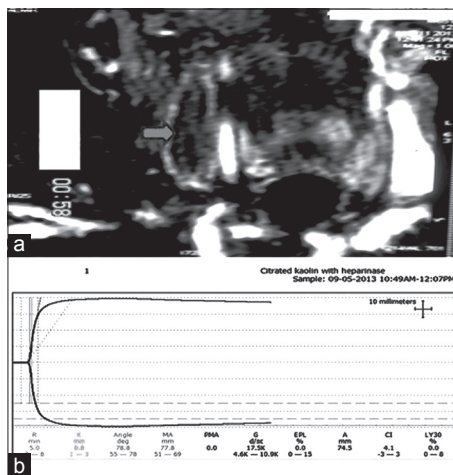


Figure 1: (a) The magnetic resonance venogram depicting thrombus in right internal jugular vein extending to right subclavian vein. (b) Thromboelastogram showing hypercoagulability

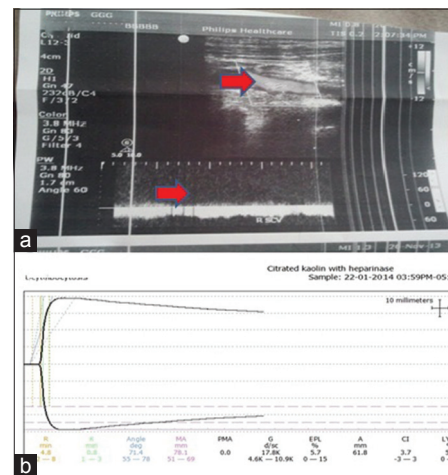


Figure 2: (a) Doppler ultrasonography showing thrombus in right internal jugular vein with no flow. (b) Thromboelastogram showing hypercoagulability

arm or shoulder are common and major risk factors.^[7] The prevalence of CVC-related upper limb DVT in cancer patients varies from 11.7% to 44%.^[8] In presented both cases, CVC were inserted in both neck vessels (IJV and subclavian vein) before diagnosis of DVT, and were not inserted after diagnosis of thrombosis and managed with catheter in the femoral vein. Furthermore, there were no evidences of central line-associated bloodstream infection.

In presented both cases, though patients had a risk factor of having CVCs previously at the site of thrombosis; the association of increased platelet count cannot be ruled out in pathogenesis of thrombosis. In further evaluation, TEG had increased maximum amplitude: 77.8 mm in the first patient and 78.1 mm in the second patient with a reference range 51–66 mm. The α angle was within normal limits depicting that the hypercoagulability is due to platelet and not enzyme activity. After the detection of DVT these patients were given the therapeutic doses of anti-coagulant for DVT along with anti-platelet (aspirin). There was no evidence of any more DVT or any other site of thrombosis in both these patients.

Conclusion

Intensive care unit patient having reactive thrombocytosis during the recovery phase of sepsis must be kept in

priority for screening to rule out DVT, so that timely therapeutic intervention could avoid a life-threatening pulmonary embolism.

References

1. Fowkes FJ, Price JF, Fowkes FG. Incidence of diagnosed deep vein thrombosis in the general population: Systematic review. *Eur J Vasc Endovase Surg* 2003;25:1-5.
2. Sharma SK, Gupta V, Kadiravan T, Banga A, Seith A, Kumar A, *et al.* A prospective study of risk factor profile and amp; incidence of deep venous thrombosis among medically-ill hospitalized patients at a tertiary care hospital in northern India. *Indian J Med Res* 2009;130:726-30.
3. Hirsch DR, Ingenito EP, Goldhaber SZ. Prevalence of deep venous thrombosis among patients in medical intensive care. *JAMA* 1995;274:335-7.
4. Joffe HV, Goldhaber SZ. Upper-extremity deep vein thrombosis. *Circulation* 2002;106:1874-80.
5. Kaushansky K. Reactive thrombocytosis. In: Lichtman MA, Kipps TJ, Seligsohn U, Kaushansky K, Prehal JT, editors. *Williams Hematology*. 8th ed., Ch. 120. New York: McGraw-Hill; 2010.
6. Gurung AM, Carr B, Smith I. Thrombocytosis in intensive care. *Br J Anaesth* 2001;87:926-8.
7. Kucher N. Clinical practice. Deep-vein thrombosis of the upper extremities. *N Engl J Med* 2011;364:861-9.
8. Kujur R, Rao SM, Badwaik G, Paraswani R. Thrombosis associated with right internal jugular central venous catheters: A prospective observational study. *Indian J Crit Care Med* 2012;16:17-21.

How to cite this article: Mishra SB, Bhojer J, Gurjar M, Muzaffar N, Verma A. Deep vein thrombosis of upper extremities due to reactive thrombocytosis in septic patients. *Indian J Crit Care Med* 2014;18:540-2.

Source of Support: Nil, **Conflict of Interest:** None declared.