



Since January 2020 Elsevier has created a COVID-19 resource centre with free information in English and Mandarin on the novel coronavirus COVID-19. The COVID-19 resource centre is hosted on Elsevier Connect, the company's public news and information website.

Elsevier hereby grants permission to make all its COVID-19-related research that is available on the COVID-19 resource centre - including this research content - immediately available in PubMed Central and other publicly funded repositories, such as the WHO COVID database with rights for unrestricted research re-use and analyses in any form or by any means with acknowledgement of the original source. These permissions are granted for free by Elsevier for as long as the COVID-19 resource centre remains active.

Systemic Lupus Induced by Messenger RNA Vaccination



To the Editor: We report the case of a woman in her 20s who developed systemic lupus erythematosus after messenger RNA vaccination against severe acute respiratory syndrome coronavirus 2 (SARS-CoV-2). She had no medical history and was not taking any medication. She has a twin sister with no medical history. An inflammatory polyadenopathy involving the cervical, axillary, and inguinal regions developed 7 days after the first injection (Comirnaty). She had no other symptoms, notably no fever or fatigue.

One month later, despite the persistence of adenopathy, she received a second vaccine injection, and bilateral polyarthritides of the metacarpophalangeal joints, proximal interphalangeal joints, and wrists developed 7 days later. She also noticed the appearance of typical Raynaud phenomenon (Figure). At the same time, a progressive asthenia and an increase of her symptoms set in during 3 weeks.

She was admitted for further investigation. The clinical

examination revealed supracentimetric adenopathies, laterocervical, supraclavicular, axillary, and inguinal, painful to palpation, as well as a discrete hepatomegaly. No skin lesions were observed. The biological work-up showed autoantibodies with antinuclear factors at 1/1280 with anti-native DNA antibodies at 586 IU/mL and positive antihistone and antinucleosome antibodies with consumption of complement and its fractions. Creatinine level was normal without proteinuria. HIV serology was negative. The capillaroscopy was normal. The thoracic and abdomen-pelvic computed tomography scan confirmed hepatomegaly, without splenomegaly or deep adenopathy. A lymph node biopsy was performed without any germ found on direct examination. Tuberculosis polymerase chain reaction came back negative, and cytologic examination revealed a lymphadenitis without tumor proliferation.

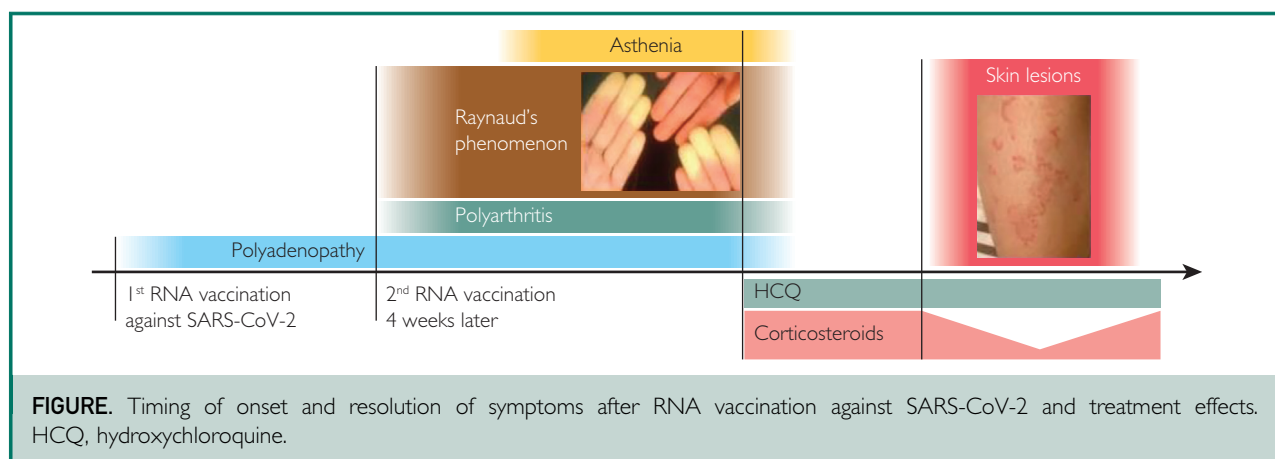
We eventually retained the diagnosis of systemic lupus erythematosus induced by vaccination and then initiated treatment with hydroxychloroquine and systemic corticosteroid therapy. All symptoms rapidly regressed under treatment. Skin lesions on the lower limbs compatible

with subacute annular lupus (Figure) appeared after the decrease of corticosteroid therapy, which resolved after resumption of the initial dosage.

To our knowledge, this is the first description of lupus occurring after vaccination with messenger RNA. Two other cases of lupus occurring after COVID-19 vaccination have been described but with nonreplicating viral vector vaccines.^{1,2}

Lupus cases have also been reported with other nonreplicating viral vector vaccine targets. A search of the French national pharmacovigilance database for this vaccine identified 7 cases of lupus exacerbation in patients previously observed for this condition, which has already been reported.^{3,4}

Despite the reported cases, vaccination remains an essential part of the fight against the current pandemic, including in patients with lupus.⁵ The reporting of this case is obviously not intended to question the current vaccine strategy but to inform the medical scientific community of the possibility of autoimmune disease induced by messenger RNA vaccines, although extremely rare in view of the number of vaccinations administered to date throughout the world.



POTENTIAL COMPETING INTERESTS

The authors report no competing interests.

Olivier Voisin, MD
Etienne Raphaël

Department of Internal Medicine, Groupe Hospitalier Paris Saint-Joseph, Paris, France

Pascal Priollet, MD

Department of Vascular Medicine, Groupe Hospitalier Paris Saint-Joseph, Paris, France

1. Kreuter A, Burmann SN, Burkert B, Oellig F, Michalowitz AL. Transition of cutaneous into systemic lupus erythematosus following adenoviral vector-based SARS-CoV-2 vaccination. *J Eur Acad Dermatol Venereol*. 2021;35(11):e733-e735.
2. Zavala-Miranda MF, González-Ibarra SG, Pérez-Arias AA, Uribe-Uribe NO, Mejía-Vilet JM. New-onset systemic lupus erythematosus beginning as class V lupus nephritis after COVID-19 vaccination. *Kidney Int*. 2021;100(6):1340-1341.
3. Joseph AK, Chong BF. Subacute cutaneous lupus erythematosus flare triggered by COVID-19 vaccine. *Dermatol Ther*. 2021;34:e15114.
4. Sekar A. Lupus nephritis flare post Moderna mRNA-1273 coronavirus vaccine. *QJM*. 2022;114(12):882-883.
5. Chowdhary VR. Broad concepts in management of systemic lupus erythematosus. *Mayo Clin Proc*. 2017;92(5):744-761.

<https://doi.org/10.1016/j.mayocp.2022.05.001>

HeartWare Thrombosis After mRNA COVID-19 Vaccination



To the Editor: A woman in her late 50s with end-stage heart failure secondary to nonischemic dilated cardiomyopathy was implanted with a HeartWare left ventricular assist device (LVAD) as bridge to transplant. She was not known to have a hypercoagulable condition and in the 6 years supported on the LVAD before presentation had not experienced power elevations, high watts alarms, or any evidence of hemolysis/thrombosis or hemocompatibility-related adverse event. She was not actively listed for transplant because of personal preference.

She received the initial series of 2 COVID-19 vaccinations with the BNT162b2 (Pfizer-BioNTech COVID mRNA vaccine) and underwent COVID-19 booster 7 months later. She had no immediate reaction and described only arm soreness after the booster. Eight days later, she noted an episode of tea-colored urine but did not notify the LVAD team. Eleven days after the booster, the LVAD team was contacted with concerns of chest pressure and high watts alarms, and the patient reported to the emergency department. There, an episode of hematuria was noted; international normalized ratio was 2.9, and metabolic panel returned hemolyzed. All international normalized ratio readings in the 2 months preceding admission were between 2.4 and 3.9; none were subtherapeutic. She had been compliant with daily aspirin 325 mg daily since implantation.

On admission, powers were noted to be elevated, and initial lactate dehydrogenase (LDH) level was above 3000 U/L. Pump thrombosis was diagnosed, and United Network for Organ Sharing listing status was upgraded appropriately. During the hospitalization course, despite adequate antithrombotic therapy (tirofiban, heparin, and aspirin 325 mg twice daily), powers continued to rise (Figure A, C) and LDH remained markedly elevated (Figure C). HeartWare powers and estimated flows exceeded 20 W and 10 L/min, respectively, and LDH levels peaked at 4458 U/L (Figure C). Given concerns for imminent pump stoppage, she underwent exchange from HeartWare to HeartMate 3 (Thoratec) 10 days after admission, with HeartWare device demonstrating thrombus within the pump housing (Figure B).

COVID mRNA vaccinations are broadly recommended for all

patients, including those supported on LVAD therapy, with exceedingly low risk of complications after vaccination.¹ Yet, reports have described increased arterial thromboembolism risk and cerebral venous sinus thrombosis risk after Pfizer-BioNTech vaccine² and an increased venous thromboembolism signal after the first Pfizer-BioNTech vaccine dose.³ These observations highlight the possibility that a proinflammatory milieu after vaccination may increase the risk of thrombosis on rare occasions.

Vaccine-induced thrombotic thrombocytopenia and thrombosis with thrombocytopenia syndrome are phenomena that have been reported after COVID vaccinations with pathophysiologic mechanisms that are presently being studied.^{4,5} Our patient received a Pfizer-BioNTech vaccine 8 days before report of tea-colored urine, had a platelet count of less than $150 \times 10^9/L$ before device exchange, and had confirmed device thrombosis but did not complete all the testing required for the diagnosis to be made before device exchange, raising consideration for potential risk of thrombosis for patients on the thrombosis with thrombocytopenia syndrome spectrum.

Additional reports from other centers with LVAD-supported patients who receive COVID vaccinations may help elucidate a causality and begin to estimate a frequency of what is suspected to be a rare phenomenon. This experience does not represent a contraindication to vaccination; rather, it highlights the importance for LVAD clinicians to remain vigilant and to avoid neglecting an LDH rise or reports of dark urine in the context of recent COVID-19 vaccination among LVAD-supported patients.