



Functional medicine

## Urinoma as the result of a 3mm stone in ipsilateral ureter: A rare case report

Fateme Guitynavard, Seyed Saeed Tamehri Zadeh, Elham Tehranipour,  
 Mohammad Mehdi Rakebi, Seyed Mohammad Kazem Aghamir\*

*Urology Research Center, Tehran University of Medical Sciences, Tehran, Iran*



### ARTICLE INFO

#### Keywords:

Urinary leakage  
 Urinoma  
 Ipsilateral ureter stone

### ABSTRACT

Leakage from the kidney, ureter, bladder, and urethra, which mainly occur due to trauma, forms urinoma. The best tool for diagnosis of urinoma is enhanced-computed tomography with delayed imaging. Apart from injury, ureteral stone can induce urinoma, however, it is rare. Herein, we report a case with urinoma, which probably formed as a result of overdistention of renal pelvis after a large amount of fluid intake (about 3 L) in a short period of time (about an hour) in the presence of a 3mm stone in ipsilateral ureter.

### Introduction

Urinoma, which forms as a result of disruption mainly in kidney collecting system, experienced by 1%–7% of renal trauma patients.<sup>1</sup> Also there is a possibility that at beginning, urinoma could be clinically asymptomatic but may present itself with pain and lead to complications including, but not limit to, hydronephrosis, imbalance of electrolyte, ileus, and abscess. The diagnosis of urinoma can be complex due to similarity in appearance to several conditions such as pelvic hematoma, cystic masses, ascites and etc. Reports have shown a number of causes of urinoma formation such as ureteral tumor and ureteral stone, but the main reason of urinoma is kidney trauma.<sup>2</sup>

### Case presentation

A 42 years old man was admitted to Department of emergency medicine at Sina Hospital because of left flank pain, which was lasted at least for 2 hours. The pain awakened the patient at 4 a.m. and the patient's pain, which was spread to suprapubic, worsened. The patient had no complications of fever, hematuria, urinary obstructive symptoms, and urinary irritation symptoms. He also had no history of renal or ureteral stone and renal trauma. He noticed that 6 hours before flank pain had been initiated, about 3 L of fluid was consumed by him in less than an hour, following of a 16-h-fasting. An abdominal sonography was performed and a massive perirenal urinoma around the left kidney, was detected. Thereafter, the patient was undergone abdominopelvic computed tomography (CT) (Fig. 1) and in addition to urinoma, a small 3mm stone in the distal of left ureter was seen. Meanwhile, serological

and urine tests were carried out and the results were as follows: WBC = 8000, Hb = 15.1, PLT = 25,200, Cr = 1.0, Bun = 17, U/A: WBC = 10–15, RBC = many, Bacteria: negative.

Patient's pain was not attenuated by morphine and the patient was taken to the operating room. By ureteroscopy, the stone was detected at the distal of left ureter and was removed through trans ureteral lithotripsy (TUL). Then ureteroscopy continued through the mid- and proximal ureter. At the ureteropelvic junction, very inflamed and bloody area with a slit-like defect was seen on the lateral side of the ureter. Under guidewire guidance, a double J stent successfully bypassed the defect and placed into the renal pelvis.

### Discussion

An extravasation from any organ that participates in urine formation (kidney, ureter, bladder, and urethra) could form urinoma, which is not a frequent disease and it can be surrounded by fibrous capsule or appear as free fluid. Inducing kidney urinoma formation usually attribute to non-obstructive causes such as trauma to the collecting system. In contrast to kidney urinoma, iatrogenic injuries to ureter due to genitourinary, retroperitoneal, and gynecologic surgery are the main causes of ureteral urinoma.<sup>3</sup> One of the rarest causes of urinoma is ureteral impact stones, which forms urinoma through perforation in ureter and this cause could face doctors with difficulty in terms of diagnosis and treatment. The plausible explanation for urinoma formation in our patient is a sudden overdistention of renal pelvis due to a massive diuresis in a short-time that occurs following a long fasting with an obstructed ureter (due to ureteral stone) which finally ends to proximal ureteral

\* Corresponding author. Urology Research Center, Sina Hospital, Hassan Abad Sq., Imam Khomeini Ave., Tehran, Iran.  
 E-mail address: [mkaghmir@tums.ac.ir](mailto:mkaghmir@tums.ac.ir) (S.M. Kazem Aghamir).

<https://doi.org/10.1016/j.eucr.2021.101571>

Received 16 December 2020; Received in revised form 10 January 2021; Accepted 11 January 2021

Available online 15 January 2021

2214-4420/© 2021 Published by Elsevier Inc. This is an open access article under the CC BY-NC-ND license (<http://creativecommons.org/licenses/by-nc-nd/4.0/>).

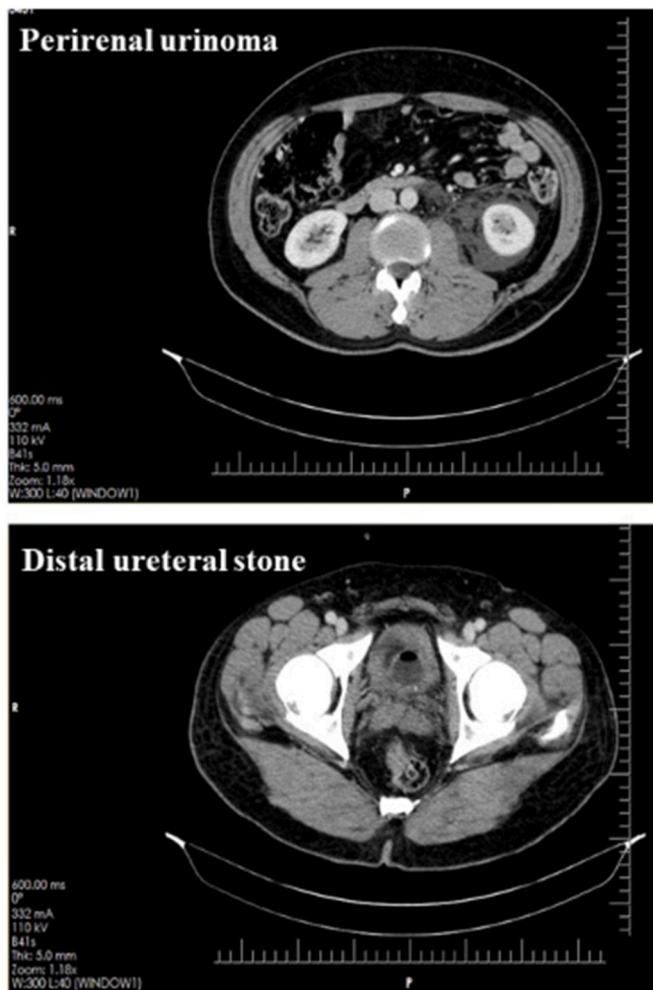


Fig. 1. Abdominopelvic CT scan.

rupture.

Perirenal space is the most frequent location of urinoma owing to higher incidence of renal injury in compare to ureteral injury. A urinary leakage can spread into different spaces. For instance, it can cross the midline if urinary leakage is massive or it can spread to mediastinum, pleural space, and soft tissues of pelvic through aortic hiatus, diaphragm, and iliopsoas compartment respectively.<sup>4</sup> Ureter urinoma can accumulate in different places, which are near the site of injury, retroperitoneal, and even in intraperitoneal cavity that occur as a result of disruption in fascial planes. In the present case, urinoma was located in perirenal space and the site of injury was in the proximal ureter just distal to ureteropelvic junction.

The applicability of CT scan in the diagnosis of urinoma is of proven value and CT scan is considered as the gold standard for urinoma diagnosis. The established CT protocol for diagnosis of urinoma is available, which is scanning both abdomen and pelvis before and after 100–150 mL contrast administration and the images of delayed phase of CT (the images that were taken 5–20 min following contrast injection) scan play a mandatory role in urine leakage diagnosis. Relative higher creatinine level and lower glucose level of urinoma than serum levels are the alternative method for the diagnosis of urinoma when radiology fails to diagnosis urinoma with one-hundred percent certainty.

Drainage would not be necessary in the majority of small urinoma and the chance of reabsorption of them is relatively high. Despite that, in certain cases, including large urinomas, not reabsorbed urinomas, and risk of infection or sepsis, drainage under guide of ultra-sonography or CT scan should be considered. A drainage catheter should be placed in

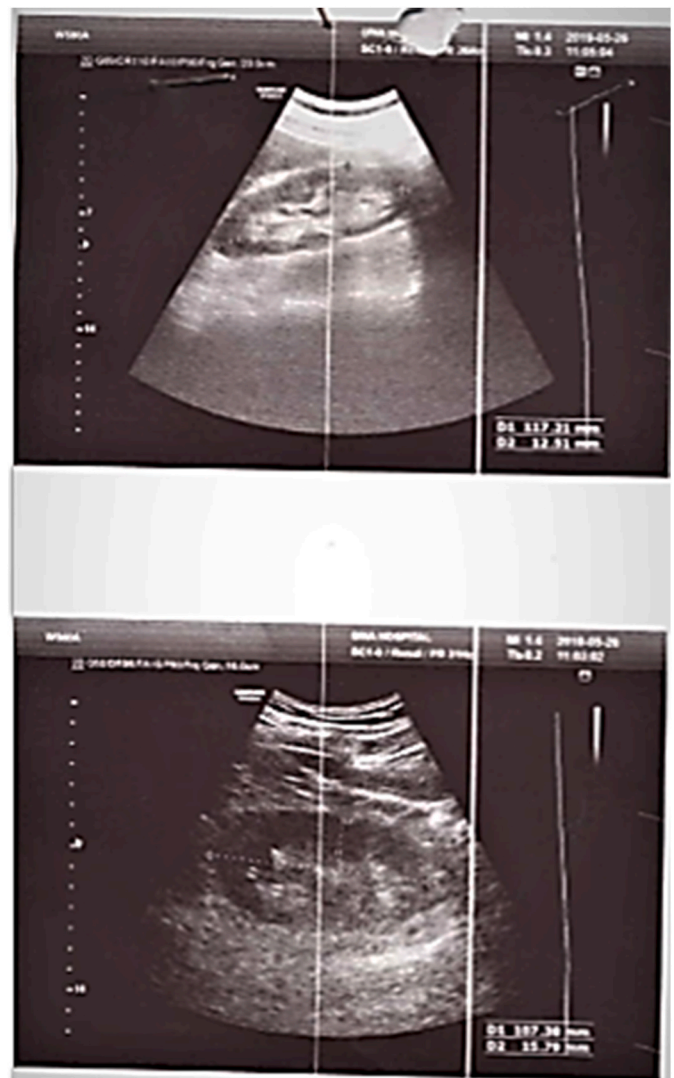


Fig. 2. Follow-up sonography.

favor of reducing intravesical pressure and help better drainage of the collecting system to stop urine leakage. Initiating empiric antibiotic therapy should be take into account to prevent urinoma infection.<sup>5</sup> In situations that urinary leakage continues, insertion a nephrostomy tube or a double j stenting is merit. In our case, the size of urinoma following ureteral stone removal and double-j stenting decreased (Fig. 2) and no more intervention then needed.

After 6 weeks, the imaging was repeated which showed no significant urinoma so the double j stent removed.

### Acknowledgments

Special thanks to Sina Hospital.

### References

1. Ito S-i, Ikeda M, Asanuma H, et al. A giant urinoma in a neonate without obstructive uropathy. *Pediatr Nephrol.* 2000;14(8-9):831–832.
2. Rizvi S, Ibne A, Siddiqui M, et al. A case report: urinoma as initial presenting sign of bladder malignancy. *Indian J Canc.* 2011;48(4):516.
3. Gayer G, Hertz M, Zissin R, et al. *Ureteral Injuries: CT Diagnosis. Seminars in Ultrasound, CT and MRI.* Elsevier; 2004.
4. Lang E. Management of urinomas by percutaneous drainage procedures. *Radiol Clin.* 1986;24(4):551–559.
5. Tilton RL, Gervais DA, Boland GW, et al. Renal trauma: radiologic evaluation and percutaneous treatment of nonvascular injuries. *Am J Roentgenol.* 2002;178(6):1507–1511.