



Guidelines in CHARGE syndrome and the missing link: Cranial imaging

Christa M. de Geus^{1,2}  | Rolien H. Free^{1,3} | Berit M. Verbist^{4,5} | Deborah A. Sival^{1,6} | Kim D. Blake^{7,8} | Linda C. Meiners^{1,9} | Conny M. A. van Ravenswaaij-Arts^{1,2} 

¹ University of Groningen, University Medical Center Groningen, Center of Expertise for CHARGE syndrome, Groningen, The Netherlands

² University of Groningen, University Medical Center Groningen, Department of Genetics, Groningen, The Netherlands

³ University of Groningen, University Medical Center Groningen, Department of ENT, Groningen, The Netherlands

⁴ Department of Radiology, Leiden University Medical Center, Leiden, The Netherlands

⁵ Department of Radiology, Radboud University Nijmegen Medical Center, Nijmegen, The Netherlands

⁶ University of Groningen, Beatrix Children's Hospital, University Medical Center Groningen, department of Pediatrics, Groningen, The Netherlands

⁷ IWK Health Centre, Halifax, Nova Scotia, Canada

⁸ Faculty of Medicine, Dalhousie University, Halifax, Nova Scotia, Canada

⁹ University of Groningen, University Medical Center Groningen, Department of Radiology, Groningen, The Netherlands

Correspondence

Conny M. A. van Ravenswaaij-Arts, Centre of Expertise for CHARGE syndrome, University of Groningen, University Medical Center Groningen, Groningen, The Netherlands.
Email: c.m.a.van.ravenswaaij@umcg.nl

“CHARGE syndrome” is a complex syndrome with high and extremely variable comorbidity. As a result, clinicians may struggle to provide accurate and comprehensive care, and this has led to the publication of several clinical surveillance guidelines and recommendations for CHARGE syndrome, based on both single case observations and cohort studies. Here we perform a structured literature review to examine all the existing advice. Our findings provide additional support for the validity of the recently published Trider checklist. We also identified a gap in literature when reviewing all guidelines and recommendations, and we propose a guideline for neuroradiological evaluation of patients with CHARGE syndrome. This is of importance, as patients with CHARGE are at risk for peri-anesthetic complications, making recurrent imaging procedures under anesthesia a particular risk in clinical practice. However, comprehensive cranial imaging is also of tremendous value for timely diagnosis, proper treatment of symptoms and for further research into CHARGE syndrome. We hope the guideline for neuroradiological evaluation will help clinicians provide efficient and comprehensive care for individuals with CHARGE syndrome.

KEYWORDS

CHARGE syndrome, CHD7, CT, guidelines, MRI

1 | INTRODUCTION

CHARGE syndrome is a relatively frequently occurring genetic syndrome with an estimated incidence of 1 in 15,000. It is a very complex syndrome with a broad phenotype that can involve almost all organ and sensory systems. As a result, comorbidity is high and extremely variable. There is

also a striking variability in severity, with both very mild cases and severe early lethal cases going undiagnosed. The clinical challenge of such a complex disorder is that some clinical problems may remain undiagnosed as other more severe or even life-threatening complications consume all medical attention. The diverse clinical aspects of CHARGE syndrome have been studied by several groups worldwide, resulting in extremely

This is an open access article under the terms of the Creative Commons Attribution-NonCommercial License, which permits use, distribution and reproduction in any medium, provided the original work is properly cited and is not used for commercial purposes.

© 2017 The Authors. *American Journal of Medical Genetics Part C* Published by Wiley Periodicals, Inc.

useful guidelines and recommendations. For this special issue of the American Journal of Medical Genetics (part C), we have examined these guidelines by performing a structured literature search and reviewing the existing advice, including that of hallmark papers by Blake et al. (1998) and the clinical checklist published recently by Trider (see Figure 1, (Trider, Arra-Robar, van Ravenswaaij-Arts, & Blake, 2017)).

To date, no guidelines for cranial imaging in CHARGE syndrome have been published, but we see two important reasons why there is a need for such a guideline. First, in our experience and that of others, cranial imaging in individuals with CHARGE syndrome is often performed incompletely or with insufficient resolution. As a result, some of the cranial malformations occurring in CHARGE syndrome

CHARGE SYNDROME CHECKLIST: HEALTH SUPERVISION ACROSS THE LIFESPAN (FROM HEAD TO TOE)

*Shaded boxes indicate key assessment points

		INFANCY (0-2 years)	CHILDHOOD (3-11 years)	ADOLESCENCE (12-17 years)	ADULTHOOD (18+ years)
GENETICS	Clinical diagnosis (Blake et al. or Verloes or Hale et al. criteria)				
	Genetic testing – Genetics consult (CHD7 analysis, array CGH)				
	Genetic counselling				
NEUROLOGY	CNS malformations/hypoplasia olfactory bulb/temporal bone (semi-circular canal) malformations – requires MRI/CT				
	Seizures – more common at older ages – consider EEG				
	Cranial nerve problems – monitor for absent sense of smell, facial nerve palsy, sensorineural hearing loss, vertigo, swallowing problems				
EYES, EARS, NOSE AND THROAT	Coloboma, risk of retinal detachment - Ophthalmology consult (dilated eye exam in infancy, vision assessments)				
	Corneal exposure – lubricating eye drops				
	Photophobia – tinted glasses, sunhat				
	Choanal atresia/cleft palate/tracheoesophageal fistula - ENT/Plastics consult				
	Audiometry and tympanometry, monitor for recurrent ear infections				
	Adaptive services for individuals with deafness/blindness				
	Cochlear implant assessment if applicable				
	Obstructive sleep apnea – monitor for tonsil/adenoid hypertrophy				
	Excessive secretions – consider Botox, medication				
	Dental issues – consider cleaning under anaesthetic				
CARDIOLOGY RESPIROLOGY	Cardiac malformations common – major/minor defects, vascular ring or arrhythmias possible (echocardiogram, chest x-ray, ECG) - Cardiology consult				
	Sinusitis, pneumonia, asthma - monitor				
	Anesthesia risk (difficult intubations/post-op airway obstruction/aspiration) – extensive pre-operative assessment, combine surgical procedures				
GASTROENTEROLOGY GENITOURINARY	Gastroesophageal reflux – Gastroenterology consult – consider motility agents with proton pump inhibitor				
	Poor suck/chew/swallow - feeding team assessment/intervention				
	Aspiration risk, tracheoesophageal fistula – swallowing studies				
	May need supplemental feeds – frequently requires gastrostomy tube or gastrojejunostomy tube				
	Constipation – consider Senna glycoside with polyethylene glycol				
	Renal anomalies – abdominal u/s +/- VCUG, blood pressure monitoring				
ENDOCRINOLOGY	Hypogonadotropic hypogonadism – LH, FSH by 3 months				
	Genital hypoplasia (if undescended testes - consider orchidoplexy)				
	Delayed puberty – Endocrinology consult - gonadotropin levels, HRT				
	Osteoporosis – DEXA scan				
	Poor growth – Endocrinology consult – GH stimulation test, GH therapy				
	Obesity - monitor				
IMMUNE SYSTEM	Note presence of thymus at open heart surgery				
	Routine immunizations/antibody titres to immunizations in adolescence				
	Recurrent infections – Immunology consult				
MSK	Scoliosis/kyphosis- monitor				
	Mobility (affected by ataxia, hypotonia) - evaluate				
PSYCHOLOGY DEVELOPMENTAL	Assess gross and fine motor skills – Occupational Therapy, Physiotherapy				
	Communication, language, writing abilities – Speech Language Therapy				
	Consider deaf-blind consultant				
	Prepare for transitions to school, situations, places, systems				
	Psychoeducational assessment, Individualized Education Plan				
	Sleep disturbances – consider melatonin				
	Behavior management – self-regulation, impulse control, anxiety, obsessions, compulsions, anger				
	Toileting skills - support				
	Life skills/adaptive behaviour/social skills/social play				
	Address sexuality				
	Family stress – offer supports and resources				
	Medical self-management – work on managing medications, understanding conditions, seeing healthcare provider independently				

FIGURE 1 The Trider checklist. Republished (with permission) from Trider C-L, Arra-Robar A, van Ravenswaaij-Arts C, Blake K. 2017. Developing a CHARGE syndrome checklist: Health supervision across the lifespan (from head to toe). *American Journal of Medical Genetics Part A*, 173A, 684–691. A PDF of the checklist is available for download from <https://www.chargesyndrome.org/wp-content/uploads/2016/03/CHARGE-Syndrome-Checklist.pdf>

TABLE 1 Recommendations for treatment or management of CHARGE syndrome collected from literature

Recommendation	References	Trider checklist
Genetics		
CHARGE is a clinical diagnosis	Bergman, Janssen, et al. (2011); Blake et al. (1998); Harris, Robert, Kallen (1997); Issekutz, Prasad, Smith, and Blake (2005); Verloes (2005)	Yes
CHD7 testing can confirm uncertain diagnosis in mildly affected patients	Bergman, Janssen, et al. (2011)	Yes
CHD7 testing may be performed according to flow diagram	Bergman, Janssen, et al. (2011)	Yes
A genome-wide array should be performed in patients with CHARGE syndrome but without a CHD7 mutation	Corsten-Janssen et al. (2013)	Yes
Clinical genetics consultation is indicated, including options for prenatal diagnosis	Bergman, Janssen, et al. (2011); Lalani, Hefner, Belmont, and Davenport (2012)	Yes
Patients diagnosed with hypogonadotropic hypogonadism and anosmia should be screened for clinical features consistent with CHARGE syndrome	Jongmans et al. (2009)	Out of scope ^a
Olfactory bulb hypoplasia and semicircular canal aplasia should be considered major signs for CHARGE syndrome	Asakura et al. (2008); Sanlaville et al. (2006)	Out of scope
If a parent has any features of CHARGE syndrome, molecular genetic testing is appropriate if a CHD7 pathogenic variant has been identified in the proband	Jongmans et al. (2008)	Out of scope
CHD7 analysis should be performed in patients with a 22q11.2 deletion phenotype without TBX1 haploinsufficiency	Corsten-Janssen et al. (2013)	Out of scope
CHD7 analysis should be performed in patients with Kallmann syndrome who have at least two additional CHARGE features or semicircular canal anomalies	Bergman et al. (2012); Costa-Barbosa et al. (2013); Jongmans et al. (2009); Marcos et al. (2014)	Out of scope
CHD7 should be included in massive parallel sequencing gene panels for diagnostics in syndromic heart defects	Corsten-Janssen et al. (2014)	Out of scope
CHD7 analysis should not be performed routinely in patients with only atrial septal defect or conotruncal heart defects	Corsten-Janssen et al. (2014)	Out of scope
CHD7 analysis should not be performed in septo-optic dysplasia without features of CHARGE	Gregory et al. (2013)	Out of scope
MLPA analysis is indicated if no causal CHD7 is mutation found (contrary to Bergman et al., 2008)	Wincent et al. (2008); Wincent, Schulze, and Schoumans (2009)	Out of scope
MLPA analysis not indicated if no CHD7 mutation found (contrary to Wincent et al., 2009 and 2008)	Bergman et al. (2008)	Out of scope
Neurology		
MR imaging of the brain should be performed (semicircular canals, olfactory structures, pituitary and the basiocciput)	Asakura et al. (2008); Fujita et al. (2009); Gregory et al. (2013)	Yes
Temporal bone CT scan should be performed (pathology of middle ear, inner ear, cranial nerves, semicircular canals, aberrant course of blood vessels or cranial nerves)	Asakura et al. (2008); Vesseur, Verbist, et al. (2016)	Yes
Anticonvulsants are indicated if overt epilepsy is seen	Bergman, Janssen, et al. (2011)	Yes
EEG is indicated when seizures are observed clinically	Bergman, Janssen, et al. (2011)	Yes
Assessment of cranial nerve function (physical examination and swallowing studies) is indicated	Bergman, Janssen, et al. (2011); Blake et al. (2008); Lalani et al. (2012);	Yes

(Continues)

TABLE 1 (Continued)

Recommendation	References	Trider checklist
Eyes, ears, nose, and throat	White, Giambra, Hopkin, Daines, and Rutter (2005)	
Assess patency of choanae (CT scan or nasal endoscopy), surgical correction	Bergman, Janssen, et al. (2011); Lalani et al. (2012)	Yes
Evaluate for cleft palate and tracheo-esophageal anomalies, surgical correction	Bergman, Janssen, et al. (2011); Issekutz et al. (2005); Stack and Wyse (1991)	Yes
In infants, brain stem auditory evoked response (BAER) is indicated to evaluate hearing as soon as the infant is medically stable	Bergman, Janssen, et al. (2011); Edwards, Kileny, and Van Riper (2002); Lalani et al. (2012)	Yes
In older children and adults, hearing evaluation as appropriate for age and developmental status is indicated	Lalani et al. (2012)	Yes
Hearing habilitation (e.g., hearing aids, bone-anchored hearing aid, cochlear implantation, sign language, auditory and communication training) should be started as soon as hearing loss is documented and, if possible, before the age of three	Blake and Brown (1993); Edwards et al. (2002); Thelin and Fussner (2005)	Yes
Grommet placement for chronic serous otitis	Bergman, Janssen, et al. (2011); Lalani et al. (2012)	Yes
Cochlear implantation is indicated after critical assessment	Arndt et al. (2010); Bauer et al. (2002); Lanson, Green, Lalwani, and Waltzman (2007); Song et al. (2011); Vesseur, Free, et al. (2016)	Yes
MR imaging to determine the location and course of the facial nerves is indicated before craniofacial surgery or cochlear implantation	Bauer et al. (2002); Butler, Henry, Leckenby, and Grobbelaar (2014); Lalani et al. (2012)	Out of scope
Presence of anosmia can predict hypogonadotropic hypogonadism, therefore smell should be tested	Bergman, Janssen, et al. (2011)	Yes
Advice concerning anosmia should be given	Bergman, Janssen, et al. (2011)	No, too detailed
Evaluate obstructive sleep apnea in case of sleep disturbances	Trider and Blake (2012)	Yes
At diagnosis: full ophthalmological examination including funduscopy is indicated	Bergman, Janssen, et al. (2011); Blake, Kirk, and Ur (1993); Lalani et al. (2012); Russell-Eggitt, Blake, Taylor, and Wyse (1990)	Yes
Regular ophthalmologic evaluations are appropriate to follow changes in acuity, risks for retinal detachment and/or cataract and corneal abrasions (facial palsy)	Bergman, Janssen, et al. (2011); Blake and Brown (1993); Lalani et al. (2012); Russell-Eggitt et al. (1990)	Yes
Tinted spectacles for photophobia (common in coloboma) can be helpful	Blake and Brown (1993)	Yes
For eyes with visual potential, cycloplegic refraction and spectacle correction may be necessary, since substantive refractive errors of micro-ophthalmic eyes have been observed	Bergman, Janssen, et al. (2011); Blake and Brown (1993); Lalani et al. (2012); Russell-Eggitt et al. (1990)	Yes
Parents, therapists and teachers need to take visual field defects into account	Blake and Brown (1993)	No
Retinal detachment, a potential complication of retinal coloboma, can cause total blindness; any change in vision should be treated as a medical emergency	Lalani et al. (2012)	Yes
Artificial tears may be necessary in case of facial palsy with incomplete closure of the eye	Bergman, Janssen, et al. (2011)	Yes
Frequent clinical and radiologic dental evaluations should be performed, if necessary under anesthesia	Lalani et al. (2012)	Yes

Cardiology and respirology

(Continues)

TABLE 1 (Continued)

Recommendation	References	Trider checklist
At diagnosis: cardiac evaluation for cardiovascular anomalies (ECG and echocardiogram) is indicated	Bergman, Janssen, et al. (2011); Lalani et al. (2012); Wyse, al-Mahdawi, Burn, and Blake (1993)	Yes
Evaluate for arch vessel anomaly in case of unexplained swallowing/respiratory problems	Corsten-Janssen, van Ravenswaaij-Arts, and Kapusta (2016)	Yes
Extensive pre-operative assessment is indicated	Bergman, Janssen, et al. (2011); Blake et al. (2009); Stack and Wyse (1991)	Yes
Longer surveillance after surgery is indicated	Bergman, Janssen, et al. (2011); Blake et al. (2009); Stack and Wyse (1991)	Yes
Surgical procedures on these patients should be combined whenever possible because of their increased risk of post-operative complications and intubation problems	Bergman et al. (2010); Bergman, Janssen, et al. (2011); Blake et al. (2009); Lalani et al. (2012)	Yes
Gastroenterology and genitourinary		
Genitourinary evaluation (including renal and bladder ultrasound, voiding cystourethrography screening) is indicated	Bergman, Janssen, et al. (2011); Blake et al. (1998); Lalani et al. (2012); Ragan, Casale, Rink, Cain, and Weaver (1999)	Yes
Early treatment of bladder infections (especially in case of unilateral renal agenesis or vesico-urethral reflux) is recommended	Bergman, Janssen, et al. (2011)	No, too detailed
Monitor cryptorchidism and perform orchidopexy if indicated	Bergman, Janssen, et al. (2011)	Yes
Perform swallowing studies, pH monitoring and reflux scan in case of feeding/swallowing difficulties	Bergman, Janssen, et al. (2011)	Yes
Perform gastrostomy/tracheotomy in case of severe swallowing problems	Asher, McGill, Kaplan, Friedman, and Healy (1990); Bergman, Janssen, et al. (2011)	Yes
Where indicated, tracheotomy needs to be performed early to avoid hypoxic events	Roger et al. (1999)	No, too detailed
Individualized evaluation of feeding behavior (incl. oral defensiveness) should be a part of the standard otolaryngologic and feeding team practice	Bergman et al. (2010); Dobbeltsteyn, Peacocke, Blake, Crist, and Rashid (2008); Hudson, Macdonald, and Blake (2016)	Yes
Endocrinology		
Early referral for endocrinology consultation is appropriate	Gregory et al. (2013); Pinto et al. (2005); Wheeler, Quigley, Sadeghi-Nejad, and Weaver (2000)	Yes
If growth is deviating from normal despite adequate nutrition and normalized cardiac status, evaluate for growth hormone deficiency	Asakura et al. (2008); Bergman, Janssen, et al. (2011); Blake et al. (1993); Lalani et al. (2012)	Yes
Start growth hormone treatment if growth hormone deficiency is present	Bergman, Janssen, et al. (2011); Lalani et al. (2012)	Yes
Routine testing of adrenal function is not indicated	Wong et al. (2016)	Negative result
Evaluation of hypogonadotropic hypogonadism is indicated (LH and FSH between age 2–3 months, or age 13–14 years if puberty has not occurred)	Bergman, Janssen, et al. (2011); Pinto et al. (2005); Wheeler et al. (2000)	Yes
Consider hormone replacement therapy in hypogonadotropic hypogonadism to induce puberty and for general health reasons including prevention of osteoporosis	Bergman, Janssen, et al. (2011); Forward, Cummings, and Blake (2007); Lalani et al. (2012); Sato et al. (2015)	Yes
All patients with congenital hypogonadotropic hypogonadism should be informed about the possibility of hypogonadotropic hypogonadism reversal before transition to adult healthcare	Laitinen et al. (2012)	No, too detailed
DEXA scan is indicated, if osteoporosis is suspected	Bergman, Janssen, et al. (2011)	Yes
Thyroid function should be tested if dysfunction is suspected	Asakura et al. (2008); Gregory et al. (2013)	Yes

(Continues)

TABLE 1 (Continued)

Recommendation	References	Trider checklist
Immune system		
Perform immunological evaluation (B- and T-cell numbers and vaccination responses) in patients with recurrent infections	Bergman, Janssen, et al. (2011); Chopra, Baretto, Duddridge, and Browning (2009); Wong et al. (2015); Writzil, Cale, Pierce, Wilson, and Hennekam (2007)	Yes
Consider booster vaccines in patients with low vaccine response	Wong et al. (2015)	Yes
Musculoskeletal		
Periodic evaluation for scoliosis in children, especially during growth hormone treatment, is indicated	Bergman, Janssen, et al. (2011); Doyle and Blake (2005)	Yes
Treat severe and/or progressive scoliosis with corset or surgery	Bergman, Janssen, et al. (2011)	Yes
Psychology and development		
Referral to deafblind education services should be made as early as possible	Blake and Brown (1993); Lalani et al. (2012)	Yes
Psychological/school evaluations should be performed by a team that includes specialists in deafblindness	Lalani et al. (2012)	No, too detailed
Perform IQ tests and/or developmental evaluations regularly	Bergman, Janssen, et al. (2011)	Yes
Extensive multidisciplinary evaluation of developmental and sensory impairments and behavioral problems is indicated	Bergman, Janssen, et al. (2011); Lalani et al. (2012)	Yes
Therapy for hypotonia and devices to overcome balance impairment are indicated	Bergman, Janssen, et al. (2011); Blake and Brown (1993)	Yes
Use formal tests to screen for autism spectrum, obsessive compulsive disorders and ADHD	Bergman, Janssen, et al. (2011)	Yes
Executive dysfunction is common. Interventions targeting improved self-regulation may help to manage behavior	Hartshorne, Nicholas, Grialou, and Russ (2007)	No, too detailed
General		
Follow-up should be by a multidisciplinary team	Bergman, Janssen, et al. (2011); Blake, Russell-Eggitt, Morgan, Ratcliffe, and Wyse (1990)	Yes
Autopsy should be performed in deceased patients to gain more insight into causes of death	Bergman et al. (2010)	Out of scope

Recommendations were collected from the literature as described in the text and categorized according to organ system.

MLPA, multiplex ligation-dependent probe amplification; TBX1, T-box 1 gene.

^aOut of scope means out of the scope of the Trider checklist.

were noted first in animal models (e.g., cerebellar abnormalities (Yu et al., 2013)) or were found only after structured evaluation of images of a series of individuals (Hoch et al., 2017). Second, as individuals with CHARGE syndrome are at increased risk of post-operative airway complications, procedures under anesthesia should be combined as much as possible (Blake et al., 2009). The need to improve imaging while reducing risks therefore warrants guidelines for performing neuro-imaging in an optimal and efficient way. Altogether, we argue that standardized recommendations for neuro-imaging protocols could contribute to clinical awareness of the heterogeneous cranial abnormalities involved in CHARGE syndrome and improve care.

2 | OVERVIEW OF GUIDELINES AND RECOMMENDATIONS FROM LITERATURE

A literature search using PubMed was performed on August 17, 2017 using the search string: ("CHARGE syndrome" OR "CHARGE association"

OR CHD7) AND (guideline* OR consensus OR recommend* OR "best practice" OR "surveillance"). This resulted in 112 hits, of which 42 contained usable guidelines or recommendations. A further 15 articles with guidelines or recommendations were found through an examination of the references. The resulting full list with recommendations is given in Supplemental Table S1. We then categorized the guidelines and recommendations from the literature either by organ system or as "general" (see Table 1), then checked if they were included in the Trider checklist (see Figure 1 and Table 1).

Out of 73 formulated recommendations, 53 were covered by the Trider checklist or the accompanying paper. Of the other 20, only one is truly "missing" from the checklist: 12 were out of the scope of a clinical surveillance checklist, six were too detailed to be included, and one was a recommendation to *not* perform a test (adrenal evaluation). The missing recommendation concerns the advice to parents, therapists and teachers to take into account visual field defects. A last recommendation was actually given in the Trider paper but not included in their checklist. Trider advises screening patients with

TABLE 2 Recommendations from literature regarding *CHD7* analysis

Recommendation	Basis for recommendation	References
The indication for <i>CHD7</i> analysis can be determined through the flow diagram provided by Bergman et al.	Validated on cohort of 280 patients	Bergman, Janssen, et al. (2011)
<i>CHD7</i> testing can confirm uncertain diagnosis in mildly affected patients	Validated on cohorts of 280 and 28 patients	Bergman, Janssen, et al. (2011); Hale, Niederriter, Green, and Martin (2016)
If a parent has any features of CHARGE syndrome, molecular genetic testing is appropriate if a <i>CHD7</i> pathogenic variant has been identified in the proband	Case series of five families	Jongmans et al. (2008)
A genome-wide array should be performed in patients with CHARGE syndrome but without a <i>CHD7</i> mutation	Expert opinion	Corsten-Janssen et al. (2013)
There is a very low yield of MLPA analysis in patients with CHARGE syndrome but without causal <i>CHD7</i> mutations	Cohort of 54 patients: 1 deletion of multiple exons; several case reports	Bergman et al. (2008); Wincent et al. (2008); Wincent et al. (2009)
<i>CHD7</i> analysis should be performed in patients with a 22q11.2 deletion phenotype without <i>TBX1</i> haploinsufficiency	5 <i>CHD7</i> mutations in 20 patients	Corsten-Janssen et al. (2013)
<i>CHD7</i> analysis should be performed in patients with Kallmann syndrome who have at least two additional CHARGE features or semicircular canal anomalies	Yield of 6% in (2 studies combined) 96 patients with Kallmann syndrome/normosmic idiopathic hypogonadotropic hypogonadism; hearing loss enriched in probands with Kallmann syndrome and <i>CHD7</i> mutation vs. without <i>CHD7</i> mutation	Bergman et al. (2012); Costa-Barbosa et al. (2013); Jongmans et al. (2009)
<i>CHD7</i> should be included in massive parallel sequencing gene panels for diagnostics in patients with syndromic heart defects	Expert opinion	Corsten-Janssen et al. (2014)
<i>CHD7</i> analysis should not be performed routinely in patients with isolated atrial septal or conotruncal heart defects	Cohort of 46 patients, no <i>CHD7</i> mutations	Corsten-Janssen et al. (2014)
<i>CHD7</i> analysis should not be performed in patients with septo-optic dysplasia or hypopituitarism without features of CHARGE syndrome	Cohort of 100 patients, no <i>CHD7</i> mutations	Gregory et al. (2013)

MLPA, multiplex ligation-dependent probe amplification; *TBX1*, T-box 1 gene.

TABLE 3 Cranial abnormalities in CHARGE syndrome

Structure	Abnormality	Clinical relevance	Imaging modality ^a	References
Skull base	<ul style="list-style-type: none"> • Basioccipital hypoplasia, small clivus, dorsally angulated clivus • Hypoplasia sella, J-shaped sella 	Diagnostic aid	Sagittal T1 sagittal T2 in neonates	Fujita et al. (2009); Hoch et al. (2017)
Cranial nerves				
I	Hypoplasia/aplasia	Sense of smell, prediction of HH, diagnostic aid	Coronal T2-TSE anterior skull base, 3D CISS, MPRAGE	Bergman, Bocca, et al. (2011)
II	Coloboma	Vision, diagnostic aid	Transverse T2 and coronal T1 and STIR through to orbits	McMain et al. (2008)
VII	Hypoplasia/aplasia and/or aberrant course	Planning of CI operation	Transverse 3D CISS, temporal bone CT	Vesseur, Verbist, et al. (2016)
VIII	Hypoplasia/aplasia	Decisions around BAHA, CI or ABI operation; planning of CI operation	Transverse 3D CISS, oblique MPRs of internal auditory canal	Vesseur, Verbist, et al. (2016)
IX	Hypoplasia/aplasia	Swallowing	Transverse 3D CISS	Blake et al. (2008)
XII	Hypoplasia/aplasia	Swallowing, speech	Transverse 3D CISS	Blake et al. (2008)
Ear				
Cochlea	Various types of malformations, stenotic cochlear aperture	Hearing, planning of CI operation	Temporal bone CT, 3D CISS	Vesseur, Verbist, et al. (2016)
Middle ear	<ul style="list-style-type: none"> • Dysplasia stapes and/or incus, absent or stenotic oval and round windows • Vascular anomalies of petrosus (persistent petrosquamous sinus (PSS), enlarged emissary vein, e.o.) • Underdevelopment middle ear cavity and underpneumatization of the mastoid 	Aid in diagnosis conductive or mixed hearing loss, planning CI or ear surgery	Temporal bone CT	Vesseur, Verbist, et al. (2016)
Semicircular canals	Aplasia/dysplasia. Typically: malformed utriculus, aplastic posterior, anterior and lateral semicircular canals	Diagnostic aid, sense of balance	Temporal bone CT, 3D CISS	Vesseur, Verbist, et al. (2016)
Brain				
Cerebellum	Vermis hypoplasia	Unknown	Transverse and sagittal T2-TSE, MPRAGE	Hoch et al. (2017); Yu et al. (2013)
Ventricles	Ventriculomegaly, cavum septum pellucidum	No specific	Transverse T2, FLAIR, T1	Hoch et al. (2017)
Brainstem	Hypoplasia	No specific	Transverse T2	Hoch et al. (2017)
Frontal lobe	Hypoplasia	Unknown	Transverse and coronal T2	Gregory et al. (2013)
Pituitary	Ectopic posterior pituitary, anterior pituitary hypoplasia	Pituitary function	Sagittal and coronal T1 and T2	Gregory et al. (2013)

(Continues)

TABLE 3 (Continued)

Structure	Abnormality	Clinical relevance	Imaging modality ^a	References
Olfactory groove and gyrus	Hypoplasia/aplasia	Pituitary function, sense of smell	Coronal T2-TSE anterior skull base, 3D CISS	Hoch et al. (2017)
Lip/palate	Cleft lip/palate	Planning of operation	Thin slice CT with MPRs, MPRAGE with coronal and sagittal reconstruction	Hoch et al. (2017)
Choanae	Choanal atresia	Planning of operation	Paranasal sinus CT; Thin slice CT with MPRs, 3D MPRAGE with coronal and sagittal reconstruction	Hoch et al. (2017)

List of MRI findings observed in CHARGE syndrome. This list is not exhaustive; rarer features include hydrocephalus and corpus callosum abnormalities. Additionally, secondary abnormalities due to (perinatal) asphyxia are fairly common. Note: it is usually not possible to conclusively diagnose aplasia of cranial nerves on cranial imaging, as very hypoplastic nerves may be missed.

3D CISS, constructive interference in steady state—a fast thin slice heavily T2 weighted sequence, also known as Fiesta, 3D T2TSE; FLAIR, fluid attenuated inversion recovery; MPRAGE, multi-planar reconstruction acquired gradient echo—an ultrafast gradient echo, also known as 3DTFE; STIR, short-T1 inversion recovery; MPR: multiplanar reconstruction.

^aSiemens terminology is used in the table.

CHARGE for cochlear implant surgery before the age of three, however the cochlear implant box in their checklist is not shaded for the “infancy” column. Our review indicates the Trider surveillance checklist is well-supported by literature with only minor omissions. Recommendations regarding analysis for *CHD7*, the causative gene for CHARGE syndrome, are beyond the scope of the clinical checklist aimed at follow-up, but we have included a summary of these guidelines in Table 2.

As we discussed in the introduction, there are currently no formal guidelines for cranial imaging even though we argue that cranial imaging is an important clinical tool that needs to be handled carefully. The guidelines we present here for cranial imaging in patients with CHARGE syndrome are based on previously published neuro-radiologic recommendations (Asakura et al., 2008; Bergman, Janssen, et al., 2011; Fujita et al., 2009; Gregory et al., 2013; Pinto et al., 2005; Vesseur, Free, et al., 2016) in addition to current insights in detectable neuro-radiologic abnormalities and anatomic variants in patients with CHARGE syndrome (see Table 3).

3 | DIAGNOSTIC VALUE OF CRANIAL IMAGING

Imaging of the semicircular canals is recommended in patients with an atypical presentation of the syndrome to decide whether *CHD7* testing is warranted, or to confirm the clinical diagnosis when *CHD7* testing reveals no or an unclassified variant (Bergman, Janssen, et al., 2011). This is because aplasia or hypoplasia of the semicircular canals is present in 95% of individuals with a pathogenic variant in the *CHD7* gene, making it one of its most prevalent clinical features (Abadie et al., 2000; Bauer, Goldin, & Lusk, 2002; Lemmerling et al., 1998; Morimoto et al., 2006; Tellier et al., 1998; Wiener-Vacher, Amanou, Denise, Narcy, & Manach, 1999). The configuration of the labyrinth in CHARGE syndrome is typical: a malformed vestibule and aplastic or hypoplastic semicircular canals that is sometimes combined with cochlear malformation. These abnormalities can already be seen in fetal imaging (Tilea et al., 2006) and can, on their own, provide a valuable first clue toward diagnosis.

Rhinencephaly is another common feature in CHARGE syndrome (Legendre et al., 2012; Sanlaville et al., 2006) that can be observed in imaging. The olfactory nerves may be hypo- or aplastic, usually in combination with olfactory sulcus effacement. Other cranial nerves, particularly the facial and acoustic nerve, may also be hypo- or aplastic.

Hoch et al. (2017) recently published findings from MRI of the head and neck for 10 individuals with CHARGE syndrome and noted that skull base abnormalities (9/10) were often present in addition to semicircular canal abnormalities (10/10) and hypoplasia of the olfactory system (10/10). These skull base anomalies consisted of a J-shaped sella and a dorsal angulation of the clivus. These findings confirm the findings of Fujita et al. (2009) and are consistent with the preliminary results of a study in which we analyzed the clivus of 23 confirmed patients with CHARGE on MRI or CT scans. We found that the vast majority had an abnormal clivus (Figure 2) [yet unpublished

data]. These observations thus suggest that clivus abnormalities may be used as an important additional diagnostic tool.

Lastly, orbital abnormalities such as microphthalmia and colobomata, and nasal abnormalities such as choanal atresia may also be seen on cranial MRI.

As summarized in Table 3, there are multiple features observable on cranial MRI or CT that can aid in clinical diagnosis of CHARGE syndrome. These include semicircular canal hypoplasia, hypo- or aplasia of the olfactory nerve and sulcus, other cranial nerve hypo- or aplasias, clivus abnormalities, colobomata, and choanal atresia.

4 | VALUE OF CRANIAL IMAGING IN TREATMENT AND MANAGEMENT

4.1 | Hearing loss

Sixty to eighty percent of patients with CHARGE syndrome have moderate to severe hearing loss, either conductive, sensorineural, or mixed (Blake, Hartshorne, Lawand, Dailor, & Thelin, 2008). Auditory testing combined with the findings on CT and MRI are necessary for (i) diagnosing the type of hearing loss; (ii) choosing the optimal kind of rehabilitation; and (iii) planning a (possible) cochlear implantation (CI) or auditory brain stem implantation (ABI). CT and MRI provide complementary information in this situation: the bony anatomy is best studied on CT, while MRI provides additional information about the inner ear and allows visualization of the vestibulocochlear nerve.

Middle ear pathology, such as dysplastic ossicles or an absent/stenotic oval or round window, is seen on mastoid CT in over 70% of patients (Vesseur, Verbist, et al., 2016). In some of these children a bone-anchored hearing aid (BAHA, sometimes known as BCD—bone conductive device) may be a good hearing solution. A BAHA allows the perception of sound by by-passing the middle ear, provided the cochlea and auditory nerve are intact (Reinfeldt, Hakansson, Taghavi, & Eeg-Olofsson, 2015). Cochlear nerve hypoplasia or aplasia is seen relatively frequently in CHARGE (Holcomb, Rumboldt, & White, 2013), which reduces the possibilities for CI. In these cases, auditory brain

stem implantation may be an option, although hearing results appear to be less successful while the surgery is more extensive than for CI (Colletti, Colletti, Mandala, & Colletti, 2014).

CT imaging also provides additional information about surgical landmarks for cochlear implantation, such as detailed information about the lateral semicircular canals, which serves as a landmark for mastoidectomy. Alternatively, an aberrant course of the facial nerve increases the risk of perioperative injury and may impede cochleostomy (Vesseur, Free, et al., 2016). Vascular abnormalities may also hamper the surgical procedure. Vesseur, Free, et al. (2016) recently published a guideline on CI implantation in CHARGE that extensively covers preoperative imaging.

4.2 | Olfactory bulbs and puberty induction

Fetal studies found arhinencephaly in 36 of 40 (90%) fetuses with a confirmed pathogenic *CHD7* variant (Legendre et al., 2012). This is seen less often postnatally, although anosmia is diagnosed in approximately 80% of individuals with CHARGE syndrome (Bergman, Bocca, et al., 2011). Bergman, Bocca, et al. (2011) showed that olfaction and spontaneous onset of puberty are correlated in CHARGE syndrome: all (11/11) patients with hypogonadotropic hypogonadism (HH) were unable to smell, whereas patients without HH had the ability to smell (4/4). This combination of symptoms is also seen in Kallmann syndrome and is explained by common factors that facilitate axon guidance for both olfactory and GnRH neurons (Yanicostas, Herbomel, Dipietromaria, & Soussi-Yanicostas, 2009). The correlation of anosmia and HH enables prediction of HH in patients with CHARGE experiencing anosmia, which is useful because after the age of 3 months endocrinological assessment of HH is impossible until the onset of puberty. Therefore, in children for whom no endocrinological evaluation was performed before the age of 3 months, anosmia can help predict whether it will be necessary to induce puberty. As the formal evaluation of sense of smell is fairly involved and only possible from a (developmental) age of 5 years, and an impaired sense of smell can have many causes, radiological evidence of olfactory nerve/bulb aplasia or hypoplasia can aid in

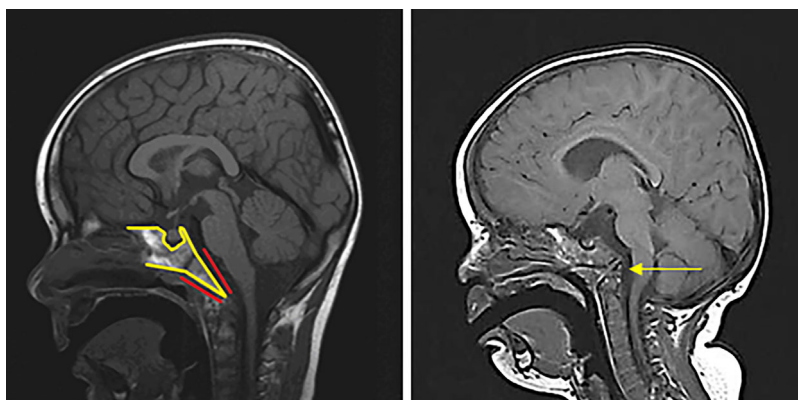


FIGURE 2 Clivus abnormalities in CHARGE syndrome. Normal anatomy (left) and typical CHARGE clivus in a 22-month-old boy (right). The clivus and sphenobasion have been outlined in yellow with the clivus indicated with red lines

CT AND MR SCANNING IN CHARGE SYNDROME	
Objective	Uniformity in MRI and CT scanning in CHARGE syndrome Awareness of difficult airway in patients with CHARGE syndrome
Background	
CHARGE syndrome is a rare congenital anomaly syndrome with a highly variable clinical spectrum. Common symptoms are coloboma of the eye (C), congenital heart defects (H), choanal atresia (A), retardation of growth or development (R), genital hypoplasia (G) and ear abnormalities (E). Additionally, cleft lip/palate, cranial nerve hypo- or aplasia and vestibular dysplasia are common. Individuals with CHARGE syndrome have a significantly increased risk of post-anesthesia airway complications due to a combination of factors, such as cranial nerve dysfunction and abnormal anatomy of the upper airways. The wide spectrum of symptoms in CHARGE syndrome requires imaging for several different indications. For many children, CT and MR imaging will have to be performed under anesthesia. To reduce the risk of anesthesia and minimize exposure to radiation, we recommend: <ul style="list-style-type: none"> • performing comprehensive CT and MRI scanning in one session • comprehensive pre-anesthesia screening, including cardiac screening, by a pediatric anesthesiologist 	
Scans to be performed	
Indicated in all CHARGE patients: <ul style="list-style-type: none"> • CT temporal bone/mastoid • MRI brain On indication: CT thorax (larynx, trachea, bronchial tree), cervical MRI, preoperative navigational CT of choanae	
Typical abnormalities in cranial imaging in CHARGE syndrome	
<ul style="list-style-type: none"> • Cranial nerves: hypoplasia or aplasia of cranial nerves, aberrant course of the facial nerve, colobomata • Cochlea: various types of malformations • Middle ear: dysplasia of the stapes/incus, absent or stenotic oval and round windows, persistent petrosquamous sinus, aberrant emissary vein, underpneumatization of the mastoid • Semicircular canals and utriculus/vestibulum: aplasia or dysplasia • Brain: cerebellar vermis hypoplasia, ventriculomegaly, frontal lobe hypoplasia, ectopic posterior pituitary, anterior pituitary hypoplasia, hypo- or aplasia of the olfactory nerve/bulb and effacement of olfactory groove • Skull base: basioccipital hypoplasia, clivus hypoplasia, hypoplasia/J-shaped sella 	
Advised scanning techniques and sequences	
<p><i>CT temporal bone</i></p> <p>Patient in supine position; minimize radiation dose to the lens (e.g. scan parallel to the inferior orbitomeatal line) Scan range should include tegmen tympani up to the mastoid tip Axial acquired volume of the temporal bone. Perform volume scan acquisition if the target can be covered in one single rotation. Otherwise, perform a helical acquisition in 4-slice mode with 0.5-0.625mm as slice thickness (i.e. 4x0.5 mm or 4x0.625 mm collimation) Zoomed in reconstructions (field of view=90mm, slice thickness 0.5-0.625mm and same or halved image spacing) of each ear magnified separately, selecting an ultrahigh resolution reconstruction algorithm specific for bone:</p> <ul style="list-style-type: none"> • axial plane: parallel to horizontal semicircular canal • coronal plane: perpendicular to axial MPR <p><i>MRI brain</i></p> <p>The MR imaging should ideally be performed on a 1.5 or 3 Tesla MRI</p> <ul style="list-style-type: none"> • Brain, including cerebellum: axial T2-TSE, 2D or 3D FLAIR, IR, SWI, DWI, and a sagittal MPRAGE through the entire brain and skull base. Sagittal T2 for additional imaging of cerebellar and clival pathology • Orbits and choanal area: axial T2 images and coronal STIR and T1 • Clivus: sagittal T1. In neonates, with less contrast between marrow and bone, T2 may be useful • Olfactory nerves: coronal T2-FSE from the frontal basis to the brain stem, to include the olfactory nerves and sulci. MPRAGE/3D T1/SPACE from the frontal basis, to the brain stem through to the level of the hypoglossal nerve, to include the olfactory nerves • Other cranial nerves and labyrinth: T2 CISS 3D from the level of the olfactory nerves through to the foramen magnum with sagittal and coronal reconstructed slices • Pituitary gland: small field of view sagittal and coronal T1 and T2 <p>If the child is restless acquisitions with radial k-space filling (e.g. BLADE, PROPELLOR, MultiVane) may be used in order to minimize artifacts, while retaining the contrast and spatial resolution</p>	

Acronyms and synonyms: CISS - Constructive Interference in the Steady State. Synonym: FIESTA-C; DWI - diffusion weighted images; FLAIR - fluid-attenuated Inversion recovery; IR - Inversion recovery; MPRAGE - Magnetization Prepared Rapid Gradient Echo. Synonyms: 3D T1-TFE; 3D BRAVO; PROPELLOR - Periodically Rotated Overlapping Parallel Lines with Enhanced Reconstruction. Synonym: MultiVane; STIR - short T1 inversion recovery; SWI - susceptibility weighted images; TSE - turbo spin echo. Synonym: FSE

Centre of Expertise for CHARGE syndrome, University Medical Center Groningen, the Netherlands

FIGURE 3 Guideline for CT and MR imaging in CHARGE syndrome

predicting patients at risk for HH. However, because olfactory imaging is not a perfect predictor of sense of smell, olfactory imaging alone is insufficient to determine HH status.

4.3 | Other brain abnormalities

MR imaging has revealed a variety of other brain abnormalities in CHARGE syndrome (Hoch et al., 2017). In specific cases, the presence of

brain abnormalities on MRI can explain a particular clinical feature in a patient. For instance, post-asphyxia damage may explain an otherwise unexpected severe developmental delay in a child with overall mild symptoms. However, predicting clinical symptoms from MRI abnormalities is more difficult. For instance, even though cerebellar dys- or hypoplasia is fairly common in CHARGE syndrome (Yu et al., 2013), no relationship to ataxia has been reported so far (Sohn et al., 2016). Research on the clinical relevance of cerebellar anomalies is ongoing.

5 | RESEARCH AND CRANIAL IMAGING

Since the identification of *CHD7* as the causal gene for CHARGE syndrome, several animal models have been developed, with mouse models being the most-studied. This has led to the identification in mice of significant anatomical features that were not known or were only anecdotally described in individuals with CHARGE syndrome. The best example for this is the hypoplasia of the cerebellar vermis. Abnormalities of the cerebellum were sporadically mentioned in papers on CHARGE syndrome, but it was only after the identification in mice of a role for *Chd7* in the isthmic organizer that a systemic study of human MRI scans revealed cerebellar abnormalities in at least half of individuals with CHARGE syndrome (Haldipur & Millen, 2013; Yu et al., 2013).

Jiang et al. (2012) described telencephalic midline abnormalities in a mouse model with a nonsense *Chd7* mutation. These mice had arhinencephaly, dilated third and lateral ventricles, reduced cerebral cortex, and corpus callosum crossing failure. As described above, arhinencephaly is a well-known CHARGE feature, but it was not until recently that ventriculomegaly and corpus callosum abnormalities were described in patients with CHARGE (Hoch et al., 2017; Jiang et al., 2012).

Sperry et al. (2014) found several phenotypic features that are well-known in humans with CHARGE syndrome in *Foxg1* and *Wnt1* conditional knockout mice, but they also observed skull bone abnormalities such as frontal, parietal and occipital bone dysplasia and hypoplasia of the maxilla (Sperry et al., 2014). The same abnormalities were not seen in heterozygous *Chd7* mice and have not been described in humans, but as described above, clivus and petrosal abnormalities are common in individuals with CHARGE syndrome.

Inner and middle ear abnormalities (os petrosum) have been studied extensively in humans and mice because of their effect on hearing. Therefore, most anatomic anomalies seen in *Chd7*-deficient mice had already been extensively documented in individuals with CHARGE syndrome. One lesser-known feature, however, is the otosclerosis-like fusion of the stapes footplate to the cochlear oval window as described by Ogier et al. (2014) in *Looper* mice. A recent study of CT images of the os petrosum of individuals with CHARGE syndrome showed that, in addition to the (known) abnormalities of the oval window, the stapes was dysplastic or not identifiable in half of the ears with a stenotic oval window (Vesseur, Verbist, et al., 2016).

It is obvious that researchers studying animal models are interested in translating their findings to humans. Performing MRI or CT scans in children with CHARGE syndrome solely for the sake of research is ethically difficult to accept, especially since most children will have to be sedated with a risk of post-sedation respiratory problems. However, when there is a clinical indication to perform imaging studies, performing imaging as complete and as detailed as possible aides both individuals with CHARGE syndrome through better and more complete diagnosis and researchers through a better and more complete picture of the features of CHARGE syndrome.

6 | GUIDELINE FOR CRANIAL IMAGING

In our experience, in each individual with CHARGE, a wide variety of scans are usually performed by different medical specialists. This leads to scans that differ in completeness and sequences used. A further complication is that scans are often performed in different hospitals and parents may find it difficult to recall if and where imaging was done, illustrating that the early years of children with CHARGE syndrome are often hectic and overwhelming.

Individuals with CHARGE syndrome often undergo a great many procedures under anesthesia (Blake et al., 2009). To reduce the risk of recurrent anesthesia and minimize exposure to radiation, neuro-imaging should preferentially be completed within one efficient session. With that objective in mind, a radiology guideline, combining CT and MRI scanning and outlining the correct sequences, may enable accurate diagnostic radiologic assessment of the cranial and auditory anatomy within one session. This guideline is presented in Figure 3. In children up to 6 months of age, the unnecessary risk of anesthesia may be avoided by swaddling (CT duration 0.5–2 min, MRI duration approximately 30 min). In our opinion, avoidance of unnecessary anesthesia is more important than the small chance of movement artifacts in the MRI of a swaddled infant.

7 | CONCLUSION

CHARGE syndrome is a complex entity with a wide range of congenital abnormalities and clinical symptoms. The multitude of issues that individuals with CHARGE syndrome face, particularly early in life, greatly increases the risk that their care will be fragmented or incomplete. Our review confirms that the Trider checklist provides a well-supported framework for clinical surveillance. Our guideline for cranial imaging provides an aid to clinicians for providing accurate and optimal care while limiting risky anesthetic procedures, and may enable more effective research into cranial abnormalities in CHARGE syndrome.

ACKNOWLEDGMENTS

We thank Jackie Senior and Kate McIntyre for editing the manuscript.

CONFLICTS OF INTEREST

The authors declare no conflicts of interest.

ORCID

Christa M. de Geus  <http://orcid.org/0000-0002-7996-056X>

Conny M. A. van Ravenswaaij-Arts  <http://orcid.org/0000-0002-8744-1305>


REFERENCES

Abadie, V., Wiener-Vacher, S., Morisseau-Durand, M. P., Poree, C., Amiel, J., Amanou, L., ... Manac'h, Y. (2000). Vestibular anomalies in CHARGE

- syndrome: Investigations on and consequences for postural development. *European Journal of Pediatrics*, 159, 569–574.
- Arndt, S., Laszig, R., Beck, R., Schild, C., Maier, W., Birkenhager, R., . . . Aschendorff, A. (2010). Spectrum of hearing disorders and their management in children with CHARGE syndrome. *Otology and Neurotology*, 31, 67–73.
- Asakura, Y., Toyota, Y., Muroya, K., Kurosawa, K., Fujita, K., Aida, N., . . . Adachi, M. (2008). Endocrine and radiological studies in patients with molecularly confirmed CHARGE syndrome. *The Journal of Clinical Endocrinology and Metabolism*, 93, 920–924.
- Asher, B. F., McGill, T. J., Kaplan, L., Friedman, E. M., & Healy, G. B. (1990). Airway complications in CHARGE association. *Archives of Otolaryngology-Head and Neck Surgery*, 116, 594–595.
- Bauer, P. W., Wippold, F. J., 2nd, Goldin, J., & Lusk, R. P. (2002). Cochlear implantation in children with CHARGE association. *Archives of Otolaryngology-Head and Neck Surgery*, 128, 1013–1017.
- Bergman, J. E., Blake, K. D., Bakker, M. K., du Marchie Sarvaas, G. J., Free, R. H., & Ravenswaaij-Arts, C. M. (2010). Death in CHARGE syndrome after the neonatal period. *Clinical Genetics*, 77, 232–240.
- Bergman, J. E., Bocca, G., Hoefsloot, L. H., Meiners, L. C., & Ravenswaaij-Arts, C. M. (2011a). Anosmia predicts hypogonadotropic hypogonadism in CHARGE syndrome. *Journal of Pediatrics*, 158, 474–479.
- Bergman, J. E., de Ronde, W., Jongmans, M. C., Wolffenbuttel, B. H., Drop, S. L., Hermus, A., . . . van Ravenswaaij-Arts, C. M. (2012). The results of CHD7 analysis in clinically well-characterized patients with kallmann syndrome. *The Journal of Clinical Endocrinology and Metabolism*, 97, E858–E862.
- Bergman, J. E., de Wijs, I., Jongmans, M. C., Admiraal, R. J., Hoefsloot, L. H., & Ravenswaaij-Arts, C. M. (2008). Exon copy number alterations of the CHD7 gene are not a major cause of CHARGE and CHARGE-like syndrome. *European Journal of Medical Genetics*, 51, 417–425.
- Bergman, J. E., Janssen, N., Hoefsloot, L. H., Jongmans, M. C., Hofstra, R. M., & van Ravenswaaij-Arts, C. M. (2011b). CHD7 mutations and CHARGE syndrome: The clinical implications of an expanding phenotype. *Journal of Medical Genetics*, 48, 334–342.
- Blake, K., Kirk, J. M., & Ur, E. (1993). Growth in CHARGE association. *Archives of Disease in Childhood*, 68, 508–509.
- Blake, K., Maccuspie, J., Hartshorne, T. S., Roy, M., Davenport, S. L., & Corsten, G. (2009). Postoperative airway events of individuals with CHARGE syndrome. *International Journal of Pediatric Otorhinolaryngology*, 73, 219–226.
- Blake, K. D., & Brown, D. (1993). CHARGE association looking at the future—the voice of a family support group. *Child Care, Health and Development*, 19, 395–409.
- Blake, K. D., Davenport, S. L., Hall, B. D., Hefner, M. A., Pagon, R. A., Williams, M. S., . . . Graham, J. M., Jr. (1998). CHARGE association: An update and review for the primary pediatrician. *Clinical Pediatrics*, 37, 159–173.
- Blake, K. D., Hartshorne, T. S., Lawand, C., Dailor, A. N., & Thelin, J. W. (2008). Cranial nerve manifestations in CHARGE syndrome. *American Journal of Medical Genetics Part A*, 146, 585–592.
- Blake, K. D., Russell-Eggitt, I. M., Morgan, D. W., Ratcliffe, J. M., & Wyse, R. K. (1990). Who's in CHARGE? multidisciplinary management of patients with CHARGE association. *Archives of Disease in Childhood*, 65, 217–223.
- Butler, D. P., Henry, F. P., Leckenby, J. I., & Grobbelaar, A. O. (2014). The incidence of facial vessel agenesis in patients with syndromic congenital facial palsy. *Plastic and Reconstructive Surgery*, 134, 955e–958e.
- Chopra, C., Baretto, R., Duddridge, M., & Browning, M. J. (2009). T-cell immunodeficiency in CHARGE syndrome. *Acta Paediatrica*, 98, 408–410.
- Colletti, L., Colletti, G., Mandala, M., & Colletti, V. (2014). The therapeutic dilemma of cochlear nerve deficiency: Cochlear or brainstem implantation? *Otolaryngology Head and Neck Surgery*, 151, 308–314.
- Corsten-Janssen, N., du Marchie Sarvaas, G. J., Kerstjens-Frederikse, W. S., Hoefsloot, L. H., van Beynum, I. M., Kapusta, L., & van Ravenswaaij-Arts, C. M. (2014). CHD7 mutations are not a major cause of atrioventricular septal and conotruncal heart defects. *American Journal of Medical Genetics Part A*, 164A, 3003–3009.
- Corsten-Janssen, N., Saitta, S. C., Hoefsloot, L. H., McDonald-McGinn, D. M., Driscoll, D. A., Derks, R., . . . van Ravenswaaij-Arts, C. M. (2013). More clinical overlap between 22q11.2 deletion syndrome and CHARGE syndrome than often anticipated. *Molecular Syndromology*, 4, 235–245.
- Corsten-Janssen, N., van Ravenswaaij-Arts, C. M. A., & Kapusta, L. (2016). Congenital arch vessel anomalies in CHARGE syndrome: A frequent feature with risk for co-morbidity. *IJC Heart & Vasculature*, 12, 21–25.
- Costa-Barbosa, F. A., Balasubramanian, R., Keefe, K. W., Shaw, N. D., Al-Tassan, N., Plummer, L., . . . Crowley, W. F., Jr. (2013). Prioritizing genetic testing in patients with kallmann syndrome using clinical phenotypes. *The Journal of Clinical Endocrinology and Metabolism*, 98, E943–E953.
- Dobbelsteijn, C., Peacocke, S. D., Blake, K., Crist, W., & Rashid, M. (2008). Feeding difficulties in children with CHARGE syndrome: Prevalence, risk factors, and prognosis. *Dysphagia*, 23, 127–135.
- Doyle, C., & Blake, K. (2005). Scoliosis in CHARGE: A prospective survey and two case reports. *American Journal of Medical Genetics Part A*, 133A, 340–343.
- Edwards, B. M., Kileny, P. R., & Van Riper, L. A. (2002). CHARGE syndrome: A window of opportunity for audiologic intervention. *Pediatrics*, 110, 119–126.
- Forward, K. E., Cummings, E. A., & Blake, K. D. (2007). Risk factors for poor bone health in adolescents and adults with CHARGE syndrome. *American Journal of Medical Genetics Part A*, 143, 839–845.
- Fujita, K., Aida, N., Asakura, Y., Kurosawa, K., Niwa, T., Muroya, K., . . . Inoue, T. (2009). Abnormal basiocciput development in CHARGE syndrome. *AJNR American Journal of Neuroradiology*, 30, 629–634.
- Gregory, L. C., Gevers, E. F., Baker, J., Kasia, T., Chong, K., Josifova, D. J., . . . Dattani, M. T. (2013). Structural pituitary abnormalities associated with CHARGE syndrome. *The Journal of Clinical Endocrinology and Metabolism*, 98, E737–E743.
- Haldipur, P., & Millen, K. J. (2013). Deficits in early neural tube identity found in CHARGE syndrome. *Elife*, 2, e01873.
- Hale, C. L., Niederriter, A. N., Green, G. E., & Martin, D. M. (2016). Atypical phenotypes associated with pathogenic CHD7 variants and a proposal for broadening CHARGE syndrome clinical diagnostic criteria. *American Journal of Medical Genetics Part A*, 170A, 344–354.
- Harris, J., Robert, E., & Kallen, B. (1997). Epidemiology of choanal atresia with special reference to the CHARGE association. *Pediatrics*, 99, 363–367.
- Hartshorne, T. S., Nicholas, J., Grialou, T. L., & Russ, J. M. (2007). Executive function in charge syndrome. *Child Neuropsychology*, 13, 333–344.
- Hoch, M. J., Patel, S. H., Jethanamest, D., Win, W., Fatterpekar, G. M., Roland, J. T., & Hagiwara, M. (2017). Head and neck MRI findings in CHARGE syndrome. *American Journal of Neuroradiology*, <https://doi.org/10.3174/ajnr.A5297> epub ahead of print.
- Holcomb, M. A., Rumboldt, Z., & White, D. R. (2013). Cochlear nerve deficiency in children with CHARGE syndrome. *Laryngoscope*, 123, 793–796.
- Hudson, A., Macdonald, M., & Blake, K. (2016). Packing and problematic feeding behaviors in CHARGE syndrome: A qualitative analysis. *International Journal of Pediatric Otorhinolaryngology*, 82, 107–115.
- Issekutz, K. A., Graham, J. M., Jr., Prasad, C., Smith, I. M., & Blake, K. D. (2005). An epidemiological analysis of CHARGE syndrome: Preliminary results from a canadian study. *American Journal of Medical Genetics Part A*, 133, 309–317.
- Jiang, X., Zhou, Y., Xian, L., Chen, W., Wu, H., & Gao, X. (2012). The mutation in chd7 causes misexpression of bmp4 and developmental defects in telencephalic midline. *The American Journal of Pathology*, 181, 626–641.
- Jongmans, M. C., Hoefsloot, L. H., van der Donk, K. P., Admiraal, R. J., Magee, A., van de Laar, I., . . . van Ravenswaaij, C. M. (2008). Familial CHARGE syndrome and the CHD7 gene: A recurrent missense

- mutation, intrafamilial recurrence and variability. *American Journal of Medical Genetics Part A*, 146, 43–50.
- Jongmans, M. C., Ravenswaaij-Arts, C. M., Pitteloud, N., Ogata, T., Sato, N., Claahsen-van der Grinten, H. L., ... Hoefsloot, L. H. (2009). CHD7 mutations in patients initially diagnosed with kallmann syndrome—the clinical overlap with CHARGE syndrome. *Clinical Genetics*, 75, 65–71.
- Laitinen, E. M., Tommiska, J., Sane, T., Vaaralahti, K., Toppari, J., & Raivio, T. (2012). Reversible congenital hypogonadotropic hypogonadism in patients with CHD7, FGFR1 or GNRHR mutations. *PLoS ONE*, 7, e39450.
- Lalani, S. R., Hefner, M. A., Belmont, J. W., & Davenport, S. L. H. (2012). CHARGE syndrome. In R. A. Pagon, M. P. Adam, H. H. Ardinger, et al. (Eds.), *GeneReviews®*. Seattle (WA): University of Washington, Seattle.
- Lanson, B. G., Green, J. E., Roland, J. T., Jr., Lalwani, A. K., & Waltzman, S. B. (2007). Cochlear implantation in children with CHARGE syndrome: Therapeutic decisions and outcomes. *Laryngoscope*, 117, 1260–1266.
- Legendre, M., Gonzales, M., Goudefroye, G., Bilan, F., Parisot, P., Perez, M. J., ... Attie-Bitach, T. (2012). Antenatal spectrum of CHARGE syndrome in 40 fetuses with CHD7 mutations. *Journal of Medical Genetics*, 49, 698–707.
- Lemmerling, M., Dhooge, I., Mollet, P., Mortier, G., Van Cauwenberge, P., & Kunnen, M. (1998). CT of the temporal bone in the CHARGE association. *Neuroradiology*, 40, 462–465.
- Marcos, S., Sarfati, J., Leroy, C., Fouveaut, C., Parent, P., Metz, C., ... Dode, C. (2014). The prevalence of CHD7 missense versus truncating mutations is higher in patients with kallmann syndrome than in typical CHARGE patients. *The Journal of Clinical Endocrinology and Metabolism*, 99, E2138–E2143.
- McMain, K., Robitaille, J., Smith, I., Johnson, J., Wood, E., Tremblay, F., & Blake, K. (2008). Ocular features of CHARGE syndrome. *Journal of AAPOS*, 12, 460–465.
- Morimoto, A. K., Wiggins, R. H., III, Hudgins, P. A., Hedlund, G. L., Hamilton, B., Mukherji, S. K., ... Harnsberger, H. R. (2006). Absent semicircular canals in CHARGE syndrome: Radiologic spectrum of findings. *AJNR American Journal of Neuroradiology*, 27, 1663–1671.
- Ogier, J. M., Carpinelli, M. R., Arhatari, B. D., Symons, R. C., Kile, B. T., & Burt, R. A. (2014). CHD7 deficiency in “looper”, a new mouse model of CHARGE syndrome, results in ossicle malformation, otosclerosis and hearing impairment. *PLoS ONE*, 9, e97559.
- Pinto, G., Abadie, V., Mesnage, R., Blustajn, J., Cabrol, S., Amiel, J., ... Netchine, I. (2005). CHARGE syndrome includes hypogonadotropic hypogonadism and abnormal olfactory bulb development. *The Journal of Clinical Endocrinology and Metabolism*, 90, 5621–5626.
- Ragan, D. C., Casale, A. J., Rink, R. C., Cain, M. P., & Weaver, D. D. (1999). Genitourinary anomalies in the CHARGE association. *Journal of Urology*, 161, 622–625.
- Reinfeldt, S., Hakansson, B., Taghavi, H., & Eeg-Olofsson, M. (2015). New developments in bone-conduction hearing implants: A review. *Medical Devices (Auckland)*, 8, 79–93.
- Roger, G., Morisseau-Durand, M. P., Van Den Abbeele, T., Nicollas, R., Triglia, J. M., Narcy, P., ... Garabedian, E. N. (1999). The CHARGE association: The role of tracheotomy. *Archives of Otolaryngology-Head and Neck Surgery*, 125, 33–38.
- Russell-Eggitt, I. M., Blake, K. D., Taylor, D. S., & Wyse, R. K. (1990). The eye in the CHARGE association. *British Journal of Ophthalmology*, 74, 421–426.
- Sanlaville, D., Etchevers, H. C., Gonzales, M., Martinovic, J., Clement-Ziza, M., Delezoide, A. L., ... Attie-Bitach, T. (2006). Phenotypic spectrum of CHARGE syndrome in fetuses with CHD7 truncating mutations correlates with expression during human development. *Journal of Medical Genetics*, 43, 211–217.
- Sato, N., Hasegawa, T., Hasegawa, Y., Arisaka, O., Ozono, K., Amemiya, S., ... Tanaka, T. (2015). Treatment situation of male hypogonadotropic hypogonadism in pediatrics and proposal of testosterone and gonadotropins replacement therapy protocols. *Clinical Pediatric Endocrinology*, 24, 37–49.
- Sohn, Y. B., Ko, J. M., Shin, C. H., Yang, S. W., Chae, J. H., & Lee, K. A. (2016). Cerebellar vermis hypoplasia in CHARGE syndrome: Clinical and molecular characterization of 18 unrelated korean patients. *Journal of Human Genetics*, 61, 235–239.
- Song, M. H., Cho, H. J., Lee, H. K., Kwon, T. J., Lee, W. S., Oh, S., ... Kim, U. K. (2011). CHD7 mutational analysis and clinical considerations for auditory rehabilitation in deaf patients with CHARGE syndrome. *PLoS ONE*, 6, e24511.
- Sperry, E. D., Hurd, E. A., Durham, M. A., Reamer, E. N., Stein, A. B., & Martin, D. M. (2014). The chromatin remodeling protein CHD7, mutated in CHARGE syndrome, is necessary for proper craniofacial and tracheal development. *Developmental Dynamics*, 243, 1055–1066.
- Stack, C. G., & Wyse, R. K. (1991). Incidence and management of airway problems in the CHARGE association. *Anaesthesia*, 46, 582–585.
- Tellier, A. L., Cormier-Daire, V., Abadie, V., Amiel, J., Sigaudy, S., Bonnet, D., ... Lyonnet, S. (1998). CHARGE syndrome: Report of 47 cases and review. *American Journal of Medical Genetics*, 76, 402–409.
- Thelin, J. W., & Fussner, J. C. (2005). Factors related to the development of communication in CHARGE syndrome. *American Journal of Medical Genetics Part A*, 133, 282–290.
- Tilea, B., Garel, C., Menez, F., Vuillard, E., Elmaleh-Berges, M., Delezoide, A. L., & Sebag, G. (2006). Contribution of fetal MRI to the diagnosis of inner ear abnormalities: Report of two cases. *Pediatric Radiology*, 36, 149–154.
- Trider, C. L., Arra-Robar, A., van Ravenswaaij-Arts, C., & Blake, K. (2017). Developing a CHARGE syndrome checklist: Health supervision across the lifespan (from head to toe). *American Journal of Medical Genetics Part A*, 173, 684–691.
- Trider, C. L., & Blake, K. (2012). Obstructive sleep apnea in a patient with CHARGE syndrome. *Case Reports in Otolaryngology*, 2012, 907032.
- Verloes, A. (2005). Updated diagnostic criteria for CHARGE syndrome: A proposal. *American Journal of Medical Genetics Part A*, 133, 306–308.
- Vesseur, A., Free, R., Langereis, M., Snels, C., Snik, A., Ravenswaaij-Arts, C., & Mylanus, E. (2016a). Suggestions for a guideline for cochlear implantation in CHARGE syndrome. *Otology and Neurotology*, 37, 1275–1283.
- Vesseur, A. C., Verbist, B. M., Westerlaan, H. E., Klooststra, F. J. J., Admiraal, R. J. C., van Ravenswaaij-Arts, C. M. A., ... Mylanus, E. A. M. (2016b). CT findings of the temporal bone in CHARGE syndrome: Aspects of importance in cochlear implant surgery. *European Archives of Oto-Rhino-Laryngology*, 273, 4225–4240.
- Wheeler, P. G., Quigley, C. A., Sadeghi-Nejad, A., & Weaver, D. D. (2000). Hypogonadism and CHARGE association. *American Journal of Medical Genetics*, 94, 228–231.
- White, D. R., Giambra, B. K., Hopkin, R. J., Daines, C. L., & Rutter, M. J. (2005). Aspiration in children with CHARGE syndrome. *International Journal of Pediatric Otorhinolaryngology*, 69, 1205–1209.
- Wiener-Vacher, S. R., Amanou, L., Denise, P., Narcy, P., & Manach, Y. (1999). Vestibular function in children with the CHARGE association. *Archives of Otolaryngology-Head and Neck Surgery*, 125, 342–347.
- Wincent, J., Holmberg, E., Stromland, K., Soller, M., Mirzaei, L., Djureinovic, T., ... Schoumans, J. (2008). CHD7 mutation spectrum in 28 swedish patients diagnosed with CHARGE syndrome. *Clinical Genetics*, 74, 31–38.
- Wincent, J., Schulze, A., & Schoumans, J. (2009). Detection of CHD7 deletions by MLPA in CHARGE syndrome patients with a less typical phenotype. *European Journal of Medical Genetics*, 52, 271–272.
- Wong, M. T., Lambeck, A. J., van der Burg, M., la Bastide-van Gemert, S., Hogendorf, L. A., van Ravenswaaij-Arts, C. M., & Scholvinck, E. H. (2015). Immune dysfunction in children with CHARGE syndrome: A cross-sectional study. *PLoS ONE*, 10, e0142350.
- Wong, M. T., van Ravenswaaij-Arts, C. M., Munns, C. F., Hsu, P., Mehr, S., & Bocca, G. (2016). Central adrenal insufficiency is not a common feature in CHARGE syndrome: A cross-sectional study in 2 cohorts. *Journal of Pediatrics*, 176, 150–155.

- Writzl, K., Cale, C. M., Pierce, C. M., Wilson, L. C., & Hennekam, R. C. (2007). Immunological abnormalities in CHARGE syndrome. *European Journal of Medical Genetics*, 50, 338–345.
- Wyse, R. K., al-Mahdawi, S., Burn, J., & Blake, K. (1993). Congenital heart disease in CHARGE association. *Pediatric Cardiology*, 14, 75–81.
- Yanicostas, C., Herbolme, E., Dipietromaria, A., & Soussi-Yanicostas, N. (2009). Anosmin-1a is required for fasciculation and terminal targeting of olfactory sensory neuron axons in the zebrafish olfactory system. *Molecular and Cellular Endocrinology*, 312, 53–60.
- Yu, T., Meiners, L. C., Danielsen, K., Wong, M. T., Bowler, T., Reinberg, D., ... Basson, M. A. (2013). Deregulated FGF and homeotic gene expression underlies cerebellar vermis hypoplasia in CHARGE syndrome. *Elife*, 2, e01305.



CHRISTA M. DE GEUS is a medical doctor in training to become a clinical geneticist. She is working toward her PhD, which focuses on neurological symptoms in CHARGE syndrome.



ROLIEN H. FREE, MD, PhD, is an otolaryngologist/otologist/pediatric otolaryngologist whose particular focus is on ear surgery and cochlear implantation. She has published extensively on this subject, including articles about radiological findings, cochlear implantation, and speech language development in CHARGE patients. She is the otolaryngologist of the CHARGE center of expertise in Groningen, The Netherlands.



BERIT M. VERBIST is a head and neck radiologist at the Leiden University Medical Center with a specific interest in otology and neurotology. Her research in that area focuses on cochlear implantation. She has published about imaging abnormalities in CHARGE syndrome and the relevance to cochlear implantation.



DEBORAH A. SIVAL, MD, PhD, is a pediatric neurologist, with a specific interest in the field of fetal and neonatal developmental neurology. She is the pediatric neurologist involved in the CHARGE center of expertise in Groningen, the Netherlands.



Dr. KIM BLAKE is a Professor of Pediatrics at Dalhousie University Medical School and a General Pediatrician at the IWK Health Centre in Halifax, Canada. She is an international expert in the area of CHARGE syndrome. She runs a multi-disciplinary Atlantic Canadian CHARGE syndrome clinic at a large pediatric tertiary care center (IWK Health Centre) in Halifax.



LINDA C. MEINERS, MD, PhD, is a pediatric neuroradiologist. She has been associated with the CHARGE center of expertise in Groningen since 2009.



CONNIE M. A. VAN RAVENSWAAIJ-ARTS, MD, PhD is a consultant in Clinical Genetics and Professor in Dysmorphology at the Department of Genetics of the University Medical Center Groningen, Netherlands. Her research projects focus on neurodevelopmental syndromes, with a special interest in CHARGE syndrome and rare chromosomal disorders. She coordinates an accredited center of expertise for both these disorders and is a member of the European Reference Network ITHACA.

SUPPORTING INFORMATION

Additional Supporting Information may be found online in the supporting information tab for this article.

How to cite this article: de Geus CM, Free RH, Verbist BM, et al. Guidelines in CHARGE syndrome and the missing link: Cranial imaging. *Am J Med Genet Part C Semin Med Genet*. 2017;175C:450–464. <https://doi.org/10.1002/ajmg.c.31593>