

Adenosine-sensitive decremental conduction over short non-decremental atrioventricular accessory pathways after radiofrequency ablation: case series

Jan Hluchy^{1*}, Marc Van Bracht¹, and Bodo Brandts^{1,2}

¹Division of Clinical Electrophysiology, Department of Cardiology and Angiology, Augusta-Kranken-Anstalt, Bergstr. 26, 44791 Bochum, Germany; and ²Witten-Herdecke University, Alfred-Herrhausen-Straße 50, 58448 Witten, Germany

Received 28 September 2017; accepted 9 March 2018; online publish-ahead-of-print 4 April 2018

Introduction

Decremental conduction in short anterograde atrioventricular accessory pathways (AV-APs) is rare.

Case presentation

We report on two cases with radiofrequency (RF) ablation of anterograde fast non-decremental AV-AP conduction. In Case 1, electrophysiological testing revealed fast non-decremental conduction over an anterograde short right posteroseptal AV-AP. During ablation, latent pre-excitation due to anterograde adenosine-sensitive slow decremental conduction over the same AV-AP manifested after eliminating its non-decremental conduction. Complete abolition of AP conduction was achieved by additional ablation. In Case 2, overt pre-excitation disappeared after the first ablation session for an anterograde short non-decremental right mid-septal AV-AP. However, latent pre-excitation due to markedly decremental conduction over the same AV-AP unmasked by intravenous adenosine and atrial pacing manoeuvres could be eliminated in a second session.

Discussion

This report describes unusual anterograde short non-decremental AV-APs, developing markedly slow adenosine-sensitive decremental conduction during ablation. Such AV-AP conduction properties due to RF injury may be overlooked and mask incomplete ablation and point-out careful testing including stimulation techniques and low and higher dose adenosine administration post-ablation.

Keywords

Case series • Wolff-Parkinson-White syndrome • Latent pre-excitation • Atrioventricular accessory pathway • Decremental conduction • Radiofrequency ablation

Learning points

- This study describes anterograde short non-decremental accessory pathways in which markedly slow adenosine-sensitive decremental conduction appeared during radiofrequency (RF) ablation, most likely due to injury-induced non-uniform anisotropy.
- Rare RF injury-induced accessory pathway properties may be overlooked and mask incomplete ablation and stress the importance of a thorough evaluation of the absence of accessory pathway conduction after ablation.

Introduction

Short atrioventricular accessory pathways (AV-APs) are usually fast and non-decremental. Slow decremental AV-APs are uncommon and usually concealed.^{1,2} Nevertheless, decremental conduction properties in short anterograde AV-APs have rarely been reported.^{3,4}

We report two cases with anterograde short AV-APs, one right posteroseptal and the other right mid-septal, in which anterograde slow decremental conduction with latent pre-excitation manifested after initial radiofrequency (RF) ablation.

* Corresponding author. Tel: +49 234 517 2351, Fax: +49 234 517 2373, Email: hluchy@degedi.de. This case report was reviewed by A. Justin Luermans and George K. Andrikopoulos.

© The Author(s) 2018. Published by Oxford University Press on behalf of the European Society of Cardiology.

This is an Open Access article distributed under the terms of the Creative Commons Attribution Non-Commercial License (<http://creativecommons.org/licenses/by-nc/4.0/>), which permits non-commercial re-use, distribution, and reproduction in any medium, provided the original work is properly cited. For commercial re-use, please contact journals.permissions@oup.com

Timeline

Time	Case 1	Case 2
Day 1	<p>No evidence for structural heart disease according to non-invasive diagnostic workup done in another institution.</p> <p>Overt WPW syndrome and a history of recurrent palpitations and syncope since the childhood, non-responsive to oral sotalol.</p> <p>On admission, overt ventricular pre-excitation and unremarkable physical exam, and diagnostic assessment.</p>	<p>No evidence for structural heart disease according to non-invasive diagnostic workup done in another institution.</p> <p>Recurrent palpitations and syncope 3 weeks after radiofrequency (RF) catheter ablation for overt WPW syndrome performed in another institution, resulting in non-preexcited sinus rhythm (SR).</p> <p>On admission, non-preexcited SR and unremarkable physical exam, and diagnostic assessment.</p>
Day 2	Complication-free electrophysiological study and RF catheter ablation in a drug-free state.	Complication-free electrophysiological study and RF catheter ablation in a drug-free state.
Day 3	Echocardiogram, 12-lead electrocardiogram (ECG), Holter ECG.	Echocardiogram, 12-lead ECG, Holter ECG.
Follow-up (9 months)	Interviews, 12-lead ECGs, Holter ECGs: uneventful.	Interviews, 12-lead ECGs, Holter ECGs: uneventful.

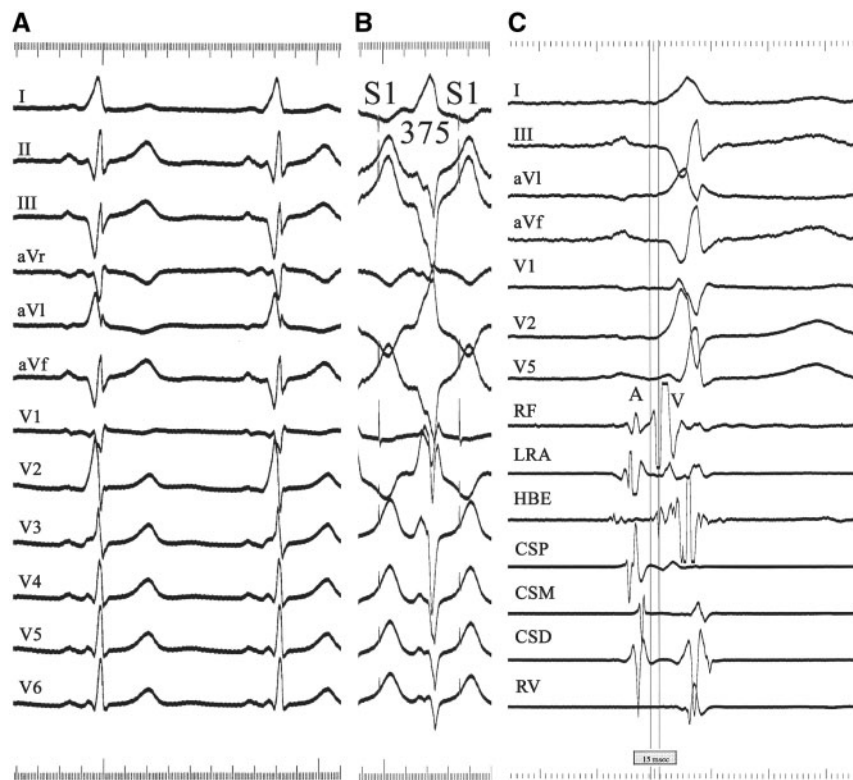


Figure 1 Case 1: electrocardiogram with overt pre-excitation during sinus rhythm (A) and atrial pacing at a cycle length (S1S1) of 375 ms (B). Paper speed = 50 mm/s. (C) Bipolar electrogram (radiofrequency, RF) before ablation of fast accessory pathway conduction. Paper speed = 200 mm/s. A, atrial electrogram; V, ventricular electrogram; CSP, proximal coronary sinus; CSM, middle coronary sinus; CSD, distal coronary sinus; HBE, His-bundle electrogram; LRA, low right atrium; RV, right ventricle.

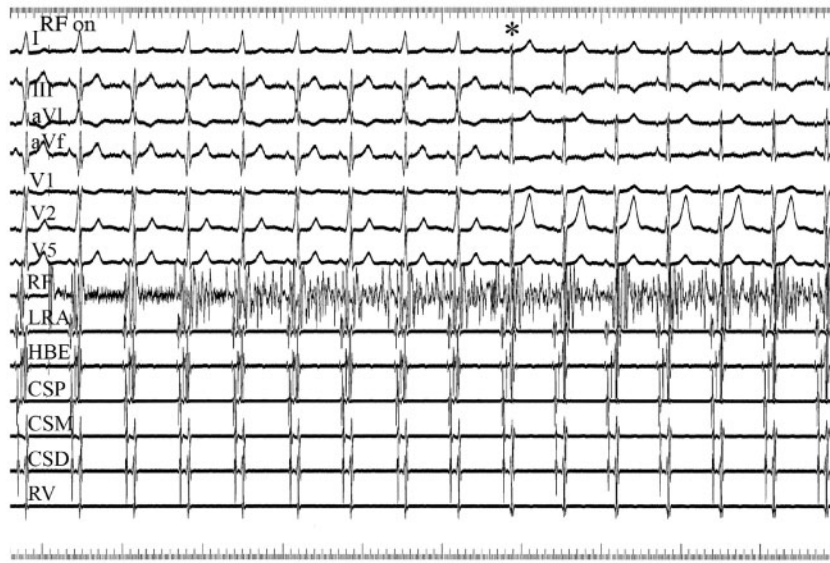


Figure 2 Case 1: radiofrequency ablation during sinus rhythm. Asterisk indicates block of fast accessory pathway conduction followed by non-pre-excited sinus rhythm. Paper speed = 25 mm/s. Abbreviations as listed in Figure 1.

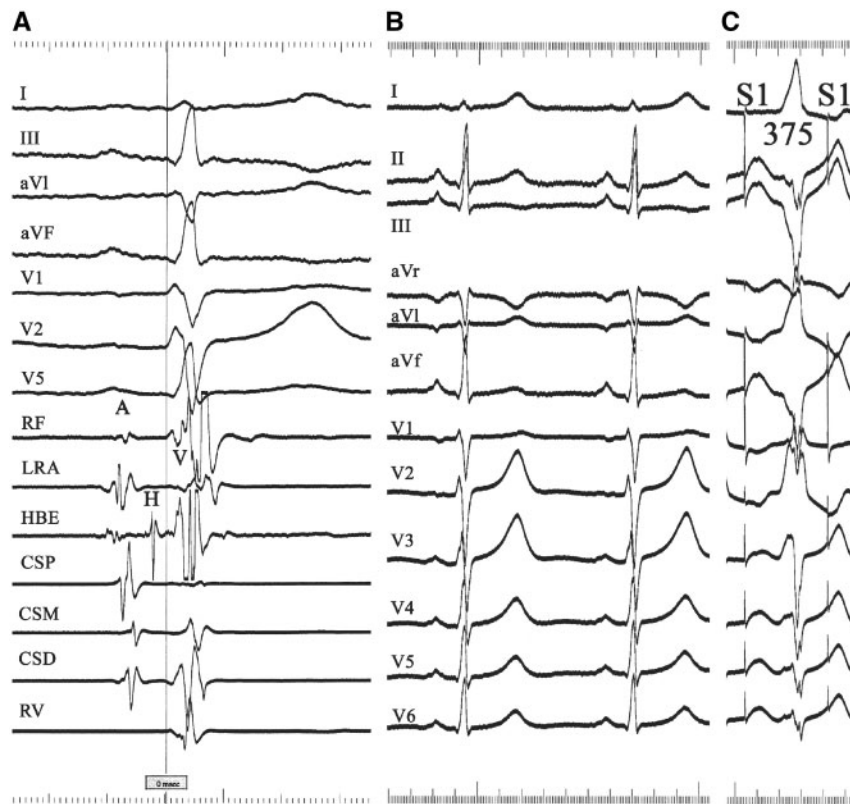


Figure 3 Case 1: bipolar electrogram (radiofrequency) recording (A) and electrocardiogram (B) during non-preexcited sinus rhythm after ablation of fast accessory pathway conduction. (C) Electrocardiogram during atrial pacing at a cycle length (S1S1) of 375 ms unmasking a nearly maximum ventricular pre-excitation. H, His-bundle potential. Abbreviations as listed in Figure 1.

An electrophysiological study was performed using standard electrode catheters with 10-mm interelectrode spacing (Daig, St. Jude Medical, St. Paul, MN, USA). Quadripolar catheters were used for stimulation and recording from the high right atrium and right ventricular apex. Two hexapolar catheters were positioned within the coronary sinus for left atrial activity recording and stimulation and across the tricuspid valve for His-bundle (distal pair) and low right atrial (proximal pair) activity recording. A steerable quadripolar 7-Fr catheter with a 4 mm tip electrode (Mariner, Medtronic, Minneapolis, MN, USA) was used for mapping and temperature-guided RF ablation along the tricuspid annulus.

Case series

Case 1

A 25-year-old woman with overt Wolff–Parkinson–White syndrome suggestive of a right posteroseptal AV-AP and a history of syncope associated with sustained paroxysmal palpitations was referred for RF ablation.

The electrocardiogram in sinus rhythm (SR) showed a PR interval of 0.11 s and a QRS duration of 0.12 s with a negative delta wave in the inferior leads and lead V1 as well as a R/S transition between V1 and V2 (Figure 1A).

Programmed atrial and ventricular stimulation revealed fast non-decremental conduction over a unidirectional anterograde right posteroseptal AV-AP and retrograde dual AV nodal pathway conduction. The effective refractory periods (ERPs) of the anterograde AV-AP and the AV node were 270 and 230 ms, respectively. With incremental atrial pacing, a maximum pre-excitation pattern at a cycle length (CL) of 400–353 ms (Figure 1B) and anterograde conduction block over the AV-AP followed by 1:1 conduction over the AV node–His–Purkinje system axis at a CL of 333 ms were demonstrated. Mapping the right posteroseptal region, the shortest AV interval (45 ms) with the earliest ventricular activation preceding the delta wave (-15 ms) were found inferior to the coronary sinus ostium (Figure 1C). Two applications of RF energy at the mapped posteroseptal site resulted reproducibly in prompt transient AP conduction block. A third RF application abolished ventricular pre-excitation (Figures 2 and 3A, B).

Post-ablation, incremental atrial pacing, and atrial extra-stimulation performed during non-preexcited SR revealed a marked slow and decremental AP conduction resulting progressively in a marked to nearly maximum pre-excitation pattern similar to that before ablation (Figures 3C and 4).

The ERP (240 ms) and the longest atrial paced CL with conduction block of the AV-AP (353 ms) were similar to those before ablation. This was suggestive of conduction over the same short AV-AP, showing the earliest ventricular activation at the level of the tricuspid annulus.

Intravenous administration of adenosine during non-preexcited SR resulted in unmasking latent ventricular pre-excitation due to slow decremental AV-AP conduction (6 and 12 mg; Figure 5A) and transient complete AV block (18 mg; Figure 5B). The maximum pre-excitation pattern (Figure 5A) was identical to that during atrial pacing techniques pre-ablation. Complete permanent elimination of AV-AP conduction was achieved by delivering additional nine RF applications during atrial pacing within the same right posteroseptal region (Figure 6), which was verified by intravenous adenosine and programmed stimulation before and after isoproterenol.

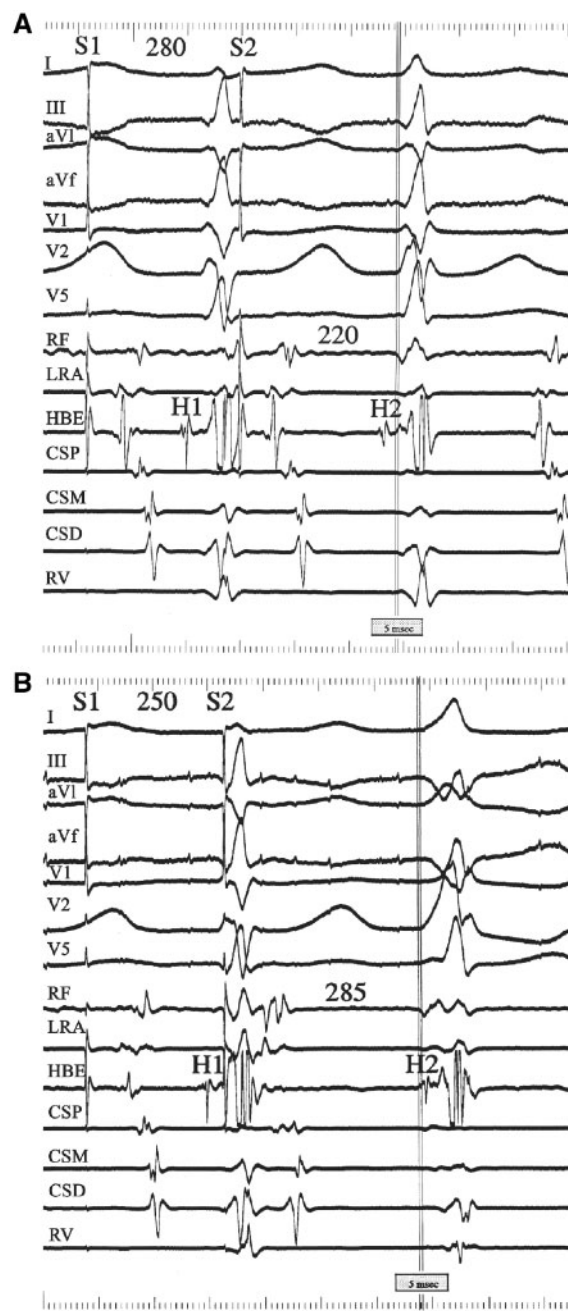


Figure 4 Case 1: atrial extra-stimulation (S2) coupled with atrial driving (S1S1 400 ms) after ablation of fast accessory pathway conduction. With atrial prematurity (S1S2) shortening from 280 (A) to 250 ms (B), the local S2- Δ 2 measured in the radiofrequency progressively lengthened along with a progressive pre-excitation pattern. Note a delayed local ventricular activation in the radiofrequency inscribed after non-preexcited QRS complexes during atrial driving. Paper speed = 150 ms. Abbreviations as listed in Figure 1.

Case 2

In a 17-year-old woman with a history of syncope, overt pre-excitation disappeared after RF ablation performed at another institution for a non-decremental anterograde right mid-septal AV-AP.

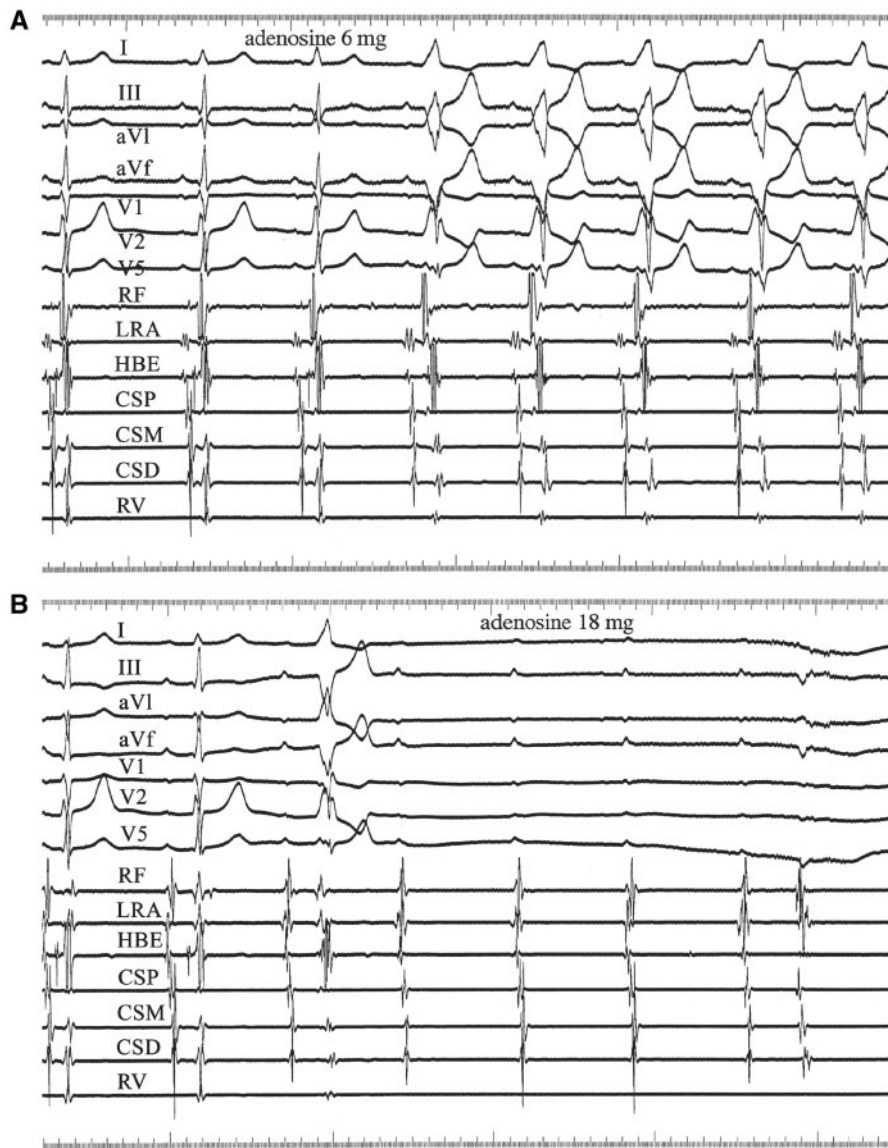


Figure 5 Case 1: intravenous adenosine during non-preexcited sinus rhythm. (A) After 6 mg adenosine, three non-preexcited sinus beats with a progressive PR time prolongation are followed by sinus beats conducted with unmasked pre-excitation. (B) After 18 mg adenosine, two non-preexcited sinus beats are followed by one pre-excited sinus beat with a long PR interval, followed by transient complete atrioventricular block. Paper speed = 50 mm/s. Abbreviations as listed in Figure 1.

However, 3 weeks later, she complained about recurrent palpitations and syncope. During non-preexcited SR (Figure 7A), latent pre-excitation due to markedly decremental conduction over the same AV-AP could be unmasked by intravenous administration of 6 mg adenosine (12 mg induced self-terminating atrial fibrillation) and atrial pacing manoeuvres (Figure 7B and 7C).

During incremental atrial pacing and extra-stimulation from the proximal coronary sinus, there was a prolongation of 50 ms of the atrial-delta wave interval and the ERP of the AV-AP was 300 ms. Mapping of the right atrial mid-septum two-thirds of the way from the His-bundle towards the coronary sinus ostium revealed the earliest ventricular activation (-31 ms) with an AV interval of 85 ms demonstrable during high right atrial pacing at a CL of 462 ms

(Figure 7D). A single RF application delivered at this site during atrial pacing resulted in prompt conduction block in the AV-AP and accelerated junctional tachycardia. Post-ablation, both programmed atrial stimulation and intravenous adenosine (6 mg) before and after isoproterenol revealed permanent elimination of AV-AP conduction.

Discussion

For anterograde and retrograde decremental AV-APs heterogeneous electrophysiological properties have been reported.⁵⁻⁷ These pathways are usually adenosine-sensitive and consist of partially depolarized fibers with depressed fast-Na⁺ channels. Some of

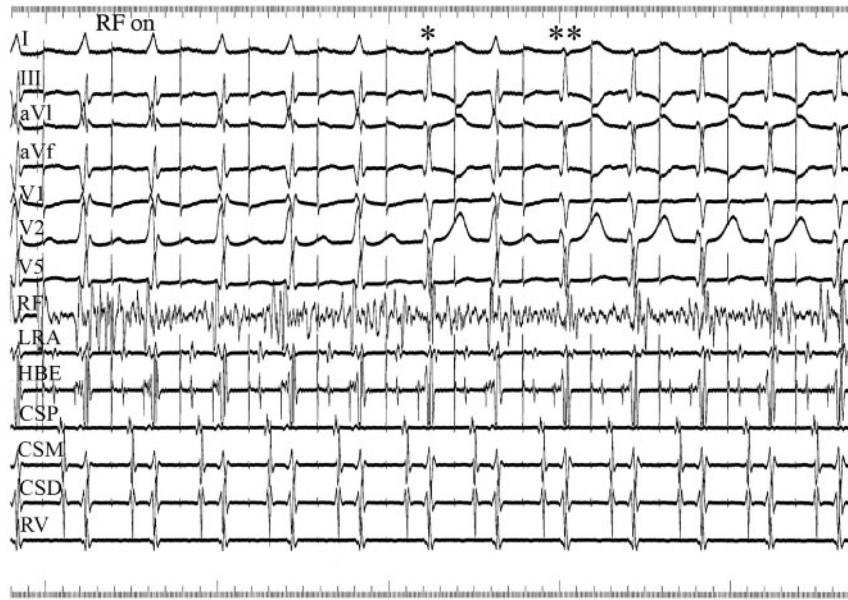


Figure 6 Case 1: radiofrequency ablation during atrial pacing. Single (*) and double (***) asterisks indicate transient and persistent accessory pathway block, respectively. Paper speed = 50 mm/s.

decremental AV-APs, especially those with permanent junctional reciprocating tachycardia, that respond to both adenosine-induced hyperpolarizing K⁺ current and verapamil-induced block of the slow-inward calcium current have properties consistent with AV nodal-like tissue. Recently, unusual decremental AV-APs either latent, demonstrable only during circus movement tachycardia or overt, exhibiting functional longitudinal dissociation have been reported.⁴

In this study, our cases had latent pre-excitation due to markedly slow decremental conduction in anterograde septal AV-APs, manifesting after initial ablation. Our results suggest that in patients with slow decremental AV-AP conduction emerging during ablation, intravenous adenosine in a titrated dosage is useful for evaluating latent pre-excitation before and after ablation if administered in a low dose (6–12 mg), whereas it may induce AV-AP conduction block if administered in a higher dose (18 mg). A similar pathway has been reported in which slow conduction disappeared spontaneously within 15 min after ablation.⁸ However, neither atrial extra-stimulation before nor administration of adenosine before and after ablation were performed. Recently, dormant AV-AP conduction after ablation unmasked by adenosine and possibly due to AP membrane potential hyperpolarization has been reported.⁹ A thorough analysis of dormant AP conduction properties by using stimulation techniques was not done.

It has been suggested that in two components of the same AP, RF energy might destroy the fast-conducting AP fibres leaving the slow-conducting component undamaged.^{8,10} Alternatively, initial RF application could create partial damage to a single fast-conducting pathway (AV-AP) or the peri-accessory pathway tissue, resulting in decremental AP conduction properties like partially depressed or AV nodal-like fibres or due to alteration of the impedance mismatch.^{8,10,11} The fact that such decremental AV-APs do clinically exist is in support of the former explanation in our cases.⁴ Furthermore, complex RF ablation needed for

complete elimination of AV-AP conduction suggests that such electrophysiological conduction properties in the AV-APs can be due to their multifibre structure.^{4,12,13} In one report on six patients with short non-decremental septal AV-APs in whom after eliminating fast AP conduction, acquired decremental conduction was localized in the coronary venous system in five of them.¹³ The authors suggested that RF ablation-mediated injury of part of the coronary sinus myocardial coating fibres might set the stage of slow conduction. In our two cases, both rapid non-decremental and slow decremental conduction were sequentially ablated within the same region outside the coronary venous system.

Our cases demonstrated a single anterograde AV-AP with overt fast non-decremental before and persistent latent slow decremental conduction properties during ablation. According to our proposed explanation, similar to known micro-fibrosis with aging and the changes in the border zone of healed myocardial infarctions resulting in the change from uniform to non-uniform anisotropic properties,¹⁴ elimination of side-to-side electrical coupling of parallel fibres due to RF injury in our cases most likely caused such a change from uniform to non-uniform anisotropic conduction in the same AV-AP, resulting in fast longitudinal conduction block parallel to the fibres and very slow decremental transverse conduction perpendicular to their longitudinal alignment. Alternatively, slow AV-AP conduction in association with non-uniform anisotropy created by partial damage to the atrial peri-accessory pathway tissue cannot be excluded. The classic anatomic model of dual AP conduction in absence of any direct or indirect criteria of dual AP conduction, as published previously, would not allow to explain the mechanism responsible for this.^{12,15} According to this 'RF injury model' of slow decremental AV-AP conduction, one may speculate that natural slow and decremental conduction in the short anterograde and concealed AV-APs may be the result of the change of anisotropic properties from uniform to

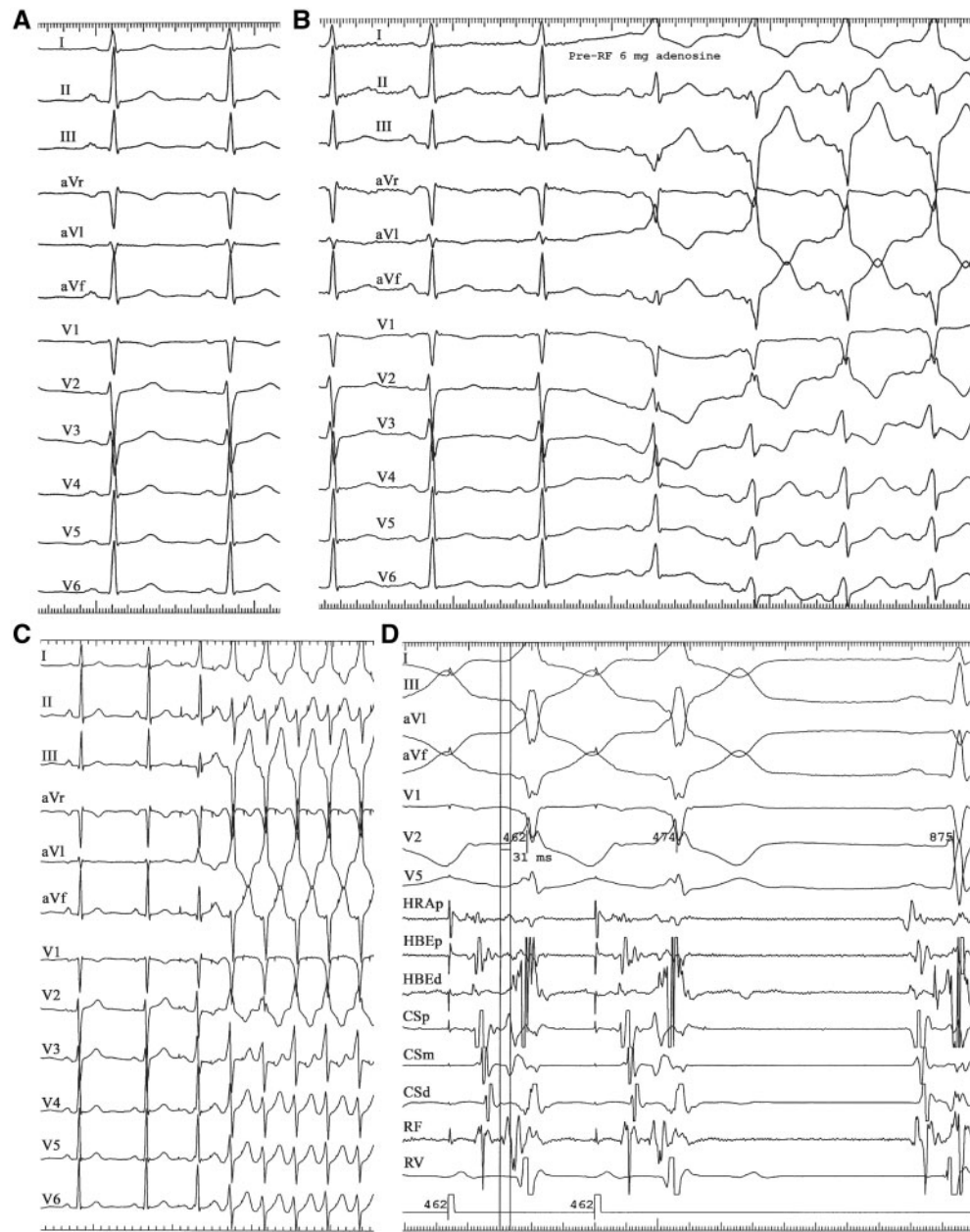


Figure 7 Case 2: electrocardiogram showing non-preexcited sinus rhythm (A, paper speed = 50 mm/s) and latent pre-excitation unmasked by intravenous adenosine (6 mg) (B, paper speed = 50 mm/s) and atrial pacing (C, paper speed = 25 mm/s). (D) Bipolar electrogram (radiofrequency) at the ablation site recorded during high right atrial pacing at a cycle length of 462 ms. Paper speed = 100 mm/s.

non-uniform during development following birth and with aging as previously observed in myocardial bundles.¹⁴

Finally, in Case 2 which underwent the first ablation session at another institution, duality of anterograde AV-AP conduction as a result of two distinct but closely located AV-APs cannot be excluded.

Consent: Consent for publication was not obtained by the authors for the patients in this case series. It is felt by the *EHJ-CR* editorial board that benefit of publication of this case series outweighs a lack

of consent. Every effort has been made to ensure that patient's are not identifiable in this publication.

Conflict of interest: none declared.

References

1. Ticho BC, Saul PS, Hulse JE, De W, Lulu J, Walsh EP. Variable location of accessory pathways associated with the permanent form of junctional reciprocating tachycardia and confirmation by radiofrequency ablation. *Am J Cardiol* 1992;**70**: 1559–1564.

2. Gaita F, Haissaguerre M, Giustetto C, Fischer B, Riccardi R, Richiardi E, et al. Catheter ablation of permanent junctional reciprocating tachycardia with radiofrequency current. *J Am Coll Cardiol* 1995;**25**:648–654.
3. Haissaguerre M, Cauchemez B, Marcus F, Le Métayer P, Lauribe P, Poquet F, et al. Characteristics of the ventricular insertion sites of accessory pathways with anterograde decremental conduction properties. *Circulation* 1995;**91**:1077–1085.
4. Hluchy J, Schickel S, Schlegelmilch P, Jörgen U, Brägelmann F, Sabin GV. Decremental conduction properties in overt and concealed atrioventricular accessory pathways. *Europace* 2000;**2**:42–53.
5. Lerman BB, Greenberg M, Overholt ED, Swerdlow CD, Smith RT, Sellers TD, et al. Differential electrophysiologic properties of decremental retrograde pathways in long RP tachycardia. *Circulation* 1987;**76**:21–31.
6. Tai DY, Chang M-S, Svinarich JT, Chang BN, Sung RJ. Mechanisms of verapamil-induced conduction block in anomalous atrioventricular bypass tracts. *J Am Coll Cardiol* 1985;**5**:311–317.
7. Chen S-A, Tai C-T, Chiang C-E, Lee S-H, Wen Z-C, Chiou C-W, et al. Electrophysiologic characteristics, electropharmacologic responses and radiofrequency ablation in patients with decremental accessory pathway. *J Am Coll Cardiol* 1996;**28**:732–737.
8. Kawabata M, Nawata H, Hirao K, Miyasaka N, Kawara T, Hiejima K, et al. Marked anterograde decremental conduction over a rapidly conducting accessory pathway after radiofrequency ablation. *J Electrocardiol* 2000;**33**:71–78.
9. Spotnitz MD, Markowitz SM, Liu CF, Thomas G, Ip JE, Liez J, et al. Mechanisms and clinical significance of adenosine-induced dormant accessory pathway conduction after catheter ablation. *Circ Arrhythm Electrophysiol* 2014;**7**:1136–1143.
10. Chen S-A, Tai C-T, Lee SH, Chiang C-E, Wen Z-C, Chiou C-W, et al. Electrophysiologic characteristics and anatomical complexities of accessory atrioventricular pathways with successful ablation of anterograde and retrograde conduction at discrete sites. *J Cardiovasc Electrophysiol* 1996;**7**:907–915.
11. Inoue H, Zipes DP. Conduction over an isthmus of atrial myocardium in vivo: A possible model of Wolff-Parkinson-White syndrome. *Circulation* 1987;**76**:637–647.
12. Chien WW, Lesh MD. Radiofrequency catheter ablation of an accessory pathway with discontinuous retrograde conduction: potential insights into mechanism of longitudinal dissociation. *Am Heart J* 1993;**126**:712–715.
13. Sternick EB, Correa FS, Rego S, Santos DM, Damascena F, Scarpelli R, et al. Post-ablation acquired short atrioventricular Mahaim-type fibers: Observations on their clinical, electrocardiographic, and electrophysiologic profile. *Heart Rhythm* 2012;**9**:850–858.
14. Spach MS. Anisotropic structural complexities in the genesis of re-entrant arrhythmias. *Circulation* 1991;**84**:1447–1450.
15. Atie J, Brugada P, Brugada J, Smeets JLRM, Cruz FES, Peres A, et al. Longitudinal dissociation of atrioventricular accessory pathway. *J Am Coll Cardiol* 1991;**17**:161–166.