

Received: 2017.08.22
Accepted: 2017.12.12
Published: 2018.03.18

e-ISSN 1941-5923
© Am J Case Rep, 2018; 19: 309-313
DOI: 10.12659/AJCR.906767

A Case of Lown-Ganong-Levine Syndrome: Due to an Accessory Pathway of James Fibers or Enhanced Atrioventricular Nodal Conduction (EAVNC)?

Authors' Contribution:
Study Design A
Data Collection B
Statistical Analysis C
Data Interpretation D
Manuscript Preparation E
Literature Search F
Funds Collection G

BEF 1 **Juanita Hunter**
B 2 **Emmanouil Tsounias**
A 3 **John Cogan**
ABCDEF 4 **Ming-Lon Young**

1 Department of Pediatrics, University of Miami, Miami, FL, U.S.A.
2 Department of Pediatrics, Mercy Medical Center, Flushing, NY, U.S.A.
3 Department of Internal Medicine, Memorial Healthcare System, Hollywood, FL, U.S.A.
4 Heart Institute, Joe DiMaggio Children's Hospital, Hollywood, FL, U.S.A.

Corresponding Author: Ming-Lon Young, e-mail: mingyoung@mhs.net
Conflict of interest: None declared

Patient: Male, 17
Final Diagnosis: Lown-Ganong-Levine syndrome
Symptoms: Tachycardia
Medication: —
Clinical Procedure: Catheter ablation
Specialty: Cardiology





Objective: Unknown etiology
Background: Lown-Ganong-Levine syndrome, includes a short PR interval, normal QRS complex, and paroxysmal tachycardia. The pathophysiology of this syndrome includes an accessory pathway connecting the atria and the atrioventricular (AV) node (James fiber), or between the atria and the His bundle (Brenchenmacher fiber). Similar features are seen in enhanced atrioventricular nodal conduction (EAVNC), with the underlying pathophysiology due to a fast pathway to the AV node, and with the diagnosis requiring specific electrophysiologic criteria.

Case Report: A 17-year-old man presented with a history of recurrent narrow-complex and wide-complex tachycardia on electrocardiogram (ECG). An electrophysiologic study showed an unusually short atrial to His (AH) conduction interval and a normal His to ventricle (HV) interval, without a delta wave. Two stable AH intervals coexisted in the same atrial pacing cycle length. In the recovery curve study, this pathway had a flat conduction curve without an AH increase until the last 60 ms, before reaching the effective refractory period. These ECG changes did not respond to an adenosine challenge. When this pathway became intermittent, there was a paradoxical response to adenosine challenge with conduction via a short AH interval, but without conduction block. Catheter ablation of the AV nodal region resulted in a normalized AH interval, decremental conduction properties, and resulted in a positive response to an adenosine challenge.

Conclusions: In this case of Lown-Ganong-Levine syndrome, electrophysiologic studies supported the role of the accessory pathway of James fibers.

MeSH Keywords: Accessory Atrioventricular Bundle • Catheter Ablation • Lown-Ganong-Levine Syndrome

Full-text PDF: <https://www.amjcaserep.com/abstract/index/idArt/906767>

 2132   3  8



Background

Lown-Ganong-Levine syndrome, with the electrocardiographic (ECG) findings of a short PR interval, a normal QRS complex, and paroxysmal tachycardia, was first described in 1938 [1], and was further characterized by Lown, Ganong, and Levine in 1952 [2]. The proposed pathophysiology of Lown-Ganong-Levine syndrome involves accessory pathway connections between the atria and low atrioventricular (AV) node, as described by James in 1961 [3], or between the atria and the His bundle, as described by Brechenmacher in 1975 [4]. Similar electrophysiologic findings with supraventricular tachycardia (SVT) and without a delta wave are seen in enhanced atrioventricular nodal conduction (EAVNC), with the underlying pathophysiology due to a fast pathway to the AV node, and with the diagnosis requiring specific electrophysiologic criteria. The ECG findings in EAVNC include a short atrial to His (AH) conduction interval of ≤ 60 ms during sinus rhythm, intact AV conduction with a short atrial paced cycle length of ≤ 300 ms, and a small AH increment of ≤ 100 ms as paced atrial cycle length is decreased to 300 ms [5-7].

The clinical and electrophysiologic features of a case of recurrent narrow-complex and wide-complex tachycardia on electrocardiogram (ECG), in a 17-year-old man, are presented. The features of Lown-Ganong-Levine syndrome are compared with those of EAVNC and included analysis of the AV nodal recovery curves obtained before and after adenosine challenge and cryoablation. The findings in this single case, including the short PR and AH interval, may be due to an accessory pathway connection from the atrium to the distal AV node (James fiber), rather than enhanced atrioventricular nodal conduction (EAVNC).

Case Report

A 17-year-old man presented to our institution with a history of recurrent narrow-complex and wide-complex tachycardia. A 12-lead electrocardiogram (ECG) (Figure 1) showed a short PR interval (0.10 sec), a normal QRS complex, and otherwise normal ECG intervals and voltages. A previous electrophysiologic study at 16 years-of-age demonstrated both antegrade and retrograde dual AV nodal pathways, with pacing-inducible slow and fast AV nodal re-entrant tachycardia. Extensive radiofrequency ablation of the proximal coronary sinus and the right posteroseptal tricuspid annulus area were unsuccessful at that time.

On his recent hospital admission, the electrophysiologic studies showed an extremely short baseline atrial to His (AH) conduction interval of 22 ms, and a normal His to ventricle (HV) interval, without a delta wave (Figure 2). Adenosine, 0.3 mg/kg intravenously (IV), did not change the AH interval. Rapid atrial pacing at cycle lengths of 330-300 ms showed stable 1:1 antegrade conduction and two steady AH intervals, indicating two conduction pathways: a conduction pathway with short AH, presumed to be a James fiber, and an AV nodal pathway with long AH. At pacing cycle length 280 ms with stable 1:1 AV conduction the PR interval was longer than the RR intervals, indicating the presence of antegrade dual AV nodal pathways (fast and slow AV nodal pathways). AV nodal Wenckebach block occurred at atrial pacing cycle length of 270 ms.

In atrial extra-stimuli, the AV nodal (AVN) conduction (A1A2-A2H2) recovery curves pre-James fiber ablation plot (Figure 2) showed that from A1A2 550-420 ms, there was a flat AH without decrement. When the A1A2 further decreased to 350 ms, A2H2 increased from 35-77 ms (with a decremental property).

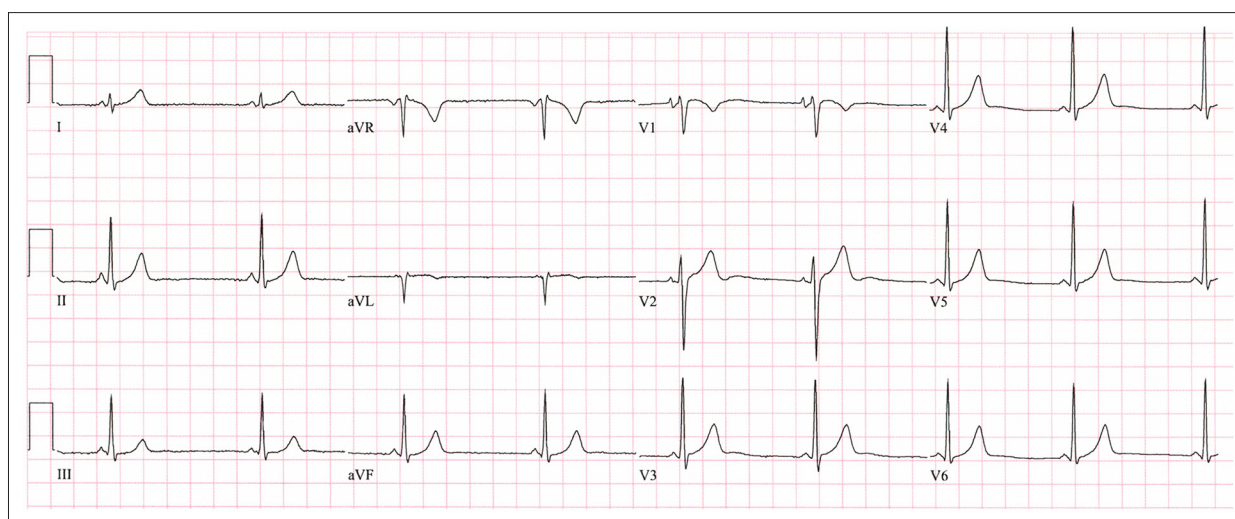


Figure 1. The findings of the 12-lead electrocardiogram (ECG) in a case of Lown-Ganong-Levine syndrome. The PR interval is 0.10 sec without evidence of a delta wave.

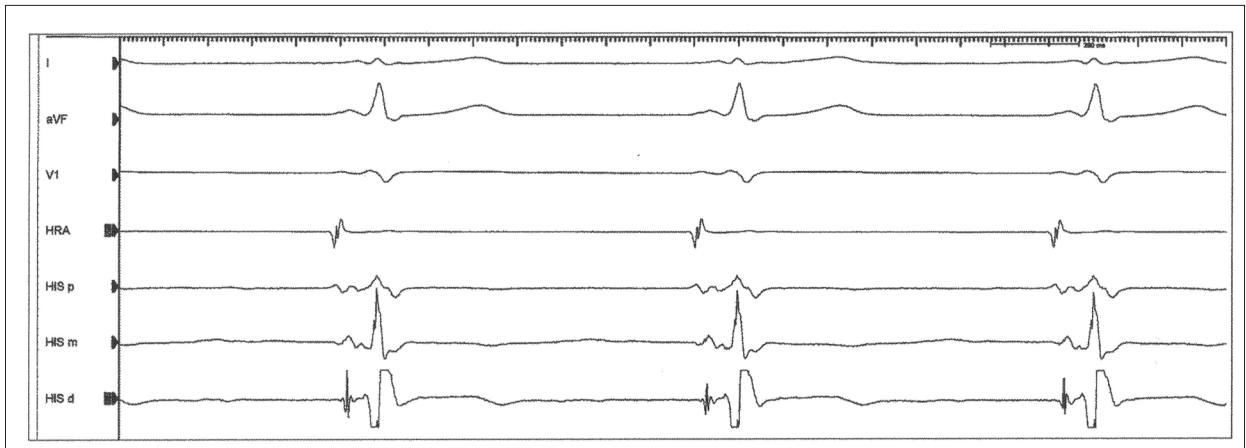


Figure 2. Surface and intracardiac electrocardiograms (ECGs) in a case of Low-Ganong-Levine syndrome. The ECG findings show the atrial to His (AH) conduction interval: 22 ms; His to ventricle (HV) interval: 41 ms; PR interval: 91 ms; and QRS complex: 88 ms.

When the A1A2 decreased from 350-340 ms, there was an A2H2 jump of 31 ms (from 77-118 ms). When A1A2 was further decreased, A2H2 gradually increased to 270 ms without a further jump.

The retrograde ventriculoatrial (VA) conduction had decremental properties. Ventricular pacing at a pacing cycle length of 600 ms showed a VA conduction of 120 ms with the earliest atrial depolarization at His bundle region. In ventricular extrastimuli, the VA conduction progressively lengthened to 181 ms, then jumped to 330 ms, with the earliest retrograde atrial conduction that shifted to the coronary sinus ostium, which induced a retrograde, slow-antegrade, fast AV nodal re-entry. With isoproterenol challenge, which is a sympathomimetic for beta-receptors, ventricular pacing induced a sustained fast-slow AV nodal reentrant tachycardia with an AH of 71 ms and HA of 180 ms and the earliest retrograde atrial depolarization was recorded at the area of the ostium of the coronary sinus.

A Freezor Xtra® ablation catheter (Medtronic, Kirkland, Québec, Canada) was used for mapping and cardiac ablation applied to the posterior septal area close to the coronary sinus. Catheter manipulation at the upper mid-septal area incidentally resulted in transient AH prolongation (mechanical ablation of the James fiber). Cryoablation at -80°C delivered to this site for 4 minutes, followed by an additional cryoablation of 22 seconds (which was stopped due to transient AV block) resulted in a normalized basic AH interval to 56 ms.

The A1A2-A2H2 plot post-James fiber ablation (Figure 3) showed that from A1A2 600 ms to 350 the A2H2 conduction curve had a decremental property, which was significantly different from that of the pre-ablation curve. From A1A2 340 to 170 the two recovery curves were superimposable, and this was presumed to be the James fiber effective refractory period. A repeat adenosine challenge, at the same dose, resulted

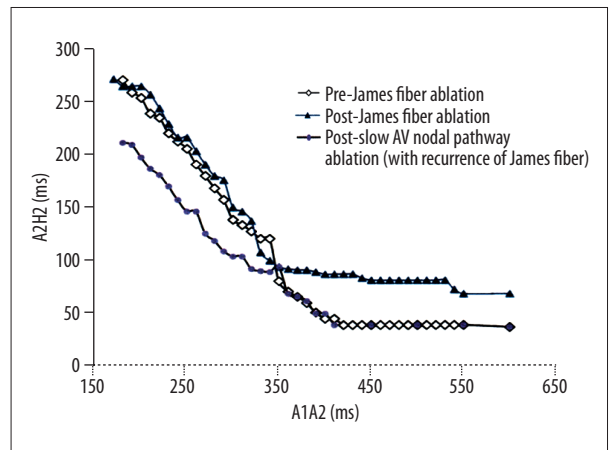


Figure 3. Atrioventricular (AV) nodal recovery curve plots in a case of Low-Ganong-Levine syndrome. Characterization of typical atrioventricular nodal reentrant tachycardia (AVNRT) with continuous AV nodal (AVN) conduction (A1A2-A2H2) curves before and after James fiber ablation, and post-retrograde slow AV nodal pathway ablation (with recurrence of the James fiber).

in transient AV conduction block. However, the James fiber conduction recurred with an intermittent short AH of 33 ms, which was longer than the baseline AH of 22 ms, and a long AH of 50 ms. Adenosine challenge of 0.3 mg/kg intravenously resulted in a paradoxical response of constant short AH of 33 ms with loss of the long AH interval.

Cryoablation commenced at the level of the mid-coronary sinus ostium and continued superiorly, finally eliminated the retrograde slow AV nodal pathway at the right lower midseptal area above the coronary sinus ostium. Post-ablation rapid atrial pacing resulted in a PR interval that was shorter than the RR interval before AV nodal Wenckebach block. The post-slow pathway ablation recovery curve, with recurrence of the James

fiber (Figure 3) showed the superimposable recovery curve from A1A2 600 to 350 ms compared with that of the pre-James fiber ablation curve. At A1A2 ≤ 340 ms, the James fiber effective refractory period, the recovery curve post-slow pathway ablation had a shorter A2H2 at the same A1A2 (downward displacement) compared with that of the pre-slow pathway ablation curve. There was no demonstrable retrograde slow AV nodal pathway conduction and no inducible AV nodal re-entry with or without isoproterenol challenge. At one-year follow-up, there was no clinical recurrence of tachycardia in this patient.

Discussion

In this case, the clinical and electrophysiologic characteristics were consistent with a diagnosis of Lown-Ganong-Levine syndrome, with a short PR interval, normal QRS complex, without a delta wave, and paroxysmal tachycardia. This case had the features described by James, as an accessory pathway connection from the atrium to the distal AV node [3]. The findings in this case included an unusually short atrium to His (AH) conduction interval and a normal His to ventricle (HV) conduction interval without a delta wave; two different stable AH intervals coexisted at the same atrial pacing cycle length; and in the A1A2-A2H2 recovery curve study, this pathway had a flat conduction curve without AH increase until the last 60 ms before reaching its effective refractory period. When decremental conduction occurred, this pathway showed no response to the adenosine challenge, and when this pathway became intermittent, there was a paradoxical response to adenosine challenge with conduction via a short AH instead of lengthening AH or conduction block. Finally, catheter ablation at the AV nodal region resulted in a normalized AH interval, normal decremental conduction, and resulted in a positive response to adenosine challenge.

In this case, since this pathway had some decremental properties, it is possible that the distal insertion site of this pathway was in the distal AV nodal area (James fiber) rather than connecting via the atria and the His bundle (Brechenmacher fiber) [3,4].

The James fiber in this patient appeared to be a bystander, which was not a tachycardia substrate. The clinical fast and slow AV nodal re-entrant tachycardia utilized an antegrade normal AV nodal pathway and a retrograde slow AV nodal pathway. Therefore, after the James fiber recurrence, further ablation was not pursued. Instead, the retrograde slow AV nodal pathway was eventually ablated successfully at the right lower mid septal area above the coronary sinus ostium.

When comparing the pre- and post-James fiber ablation A1A2-A2H2 recovery curves, the former had a faster conduction (shorter AH), a reduced decremental conduction property (an

unchanged A2H2 until A1A2 ≤ 410 ms, and then the A2H2 started to lengthen), and a longer effective refractory period. When the James fiber became refractory (at A1A2 of 340 ms), the conduction continued through the AV nodal pathway with similar pre- and post-ablation curves, that were almost superimposable.

Comparison of the post-James fiber ablation recovery curve with that of the post-slow pathway ablation curve with James fiber recurrence, it was noted that when the A1A2 was less than 350 ms, the post-slow pathway ablation curve (fast AV nodal conduction curve) deviated downward from that of the pre-James fiber ablation curve (slow pathway conduction curve). Therefore, the pre-James fiber ablation curve was a hybrid of a James fiber and a slow AV nodal pathway conduction curve; the post-James fiber ablation curve was a hybrid of fast and slow AV nodal conduction curve, and the post-slow pathway ablation curve was a hybrid of the James fiber and fast AV nodal conduction curve.

This case also fulfilled the diagnosis criteria of enhanced atrioventricular nodal conduction (EAVNC), which requires the presence of a short AH interval (≤ 60 ms) during sinus rhythm, and intact AV sequential conduction to short atrial paced cycle length (≤ 300 ms), and a small increment (≤ 100 ms) in the AH interval as the atrial cycle length decreased to 300 ms [5-7]. The diagnosis of EAVNC implies that the underlying pathology is due to a distal atrial insertion to the AV node or the fast pathway input to the AV node interposed by less AV nodal tissue than normal, before entering the His bundle. If this were the case, when this EAVNC was injured during catheter manipulation and by catheter ablation (with intermittent AH prolongation), adenosine should have resulted in a further lengthening of the AH or caused AV block. Instead, the normal AV nodal pathway was blocked, resulting in the paradoxical response of constant short AH intervals.

The differential diagnosis between the small AV node showing properties of EAVNC and the presence of the anatomically independent James fiber can be quite difficult. If the James fiber had retrograde AV conduction, it would have been possible to also evaluate the anatomical difference in the atrial insertion site between the James fiber and the fast AV nodal pathway. Unfortunately, this case showed no evidence of retrograde AV conduction through the James fiber.

Tachycardia is one of the features of Lown-Ganong-Levine syndrome. However, in our case, the patient's tachycardia was caused by a slow AV nodal pathway, and the James fiber appeared to be a bystander for this effect. Similar to Wolff-Parkinson-White syndrome, Lown-Ganong-Levine syndrome can result in serious cardiac arrhythmias, atrial fibrillation, several syncope episodes, and even sudden death [2].

In 2001, a clinical study of children and young adults included 273 cases of sudden death, in which out of ten cases of ventricular pre-excitation (3.6%; mean age, 24 years) there were eight cases of Wolff-Parkinson-White syndrome (short PR interval, wide QRS, and a delta wave) and two cases of Lown-Ganong-Levine syndrome (short PR interval and normal QRS complexes) [8]. In the two cases of Lown-Ganong-Levine syndrome, one case had a hypoplastic atrioventricular node, likely to have been caused by EAVNC, and the other had Brechenmacher fibers (atrio-Hisian tracts); of the cases of Wolff-Parkinson-White syndrome, sudden cardiac death was related to a very short antegrade effective refractory period of the accessory pathway [8].

Since the tachycardia in this case was caused by fast and slow AV nodal re-entrant tachycardia and the antegrade effective refractory period of the James fiber was relatively long (340 ms), in retrospect, there may have been no need to ablate the James fiber in this case. However, attempted cryoablation of the James fiber proved its presence. Since the James

fiber is close to the normal AV nodal tissue, cryoablation, with its reversibility in case of an adverse event of AV block, should be used if necessary.

Conclusions

This single case report is of Lown-Ganong-Levine syndrome associated with accessory pathway (James fiber) conduction, but this single case does not attempt to apply this finding to the cause in all cases of this syndrome. With the increasing use of the cardiac electrophysiologic studies and catheter ablation in the evaluation of patients with cardiac pre-excitation syndromes, it is likely that more cases of Lown-Ganong-Levine syndrome will be studied. An awareness of the clinical and electrophysiologic features of Lown-Ganong-Levine syndrome will assist the cardiologist and electrophysiologist in making the correct diagnosis and may add further insight into the pathophysiology of this syndrome.

References:

1. Clerc A, Levy R, Critesco C: A propos du raccourcissement permanent de l'espace P-R de l'électrocardiogramme: sans déformation du complexe ventriculaire (About the permanent shortening of the P-R interval on the electrocardiogram: Without deformation of the ventricular complex). *Arch Mal Coeur*, 1938; 31: 569–82
2. Lown B, Ganong WF, Levine SA: The syndrome of short PR interval, narrow QRS complex and paroxysmal rapid heart action. *Circulation* 1952; 5: 693–706
3. James TN: Morphology of the human atrioventricular node, with remarks pertinent to its electrophysiology. *Am Heart J*, 1961; 62: 756–71
4. Brechenmacher C: Atrio-His bundle tracts. *Brit Heart J*, 1975; 37: 853–855
5. Bauernfeind RA, Swiryn S, Strasberg B et al: Analysis of anterograde and retrograde fast pathway properties in patients with dual atrioventricular nodal pathways. Observations regarding the pathophysiology of the Lown-Ganong-Levine syndrome. *Am J Cardiol*, 1982; 49(2): 283–90
6. Dougherty A, Naccarelli G: Characteristics of ventriculoatrial conduction in patients with enhanced atrioventricular nodal conduction. *Pacing Clin Electrophysiol*, 1987; 10(1 Pt 1): 32–40
7. Benditt DG, Pritchett LC, Smith WM et al: Characteristics of atrioventricular conduction and the spectrum of arrhythmias in Lown-Ganong-Levine syndrome. *Circulation*, 1978; 57: 454–65
8. Basso C, Corrado D, Rossi L, Thiene G: Ventricular pre-excitation in children and young adults. Atrial myocarditis as a possible trigger of sudden death. *Circulation*, 2001; 103: 269–75