

## Case Report



# Treatment of Extensive Spinal Epidural Abscess with Skipped Laminotomy Using a Pediatric Feeding Tube: A Case Report

Chang Yub Kim , Pius Kim , Chang Il Ju , and Seok Won Kim

Department of Neurosurgery, College of Medicine, Chosun University, Gwangju, Korea

## OPEN ACCESS

Received: Apr 20, 2021

Revised: Jun 28, 2021

Accepted: Jun 30, 2021

### Address for correspondence:

Seok Won Kim

Department of Neurosurgery, College of Medicine, Chosun University, 365 Pilmun-daero, Dong-gu, Gwangju, 61453, Korea.  
E-mail: chosunns@chosun.ac.kr

Copyright © 2021 Korean Neurotraumatology Society

This is an Open Access article distributed under the terms of the Creative Commons Attribution Non-Commercial License (<https://creativecommons.org/licenses/by-nc/4.0/>) which permits unrestricted non-commercial use, distribution, and reproduction in any medium, provided the original work is properly cited.

### ORCID iDs

Chang Yub Kim

<https://orcid.org/0000-0001-6970-2527>

Pius Kim

<https://orcid.org/0000-0001-5514-9257>

Chang Il Ju

<https://orcid.org/0000-0001-9123-2808>

Seok Won Kim

<https://orcid.org/0000-0002-1910-0242>

### Conflict of Interest

The authors have no financial conflicts of interest.

## ABSTRACT

Spinal epidural abscess (SEA) is an unusual form of spinal infection. Performing multilevel laminectomies is controversial in cases of extensive SEA considering the long surgical time and mechanical instability. Here, we report the case of an older woman with extensive SEA and poor general condition who was successfully treated with a less invasive treatment, namely skipped laminotomy using a pediatric feeding tube. A 79-year-old woman complained of progressive weakness in both legs, fever, and back pain. An extensive epidural abscess from the T3 to L5 vertebrae was observed on thoracic and lumbar magnetic resonance imaging (MRI). We performed skipped laminotomy at the T8 and T12 levels, and a 5-Fr pediatric feeding tube was advanced from the caudal level toward the rostral area and rostral level toward caudal level into the dorsal epidural space. Subsequently, regurgitation was performed with saline through the pediatric feeding tube at each level. Following this, to further irrigate the unexposed epidural abscess through laminotomy, the epidural space was washed by continuous irrigation, and the irrigation system was maintained for 48 hours. Follow-up MRI performed 3 weeks after the procedure confirmed near complete removal of the abscess in the thoracic spine, with a small residual abscess in the lumbar spine.

**Keywords:** Epidural abscess; Laminotomy; Irrigation

## INTRODUCTION

Spinal epidural abscess (SEA) is an unusual form of spinal infection that causes significant morbidity and mortality.<sup>6)</sup> Early diagnosis and surgical drainage with antimicrobial treatment are essential for reducing the rate of mortality from SEA.

Extensive SEAs have been described, but they are rare and pose a therapeutic challenge as they have a higher mortality rate.<sup>1,2)</sup> SEA localized to one region of the spine is amenable to surgical drainage through simple 1- or 2- level laminectomy or laminotomy; however, extensive SEA require more extensive laminectomies, even in patients with poor general conditions. Few authors have indicated that these patients should not be treated surgically. However, open surgery is not considered for multilevel laminectomies when a patient's general condition is poor. Moreover, decompression with laminectomies involving multiple

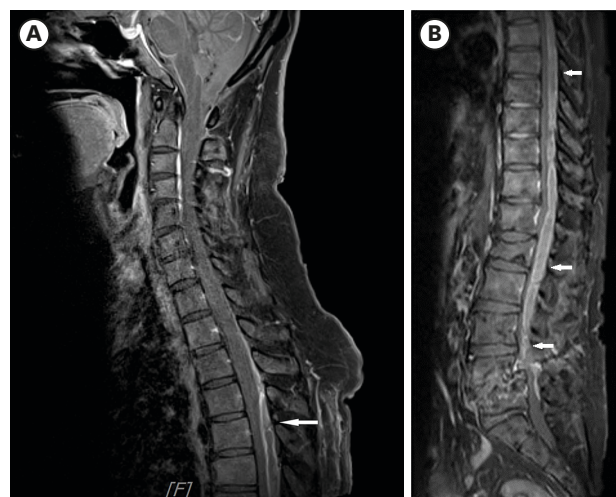
levels may lead to mechanical instability and require a long surgical time. Hence, we have reported a case of an extensive SEA from T5 to L5 that was treated surgically with skipped laminotomy using a pediatric feeding tube and an irrigation system.

## CASE REPORT

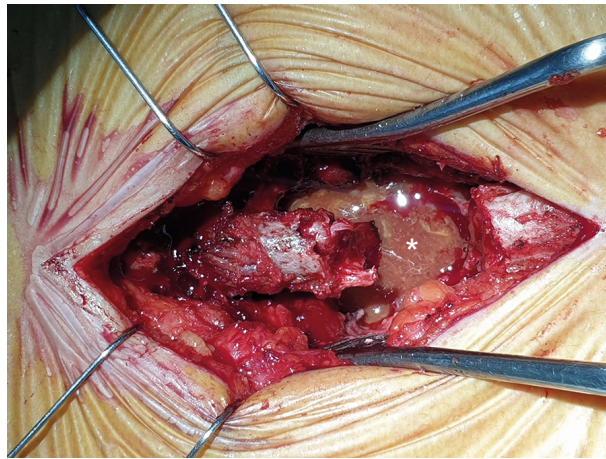
A 79-year-old woman (height: 158 cm and weight: 65 kg) visited the emergency room with bilateral leg motor weakness (grade 4/4) and back pain. All her vital signs were stable; however, she had mild fever (37.9°C). She had a medical history rheumatoid arthritis and type 2 diabetes mellitus.

She had previously undergone acupuncture or epidural blocks in the lumbar region occasionally at a local pain clinic. Blood test results showed a markedly elevated white cell count of 14,360 cells/mm<sup>3</sup>, a C-reactive protein level of 7.57 mg/dL, and an erythrocyte sedimentation rate of 83 mm/h. Magnetic resonance imaging (MRI) of the entire spine revealed dorsal compression of the spinal cord and cauda equina by an epidural abscess extending from the apex of T3 to L5 (**FIGURE 1**).


Two separate midline incisions were made over the T8-T9 and T12-L1 areas. We performed bilateral laminotomy at T8 and T12. On the laminotomy at each level, yellowish pus was gushed out (**FIGURE 2**), and swabs were sent for culture. A 5-Fr pediatric feeding tube (**FIGURE 3**) was advanced from the laminotomy level superiorly and then inferiorly into the dorsal epidural space, and vancomycin mixed with saline was irrigated through the pediatric feeding tube, resulting in further irrigation of portions of the epidural abscess not exposed via laminotomy. Two inflow irrigation tips (Hemovac pp 400 mL, 1.6 mm) were inserted into the epidural space, and 2 outflow tips (Hemovac ps 400 L, 2.8 mm) were inserted in each epidural space (**FIGURE 4**). The irrigation system was maintained for 48 h, and when the color of the outflow was clear, it removed to prevent secondary infection. The pus culture revealed methicillin-resistant *Staphylococcus aureus* (MRSA) as the causative agent. The patient was initiated on intravenous vancomycin. Blood cultures also showed MRSA positivity; therefore, she was transferred to infection internal medicine department for further



**FIGURE 1.** (A, B) Gadolinium-enhanced magnetic resonance images showing an extensive epidural abscess (arrows) from T3 to L5.



**FIGURE 2.** Yellowish pus (asterisk) after removal of the yellow ligament after T12 laminotomy.



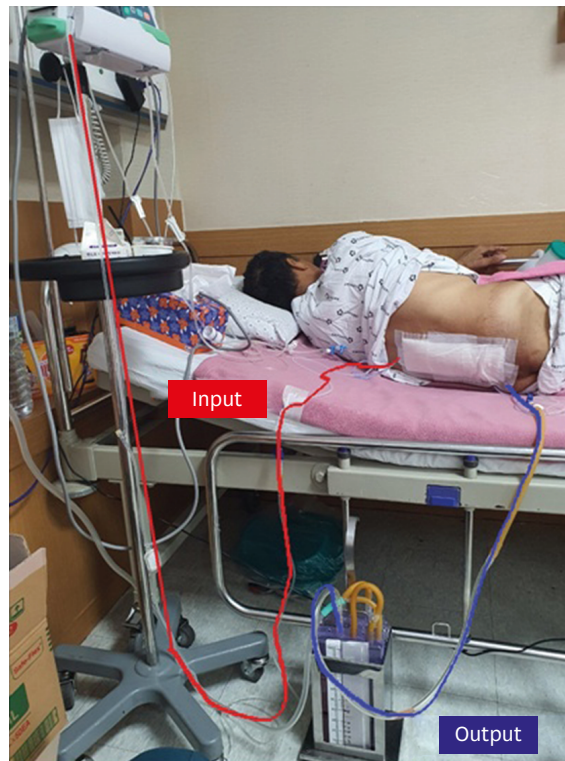**FIGURE 3.** 5-Fr pediatric feeding tube.

antibiotic treatment. Follow-up MRI performed 21 days after surgery showed that the abscess in the thoracic spine was completely removed, with a small residual abscess in the lumbar spine (**FIGURE 5**). After 3 months of follow-up, the motor strength of both lower extremities improved (G5/G5), and she could walk without any assistance.

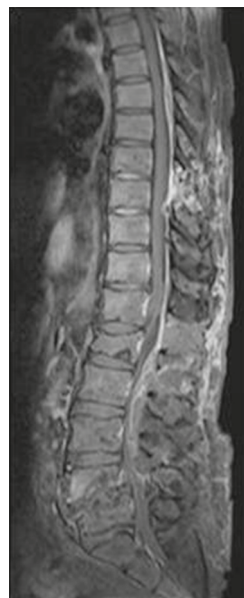
## DISCUSSION

SEA is an uncommon but severe infectious condition that may lead to significant neurological disability and death.<sup>7)</sup> It classically manifests as a triad of fever, back pain, and progressive neurological deficits. The route of infection is hematogenous spread of bacteria or a direct extension of osteomyelitis into the spinal canals. Recently, the incidence of SEA has increased, possibly because of the increase in the aging population; the prevalence of diabetes; and the use of instrumentation, epidural catheters, and immunosuppressive therapy.

Prompt diagnosis and surgical drainage should be instituted because diagnostic delay is associated with poor outcomes and catastrophic consequences.<sup>9)</sup>



**FIGURE 4.** Clinical application of irrigation system.



**FIGURE 5.** Gadolinium-enhanced magnetic resonance image after 21 days of skipped laminotomy. The abscess of the thoracic spine has almost disappeared and the volume of the epidural abscess in the lumbar spine has markedly decreased.

In cases of extensive SEA involving multiple levels, spine surgeons hesitate to perform surgical decompression and drainage through multilevel laminectomies for patients with poor general conditions. These cases represent a treatment dilemma, especially for patients with medical comorbidities.

Performing multilevel laminectomies may predispose patients to complications such as increased blood loss, cardiac and respiratory difficulties, increased postoperative pain and recovery time, and late kyphotic deformity and iatrogenic instability.<sup>4,5)</sup> There have only been a few cases of extensive SEA involving more than five vertebral levels.

Among them, some case reports have shown successful resolution of extensive SEAs involving more than five vertebral bodies with conservative antibiotics alone.<sup>8,12)</sup> Recently, Ran et al.<sup>10)</sup> introduced the concepts of aspiration and irrigation of multilevel SEA by percutaneous CT-guided needle aspiration. However, in clinical practice, CT-guided percutaneous drainage of SEA is not commonly performed due to technical difficulties; it is only indicated for a dorsally located SEA with a confirmed purely liquid component.

Surgical drainage should be promptly considered for patients with neurological deficits because of the limited time window for irreversible damage. Most authors prefer surgical decompression and abscess drainage because the progression of infection is unpredictable even if appropriate antibiotic therapy is established, and severe neurological compromise can follow vascular involvement of the spinal cord.<sup>11)</sup> Ahuja et al.<sup>2)</sup> reported a novel technique of interval laminectomy at two sites in the thoracic spine and drainage with the help of infant feeding tubes in a case of holocord SEA.

Our patient was treated successfully with skipped laminotomy using an irrigation system for the drainage of pus. The use of a less rigid but flexible 5-Fr pediatric feeding tube allows for high-flow irrigation, which enables the navigation of the curvature of the spine and epidural space with minimal pressure of the spinal cord. We performed less invasive skipped laminotomy at only two sites, and irrigation was performed to remove the abscess.

We attempted to prevent instability and kyphosis by performing the surgeries with a minimal skipped segment. Skipped laminotomy can be performed, and the abscess can be removed through continuous irrigation, even in cases of extensive SEA.<sup>1)</sup>

Even if sufficient irrigation and debridement are performed through surgery, appropriate antibiotic treatment for 4–12 weeks is essential.<sup>3)</sup>

## CONCLUSION

For extensive SEA, skipped laminotomy using a 5-Fr pediatric feeding tube and an irrigation system is less invasive. It can reduce the surgical time and the risk of mechanical instability compared to multilevel laminectomies.

## REFERENCES

1. Abd-El-Barr MM, Bi WL, Bahluyen B, Rodriguez ST, Groff MW, Chi JH. Extensive spinal epidural abscess treated with “apical laminectomies” and irrigation of the epidural space: report of 2 cases. *J Neurosurg Spine* 22:318-323, 2015  
[PUBMED](#) | [CROSSREF](#)
2. Ahuja K, Das L, Jain A, Meena PK, Arora SS, Kandwal P. Spinal holocord epidural abscess evacuated with double thoracic interval laminectomy: a rare case report with literature review. *Spinal Cord Ser Cases* 5:62, 2019  
[PUBMED](#) | [CROSSREF](#)

3. Bluman EM, Palumbo MA, Lucas PR. Spinal epidural abscess in adults. *J Am Acad Orthop Surg* 12:155-163, 2004  
[PUBMED](#) | [CROSSREF](#)
4. Duc C, Grange L, Gaudin P, Brun F, Terki RK, Barbier LP, et al. Extensive primary epidural abscess. Report of a case. *Joint Bone Spine* 69:312-315, 2002  
[PUBMED](#) | [CROSSREF](#)
5. Eismont FJ, Bohlman HH, Soni PL, Goldberg VM, Freehafer AA. Pyogenic and fungal vertebral osteomyelitis with paralysis. *J Bone Joint Surg Am* 65:19-29, 1983  
[PUBMED](#) | [CROSSREF](#)
6. Khanna RK, Malik GM, Rock JP, Rosenblum ML. Spinal epidural abscess: evaluation of factors influencing outcome. *Neurosurgery* 39:958-964, 1996  
[PUBMED](#)
7. Nussbaum ES, Rigamonti D, Standiford H, Numaguchi Y, Wolf AL, Robinson WL. Spinal epidural abscess: a report of 40 cases and review. *Surg Neurol* 38:225-231, 1992  
[PUBMED](#) | [CROSSREF](#)
8. O'Brien C, Lenehan B, Street J. Non-operative management of an extensive anteriorly located epidural abscess. *J Clin Neurosci* 18:1401-1402, 2011  
[PUBMED](#) | [CROSSREF](#)
9. Panagiotopoulos V, Konstantinou D, Solomou E, Panagiotopoulos E, Marangos M, Maraziotis T. Extended cervicolumbar spinal epidural abscess associated with paraparesis successfully decompressed using a minimally invasive technique. *Spine* 29:E300-E303, 2004  
[PUBMED](#) | [CROSSREF](#)
10. Ran B, Chen X, Zhong Q, Fu M, Wei J. CT-guided minimally invasive treatment for an extensive spinal epidural abscess: a case report and literature review. *Eur Spine J* 27 Suppl 3:380-385, 2018  
[PUBMED](#) | [CROSSREF](#)
11. Schultz KD Jr, Comey CH, Haid RW Jr. Technical note. Pyogenic spinal epidural abscess: a minimally invasive technique for multisegmental decompression. *J Spinal Disord* 14:546-549, 2001  
[PUBMED](#) | [CROSSREF](#)
12. Van Bergen J, Plazier M, Baets J, Simons PJ. An extensive spinal epidural abscess successfully treated conservatively. *J Neurol Neurosurg Psychiatry* 80:351-353, 2009  
[PUBMED](#) | [CROSSREF](#)