

# Feasibility of renal transplantation after unroofing of a large renal cyst in an expanded criteria donor

Prashanth Kanagarajah<sup>1</sup>, Obi Ekwenna, Rajinikanth Ayyathurai, George W. Burk III<sup>2</sup>, Gaetano Ciancio<sup>2</sup>

Department of Urology, University of Miami, <sup>1</sup>Bladder Health and Reconstructive Urology Institute, Miramar,

<sup>2</sup>Department of Transplant Surgery, University of Miami, FL, USA

## Abstract

We present a case in which a deceased donor kidney with a large simple cyst was successfully unroofed and transplanted to a 61-year-old male. The donor was a 62-year-old male with a history of hypertension for 2 years; cerebral vascular accident was the cause of death. A large 8-cm cyst distorting the renal hilum was identified upon the procurement of the deceased donor kidney. Prior to transplantation, the large cyst was unroofed from the allograft; the frozen section confirmed a benign cyst and the transplant was performed. Postoperatively, the serum creatinine level was 1.4 mg/ml at 22-month follow-up and the patient was normotensive. Deceased donor kidneys with giant cysts distorting the renal hilum can be effectively transplanted.

**Key Words:** Expanded criteria donor, hemodialysis, kidney transplant, unroofing renal cyst

## Address for correspondence:

Prof. Gaetano Ciancio, MD 1150 NW 14 Street, Suite 309 Miami, Florida 33136, USA. E-mail: gciancio@med.miami.edu

Received: 31.08.2011, Accepted: 11.12.2011

## INTRODUCTION

Despite the increase in total kidney transplantation, the number of individuals on the waiting list continues to trump the availability of organs. Due to the imbalance of supply and demand for organs for kidney transplantation, there has been an increase in recent years in the use of expanded criteria donors (ECDs) who are donors (1) >65 years or <5 years of age and (2) >55 years of age with one or two of the following: (a) >10-year history of diabetes or hypertension, (b) cerebrovascular accident as the cause of death, and (c) a serum creatinine level  $\geq 1.5$  mg/dl.<sup>[1,2]</sup> The incidence of simple cysts increases with age, with a 25%-40% reported incidence in patients older than 50 years. The size of cysts varies with age, with larger cysts found in the older

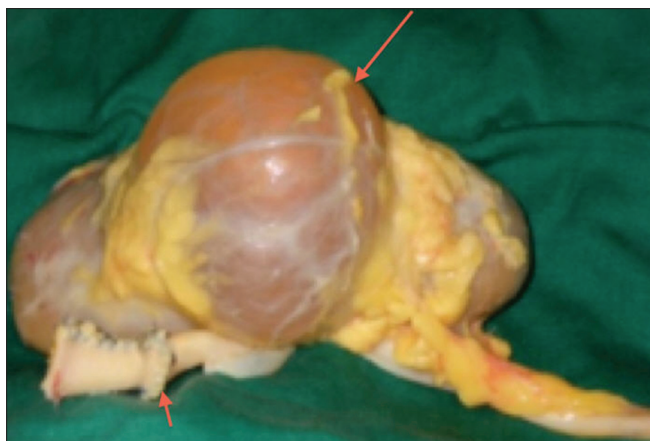population. Therefore, with ECDs there exists a moderate to high possibility of encountering simple renal cysts which may complicate the transplant procedure. We report our experience in which an expanded criteria donor with a large 8-cm renal cyst distorting the renal hilum was successfully transplanted after unroofing the cyst. The anatomic abnormality presented in this report is unique, and could have resulted in discard of this graft.

## CASE REPORT

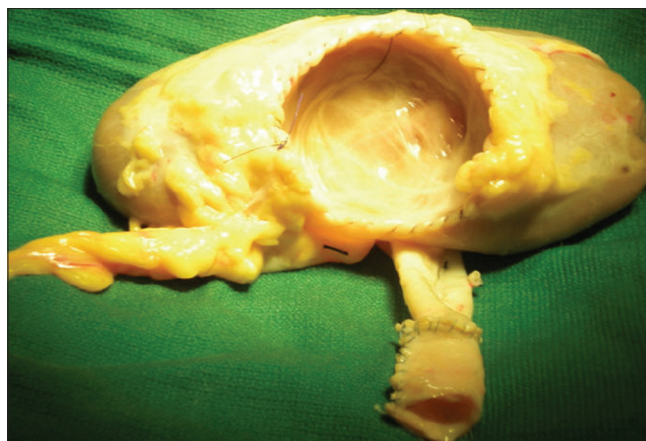
The patient was a 61-year-old male with a history of high blood pressure, who subsequently developed renal failure, and had been undergoing hemodialysis for 3 years before he received a renal transplant. The deceased donor was a 62-year-old male with a 2-year history of hypertension, and cerebrovascular accident was the cause of death. The deceased donor kidney was noted to have a large cyst abutting the main renal artery [Figure 1].

The allograft essentially met the expanded criteria for renal transplantation.<sup>[1,2]</sup> There was a I-antigen match in the HLA-DR locus. T and B-lymphocyte crossmatches were negative. The allograft was then prepared for transplantation;

Access this article online	
Quick Response Code:	Website: www.urologyannals.com
	DOI: 10.4103/0974-7796.115755



**Figure 1:** Large simple cyst in the deceased donor kidney



**Figure 2:** Deceased donor kidney after unroofing of the large simple cyst

the large cyst was unroofed [Figure 2]. The frozen section revealed a benign simple cyst. The graft kidney weighed 340 g with very mild arteriosclerosis and fibrosis, and 3% glomerulosclerosis. The edges were oversewn with a 4-0 PDS suture material; Evicel™ was applied to the base, and the two biopsy sites were oversewn with 5-0 Prolene sutures. The allograft was then transplanted in the usual fashion uneventfully: the renal artery to the external iliac artery and the vein to the external iliac vein.

The patient was induced with thymoglobulin and daclizumab. Thymoglobulin (1 mg/kg) was given intraoperatively, with similar additional postoperative doses on days 3 and 5. The first dose of daclizumab (1 mg/kg) was also given intraoperatively, with one additional dose 14 days later. Tacrolimus was initiated at a dose of 0.1 mg/kg twice daily after the renal function had improved, i.e. the serum creatinine concentration decreased to <4 mg/dl in the absence of dialysis. The target (12 h) trough level of tacrolimus was 4-6 ng/ml. The target mycophenolatemofetil dose was 1 g twice daily. Methylprednisolone was given intravenously at 500 mg per day for 3 days postoperatively, with subsequent weaning to complete withdrawal after the first postoperative week; steroid avoidance.<sup>[3]</sup>

The postoperative course was uneventful. The patient was discharged with excellent urine out, and at 22 months, the serum creatinine level was 1.4 mg/dl.

## DISCUSSION

It is well established that despite poorer outcomes using ECDs, mortality is decreased with transplantation compared with dialysis therapy in patients with end-stage renal disease.<sup>[4]</sup> In a recent study comparing dialysis to transplantation in elderly patients, survival at 5 years was 31% in the wait-list group and 49% in the transplant group.<sup>[5]</sup> The cost and survival benefit of renal transplantation is now well established in the literature and is advocated whenever possible.

Some authors have presented data suggesting comparable results in outcomes in ECDs versus standard criteria donors (SCDs).<sup>[6]</sup> The evaluation of graft survival, graft function, serum creatinine, cost, acute rejection and infection complications, including patient survival, showed no significant differences in patients receiving ECD and SCD grafts.<sup>[6]</sup>

The use of kidneys with cysts has been described in the literature with good post-transplantation outcomes.<sup>[7,8]</sup> Most authors describe the decortication of simple cysts in mostly standard criteria donor grafts for small-to-medium-sized simple cysts. In this case report, we describe the unroofing of a large benign cyst in a deceased donor kidney (ECD) with compression of the renal hilum, and subsequent successful transplantation. The anatomic variety (abnormality) presented here is unique, and could have resulted in discard of this graft. With short-term follow-up (22 months), the graft is functioning well, and serves as an excellent alternative to dialysis.

Although there has been a yearly increase in the number of kidney transplantation performed, the demand and supply for kidneys continues to be a major problem in transplantation.<sup>[1]</sup> Due to this shortage of available donor kidneys, the need for full utility of ECDs continues to draw close interest. According to reports, the alarming rate of discard of recovered organs is mostly because of the increase in the number of donors older than 50, who now represent over 30% of the national donor population.<sup>[9]</sup> It is well described that the incidence of simple cysts increases with age, with a 25%-40% incidence in 50 year olds.<sup>[10]</sup> The size of cysts varies with age, with larger cysts found in the older population. Therefore, a high percentage of ECDs will harbor a cyst; this finding should not preclude the recovered graft from transplantation.

Surgical deroofting of renal cysts has a very high success rate (95%-100%).<sup>[11]</sup> Cosmesis, shorter recovery, and less postoperative pain are advantages of minimal access surgery.

With the advent of robot-assisted surgery, and single port, single incision, natural orifice surgical options for the treatment of renal cysts, open surgery is not commonly performed. A direct approach to the kidney without the need to mobilize the colon, closer proximity to the conventional open approach, and avoidance of spillage into the peritoneum are significant advantages offered by the retroperitoneal approach over the transperitoneal approach.<sup>[11]</sup> Porpiglia *et al.* prospectively compared retroperitoneal decortications of simple renal cysts and decortications with wadding using perirenal fat. They concluded that decortication with wadding offers maximum safety and prevent recurrences compared to decortications alone.<sup>[12]</sup> Long-term follow-up confirms decortication to be a safe and effective treatment option. In all patients, upon identifying the cyst, the exophytic wall should be opened and the cystic cavity should be thoroughly examined to exclude the presence of neoplastic changes, and if no lesions are identified, the fluid should be aspirated for cytological analysis and the decorticated cyst should be subjected to histopathological analysis to exclude malignancy.<sup>[12]</sup>

It is our conclusion that potential allografts with large benign cysts should be given strong consideration for transplantation. The cyst should be excised, with the frozen section performed with proof of benign nature, and appropriate reconstruction prior to the induction of recipient and transplantation.

## REFERENCES

- Pascual J, Zamora J, Pirsch JD. A systematic review of kidney transplantation from expanded criteria donors. *Am J Kidney Dis* 2008;52:553-86.
- Metzger RA, Delmonico FL, Feng S, Port FK, Wynn JJ, Merion, RM. Expanded criteria donors for kidney transplantation. *Am J Transplant* 2003;3:114-25.
- Ciancio G, Burke GW, Gaynor JJ, Roth D, Sageshima J, Kupin W, *et al.* Randomized trial of mycophenolatemofetil versus enteric-coated mycophenolate sodium in primary renal transplant recipients given tacrolimus and daclizumab/thymoglobulin: One year follow-up. *Transplantation* 2008;86:67-74.
- Wolfe RA, Ashby VB, Milford EL, Ojo AO, Ettenger RE, Agodoa LY, *et al.* Comparison of mortality in all patients on dialysis, patients on dialysis awaiting transplantation and recipients of a first cadaveric transplant. *N Engl J Med* 1999;341:1725-30.
- World Congress of Nephrology 2009: A Joint Meeting of the European Renal Association-European Dialysis and Transplant Association (ERA-EDTA) and the International Society of Nephrology (ISN): Abstracts Sa719 and SU702. Presented May 24 and 25, 2009.
- Stratta RJ, Rohr MS, Sundberg AK, Armstrong G, Hairston G, Hartmann E, *et al.* Increased kidney transplantation utilizing expanded criteria deceased organ donors with results comparable to standard criteria donor transplant. *Ann Surg* 2004;239:688-95.
- Schulak JA, Matthews LA, Hricik DE. Renal transplantation using a kidney with a large benign cyst. *Transplantation* 1997;63:783-5.
- Srivastava A, Kumar A, Agarwal A. Donors with Renal Cysts: Adilemma in decision making. *Transplant Proc* 2003;35:30-1.
- Cho YW, Shah T, Cho ES, Stadler M, Simmons V, Mone T, *et al.* Factors associated with discard of recovered kidneys. *Transplant Proc* 2008;40:1032-4.
- Terada N, Ichioka K, Matsuta Y, Okubo K, Yoshimura K, Arai Y. The natural history of simple renal cysts. *J Urol* 2002;167:21-3.
- Hemal AK. Laparoscopic management of renal cystic disease. *Urol Clin North Am* 2001;28:115-26.
- Porpiglia F, Fiori C, Billia M, Renard J, Di Stasio A, Vaccino D, *et al.* Retroperitoneal decortication of simple renal cysts vs decortication with wadding using perirenal fat tissue: results of a prospective randomized trial. *BJU Int* 2009;103:1532-6.

**How to cite this article:** Kanagarajah P, Ekwenna O, Ayyathurai R, Burk GW, Ciancio G. Feasibility of renal transplantation after unroofing of a large renal cyst in an expanded criteria donor. *Urol Ann* 2013;5:206-8.

**Source of Support:** Nil, **Conflict of Interest:** None.