

## CASE REPORT

# Fibrosarcoma of maxilla: A rare case report

Sandhya Shrivastava, Sushruth K Nayak, Prachi Nayak, Sourabh Sahu<sup>1</sup>

Department of Oral Pathology and Microbiology, Chhattisgarh Dental College and Research Institute, Rajnandgaon, <sup>1</sup>Department of Oral Pathology and Microbiology, Government Dental College, Raipur, Chhattisgarh, India

## Address for correspondence:

Dr. Sourabh Sahu,  
Idgah Bhata, Behind Sahu Bhavan,  
Raipur - 492 001, Chhattisgarh, India.  
E-mail: sourabh218@gmail.com

Received: 04-09-2014

Accepted: 11-03-2016

## ABSTRACT

Fibrosarcoma is a malignant tumor of fibroblasts. At one time, it was considered one of the most common soft tissue sarcomas. However, the diagnosis of fibrosarcoma is made much less frequently today because of the recognition and separate classification of other spindle cell lesions that have similar microscopic features. Of all the fibrosarcomas occurring in humans, only 0.05% occur in the head and neck region. Here, we present a case of 22-year-old female patient with the swelling on the left anterior aspect of the face. Histopathologically, the lesion was diagnosed as fibrosarcoma and immunohistochemically, the lesional cells showed positivity for vimentin.

**Key words:** Fibrosarcoma, maxilla, soft tissue sarcoma

## INTRODUCTION

Fibrosarcoma is a tumor of mesenchymal cell origin that is composed of malignant fibroblasts in a collagenous background. It can occur as a soft tissue mass or as a primary or secondary bone tumor. The sarcomas as a group differ from malignant epithelial neoplasms by their typical occurrence in relatively younger persons.

Two main types of fibrosarcoma of bone exist, primary and secondary. Primary fibrosarcoma is a fibroblastic malignancy that produces variable amounts of collagen. It is central, arising within the medullary canal or peripheral, arising from the periosteum. Secondary fibrosarcoma of bone arises from a preexisting lesion or after radiotherapy to an area of bone or soft tissue. This is a more aggressive tumor with poorer prognosis. Fibrosarcoma, like other soft tissue sarcomas, has no definite cause.

Several inherited syndromes such as multiple neurofibromas may have a 10% risk over a lifetime of developing a malignant peripheral nerve sheath tumor or fibrosarcoma. Fibrosarcoma also has been noted to arise from preexisting lesion such as fibrous dysplasia, chronic osteomyelitis, bone infarcts, Paget's disease and in previously irradiated areas of bone.<sup>[1]</sup>

Clinically, fibrosarcomas most often present as slow-growing masses that may reach considerable size before they produce pain. Histologically, well-differentiated fibrosarcomas consist of fascicles of spindle-shaped cells that classically form a "herringbone pattern." The cells often show little variation in size and shape although variable numbers of mitotic figures can usually be identified. In poorly differentiated tumors, the cells are less organized and may appear rounder or ovoid. Mild pleomorphism along with more frequent mitotic activity may be seen.<sup>[2]</sup> The histological appearance of high-grade fibrosarcoma may be similar to other tumors such as malignant fibrous histiocytoma, liposarcoma or synovial sarcoma. The positive immunostaining for vimentin, together with negativity for muscular immunomarkers, helps in diagnosing fibrosarcoma. The treatment of choice is radical surgery; radiation therapy and chemotherapy can be used in inoperable cases.<sup>[3]</sup>

## CASE REPORT

A 22-year-old female came with the chief complaint of swelling over the left front side of the face since 4 months [Figure 1]. Patient gave the history of extraction in the same

This is an open access article distributed under the terms of the Creative Commons Attribution-NonCommercial-ShareAlike 3.0 License, which allows others to remix, tweak, and build upon the work non-commercially, as long as the author is credited and the new creations are licensed under the identical terms.

For reprints contact: reprints@medknow.com

**How to cite this article:** Shrivastava S, Nayak SK, Nayak P, Sahu S. Fibrosarcoma of maxilla: A rare case report. J Oral Maxillofac Pathol 2016;20:162.

## Access this article online

### Quick Response Code:

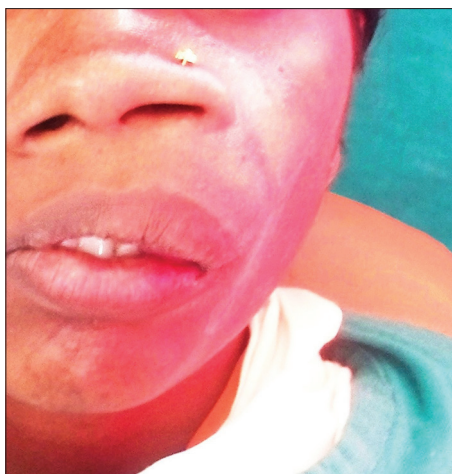

### Website:

www.jomfp.in

### DOI:

10.4103/0973-029X.180983

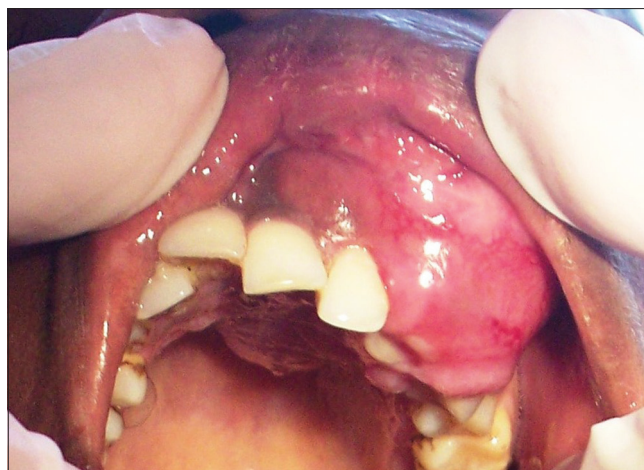


**Figure 1:** Extraorally, a swelling was noticed on the left side of face

region 1 year back. There was no significant contributing family and medical history. The patient gave a history of rapidly enlarging swelling which attained the present size of 3 cm × 4 cm. There was associated history of difficulty in speech and mastication. Extraorally, the swelling extended superoinferiorly from infraorbital margin to the upper lip and anteroposteriorly from midline to the corner of the mouth. Swelling was round to oval in shape with well-defined borders. Skin over the swelling was stretched but was normal in color. The swelling was firm and fixed to underlying structures. Intraorally, the swelling appeared to be arising from the labial vestibule extending up to the second premolar of the left side [Figure 2]. The buccal cortical plates were expanded but intact. There was displacement and Grade II mobility in relation to 21, 22 and 24.

The orthopantomography revealed unilocular radiolucency associated with 11, 12, 21, 22, 24 and root resorption in relation to 21, 22, 24 with missing 23 [Figure 3]. The computed tomography scan also revealed perforation of the cortical plates. Chest X-ray and hematological investigation were within the normal limits.

Informed consent was taken from the patient and surgical excision was done and the tissue was sent for the histopathological examination. The hematoxylin and eosin stained sections revealed the presence of parakeratinized stratified squamous epithelium overlying the connective tissue stroma. The connective tissue was fibrocellular in nature with numerous spindle-shaped cells. The cells were arranged in fascicular pattern with few areas showing herringbone pattern of arrangement [Figure 4]. The cells were dysplastic in nature with most of them showing cellular and nuclear pleomorphism. The cells showed immunoreactivity for vimentin [Figure 5]. There were few areas showing round cells [Figure 6]. Under low power the lesional cells were separated from the overlying epithelium by a zone of connective tissue. [Figure 7]. Under high power the typical herring bone pattern was seen [Figure 8]. Based on the histological assessment, the final diagnosis of intermediate grade fibrosarcoma was made.



**Figure 2:** Intraorally, the swelling was seen involving the left canine and extending up to the second premolar

Patient is under follow-up from last few months without any complications.

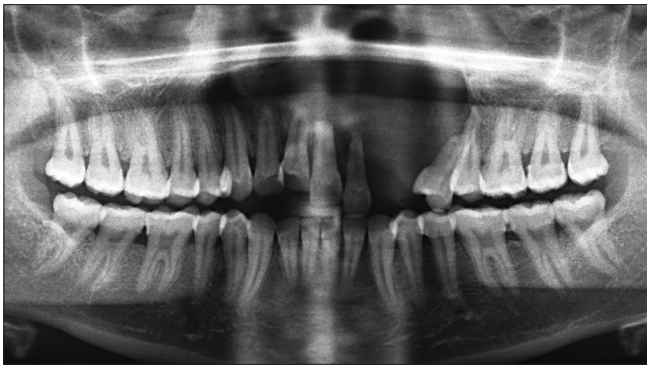
## DISCUSSION

Fibrosarcoma is a malignant tumor that arises from the fibroblasts. This is a type of sarcoma that is predominantly found in the area around the bones or in soft tissue. In earlier studies of soft tissue neoplasm, this tumor has been greatly overdiagnosed and this diagnosis has been frequently applied to virtually any richly cellular, collagen-forming spindle-cell tumor including malignant fibrous histiocytoma, malignant peripheral nerve sheath tumor and a host of other sarcomatous and pseudosarcomatous lesions.<sup>[4]</sup>

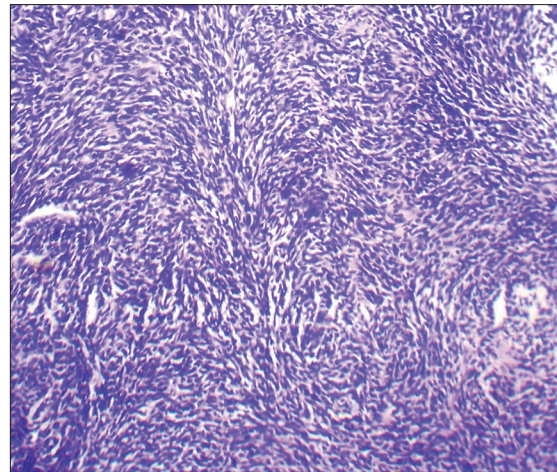
It is a rare tumor, accounting for approximately 5% of all malignant intraosseous tumors and especially affects the long bones.<sup>[5]</sup> Of all the fibrosarcomas occurring in humans, only 0.05% occur in the head and neck region. Of this, almost 23% is seen in the oral cavity.<sup>[3]</sup> Fibrosarcoma may arise as a primary tumor in any part of the jaws and may be classified as either peripheral (periosteal) or central (endosteal) type. Secondary fibrosarcoma of the bone may be associated with fibrous dysplasia, Paget's disease, bone infarct or cyst and/or osteomyelitis; it may also occur as a malignant transformation of giant-cell tumor of the bone or be induced by prior irradiation.

Clinically, in the oral cavity, the major symptoms are pain, swelling and sometimes loosening of the teeth and paresthesia. Secondary ulceration may be seen as the lesion enlarges.<sup>[5,6]</sup> Radiographically, an osteolytic lesion is usually present, with ill-defined borders; however, fibrosarcoma of the jaws cannot be distinguished from other destructive lesions of the bone.<sup>[5]</sup>

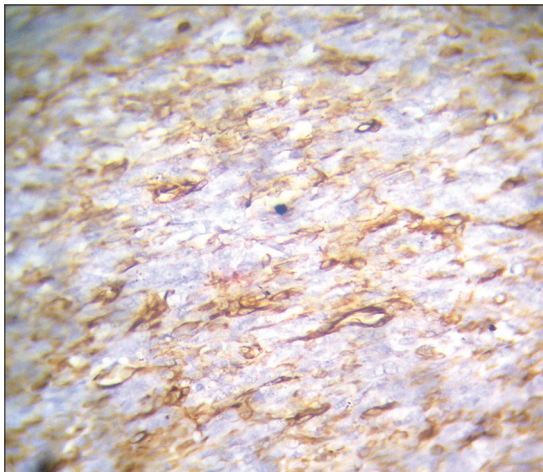
Histopathologically, fibrosarcomas of bone are invasive tumors with no distinct margins. The cells are rather uniform and spindle-shaped and arranged in fascicles, often



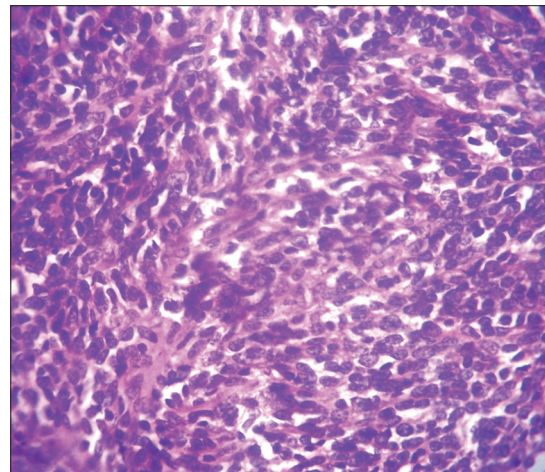
**Figure 3:** Radiograph showing well-defined radiolucency and resorption of teeth



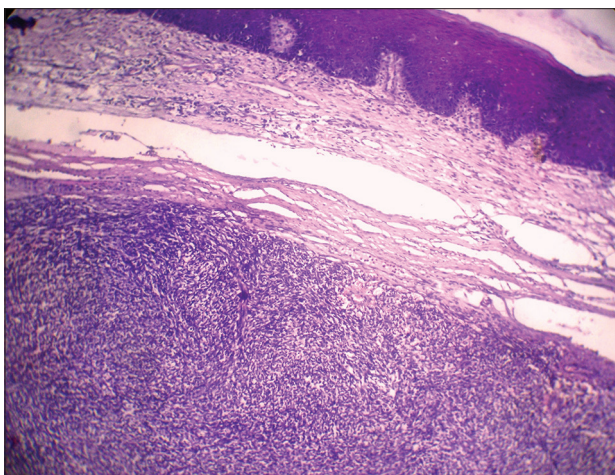
**Figure 4:** Photomicrograph showing the spindle cells arranged in herringbone pattern (H&E stain, x40)



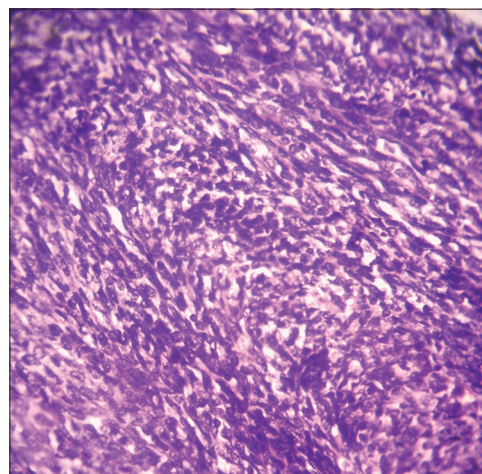
**Figure 5:** Lesional cells showing positivity for vimentin (IHC stain, x200)



**Figure 6:** Few areas showing round cells (H& E stain, x400)



**Figure 7:** The lesional cells were separated from the overlying epithelium by a zone of connective tissue (H&E stain, x40)



**Figure 8:** Dysplastic spindle cells arranged in herringbone pattern (H&E stain, x200)

forming a herringbone pattern. Histologically, the degree of differentiation of this neoplasm is variable, comparable to either a benign fibroma or an anaplastic tumor. Therefore, care should be taken to distinguish it from other spindle-cell neoplasms.<sup>[7]</sup>

Fibrosarcoma has got variable presentation due to variation in degree of cellularity, mitotic activity and pleomorphism

which has led to the histological grading of the tumor. Grade I (well differentiated) refers to tumors of uniform nuclear appearance with an appreciable amount of collagenous intercellular substance. In Grade II (intermediate) tumors, there is more cellularity and less intercellular substance showing herringbone pattern. Occasional mitotic figures may be seen. Grade III (high) tumors are anaplastic cellular growths often containing many giant cells and mitotic figures. Histological grading is important, as it has direct correlation with the prognosis of tumor. Occasionally, it is difficult to differentiate fibrosarcoma from other spindle-cell neoplasm. Fibrosarcoma stains strongly positive for vimentin. Markers for muscle (desmin and actin), macrophages (CD68), neural tissue (S-100, neuron specific enolase), melanoma (HMB-450) and epithelial tissue (cytokeratin, epithelial membrane antigen) will be absent.<sup>[8,9]</sup>

Wadhwan *et al.* in 2010 reported two cases of fibrosarcoma of maxilla which was diagnosed on the basis of herringbone pattern with positivity for vimentin.<sup>[3]</sup> Dhanavelu *et al.* in 2012 reported a case in a 73-year-old female patient.<sup>[10]</sup> Khanna *et al.* in 2014 reported a case of fibrosarcoma of maxilla with its extension into maxillary sinus.<sup>[8]</sup>

Adequate resection appears to be the most important factor in treatment. Radiation therapy is generally only considered in cases where resection is impossible. Chemotherapy is used only for palliation. The overall 5 year survival rate for fibrosarcoma of bone has been reported to be between 28.7% and 34%. Periosteal fibrosarcoma has a better prognosis than that of medullary origin, with 5 year survival rates of 52% and 27%, respectively.<sup>[10]</sup> Local recurrence is very common, but metastasis is rare and occurs mostly in lungs or to distant bones. Lymph node metastasis is extremely rare.<sup>[11]</sup>

## CONCLUSION

Fibrosarcoma of jaws are rare, detailed clinical, histological and immunohistochemical analysis is very important in such cases. Dentists should be able to recognize the features of

fibrosarcoma to propose appropriate investigations and help in treatment planning.

## Financial support and sponsorship

Nil.

## Conflicts of interest

There are no conflicts of interest.

## REFERENCES

1. Rajendran R. Benign and malignant tumors of the oral cavity. In: Rajendran R, Sivapathasundaram B, editor. Shafer's Textbook of Oral Pathology. 6<sup>th</sup> ed. New Delhi: Elsevier; 2009. p. 80-218.
2. Neville BW, Damm DD, Allen CM, Bouquot JE. Oral and Maxillofacial Pathology. 3<sup>rd</sup> ed. Noida: Saunders; 2009.
3. Wadhwan V, Chaudhary MS, Gawande M. Fibrosarcoma of the oral cavity. Indian J Dent Res 2010;21:295-8.
4. Weiss SW, Goldblum JR. Fibrosarcoma. In: Enzinger and Weiss's Soft Tissue Tumors. 5<sup>th</sup> ed. New Delhi: Elsevier; 2008. p. 303-30.
5. Angiero F, Rizzuti T, Crippa R, Stefani M. Fibrosarcoma of the jaws: Two cases of primary tumors with intraosseous growth. Anticancer Res 2007;27:2573-81.
6. Regezi JA, Sciubba JJ, Jordan RC. Oral Pathology: Clinical Pathologic Considerations. 5<sup>th</sup> ed. New Delhi: Elsevier; 2009.
7. Swain N, Kumar SV, Dhariwal R, Routray S. Primary fibrosarcoma of maxilla in an 8-year-old child: A rare entity. J Oral Maxillofac Pathol 2013;17:478.
8. Khanna S, Singh NN, Singh A, Purwar A. Fibrosarcoma of maxilla with extension into maxillary sinus: A rare case report. Oral Maxillofac Pathol J 2014;5:462-5.
9. Malati T. Tumour markers: An overview. Indian J Clin Biochem 2007;22:17-31.
10. Dhanavelu P, Prasanth K, Masthan KM, Ebenezer V. Fibrosarcoma of maxilla. A case report. Indian J Multidiscip Dent 2012;2:581-2.
11. Handlers JP, Abrams AM, Melrose RJ, Milder J. Fibrosarcoma of the mandible presenting as a periodontal problem. J Oral Pathol 1985;14:351-6.