

Retrospective Study

Hypothyroidism in patients with autoimmune pancreatitis

Ryoko Shimizuguchi, Terumi Kamisawa, Yuka Endo, Masataka Kikuyama, Sawako Kuruma, Kazuro Chiba, Taku Tabata, Satomi Koizumi

Ryoko Shimizuguchi, Terumi Kamisawa, Yuka Endo, Masataka Kikuyama, Sawako Kuruma, Kazuro Chiba, Taku Tabata, Satomi Koizumi, Department of Internal Medicine, Tokyo Metropolitan Komagome Hospital, Tokyo 113-8677, Japan

ORCID number: Ryoko Shimizuguchi (0000-0001-9501-6547); Terumi Kamisawa (0000-0002-2237-2767); Yuka Endo (0000-0002-2416-6051); Masataka Kikuyama (0000-0003-1869-5536); Sawako Kuruma (0000-0002-4113-2718); Kazuro Chiba (0000-0003-0324-859X); Taku Tabata (0000-0003-1207-1087); Satomi Koizumi (0000-0002-3840-1542).

Author contributions: All authors helped to perform the research; Shimizuguchi R and Kamisawa T wrote manuscript, collected and analyzed data; Endo Y, Kikuyama M, Kuruma S, Chiba K, Tabata T and Koizumi S collected data.

Institutional review board statement: This study was reviewed and approved by the Ethics Committee of the Tokyo Metropolitan Komagome Hospital.

Informed consent statement: This study is a retrospective our using information that had been obtained according to comprehensive agreement.

Conflict-of-interest statement: All authors declare no conflict-of-interest related to this article.

Data sharing statement: No additional data are available.

Open-Access: This article is an open-access article which was selected by an in-house editor and fully peer-reviewed by external reviewers. It is distributed in accordance with the Creative Commons Attribution Non Commercial (CC BY-NC 4.0) license, which permits others to distribute, remix, adapt, build upon this work non-commercially, and license their derivative works on different terms, provided the original work is properly cited and the use is non-commercial. See: <http://creativecommons.org/licenses/by-nc/4.0/>

Manuscript source: Unsolicited manuscript

Correspondence to: Dr. Terumi Kamisawa, MD, PhD, Chief Doctor, Department of Internal Medicine, Tokyo Metropolitan Komagome Hospital, 3-18-22 Honkomagome, Tokyo 113-8677,

Japan. kamisawa@cick.jp
Telephone: +81-3-38232101
Fax: +81-3-38235433

Received: November 27, 2017

Peer-review started: November 28, 2017

First decision: January 2, 2018

Revised: January 19, 2018

Accepted: March 6, 2018

Article in press: March 7, 2018

Published online: May 6, 2018

Abstract**AIM**

To examine thyroid function and clinical features of hypothyroidism in autoimmune pancreatitis (AIP) patients.

METHODS

We examined thyroid function in 77 patients with type 1 AIP (50 males, 27 females; median age 68 years, range 33-85) diagnosed according to the Japanese diagnostic criteria for AIP 2011. We compared clinical and serological findings between patients with and without various categories of hypothyroidism. The change in hypothyroidism after steroid therapy was also examined.

RESULTS

Eight patients (10%) had hypothyroidism of 6 patients had subclinical hypothyroidism with a normal serum free thyroxine (FT4) and high thyroid stimulating hormone (TSH) level, and 2 patients had central hypothyroidism with low serum free triiodothyronine (FT3), FT4 and TSH levels. A significant goiter of the thyroid was not observed in any patient. There were no significant differences in age; male to female ratio; serum concentrations of IgG and IgG4-related disease (IgG4-RD); presence of anti-thyroglobulin antibody, antinuclear antigen or rheumatoid factor; or presence of extrapancreatic lesions between the 6 patients with subclinical hypothyroidism and patients

with euthyroidism. After steroid therapy, both subclinical and central hypothyroidism improved with improvement of the AIP.

CONCLUSION

Hypothyroidism was observed in 8 (10%) of 77 AIP patients and was subclinical in 6 patients and central in 2 patients. Further studies are necessary to clarify whether this subclinical hypothyroidism is another manifestation of IgG4-RD.

Key words: Autoimmune pancreatitis; Hypothyroidism; IgG4-related disease

© **The Author(s) 2018.** Published by Baishideng Publishing Group Inc. All rights reserved.

Core tip: Autoimmune pancreatitis (AIP) is a pancreatic manifestation of IgG4-related disease (IgG4-RD) and is frequently associated with other IgG4-RDs. The aim of this study was to examine thyroid function and clinical features of hypothyroidism in AIP patients. Hypothyroidism was observed in 8 (10%) of 77 AIP patients and was subclinical in 6 patients and central in 2 patients. After steroid therapy, both subclinical and central hypothyroidism improved with improvement of the AIP.

Shimizuguchi R, Kamisawa T, Endo Y, Kikuyama M, Kuruma S, Chiba K, Tabata T, Koizumi S. Hypothyroidism in patients with autoimmune pancreatitis. *World J Gastrointest Pharmacol Ther* 2018; 9(2): 16-21 Available from: URL: <http://www.wjgnet.com/2150-5349/full/v9/i2/16.htm> DOI: <http://dx.doi.org/10.4292/wjgpt.v9.i2.16>

INTRODUCTION

IgG4-related disease (RD) is a systemic inflammatory disorder that was first proposed following the observation of patients with autoimmune pancreatitis (AIP) in 2003^[1]. IgG4-RD is characterized by infiltration of IgG4-positive plasma cell and lymphocyte and an elevated serum IgG4 concentration. AIP is currently divided into type 1 and type 2; type 1 AIP is recognized as a pancreatic manifestation of IgG4-RD^[2]. AIP has been reported to be complicated with various other IgG4-RDs such as sclerosing cholangitis, sialadenitis, dacryoadenitis, retroperitoneal fibrosis, interstitial lung disease, and tubulointerstitial nephritis^[3]. Komatsu *et al*^[4] first reported in 2005 that 26.8% of 41 AIP patients showed hypothyroidism; however, there are only a few reports regarding thyroid function in AIP patients^[4-6]. In this study, we examined thyroid function in 77 AIP patients and the change in hypothyroidism after steroid therapy.

MATERIALS AND METHODS

Patients

A total of 77 patients with type 1 AIP (50 males, 27

females; median age 68 years, range 33-85) who had been examined and treated at Tokyo Metropolitan Komagome Hospital, were enrolled in this study. The diagnosis of type 1 AIP was based on the Japanese diagnostic criteria for AIP 2011^[7].

Study design

In all AIP patients, antinuclear antibody (ANA) and rheumatoid factor (RF) were assayed, and the serum concentrations of IgG and IgG4 as well as the serum levels of free triiodothyronine (FT3), free thyroxine (FT4), and thyroid stimulating hormone (TSH), were measured. Anti-thyroglobulin antibodies (TgAb) and anti-thyroid peroxidase antibodies (TPOAb) were measured in 41 and 6 of the patients. Extrapancreatic lesions of AIP were defined as sclerosing cholangitis of the hilar or intrahepatic bile duct, sialadenitis/dacryoadenitis, retroperitoneal fibrosis and renal lesions. Contrast-enhanced computed tomography (CT) of neck or chest was performed for screening of other lesions of IgG4-RD in 65 patients. Ultrasonography of the thyroid was done only in 2 patients.

We classified hypothyroidism into two groups according to the following conditions: Clinical hypothyroidism with high TSH and low FT4 levels, and subclinical hypothyroidism with high TSH levels and normal FT4 levels. Hypothyroidism induced by hypophysitis, which showed low FT3, FT4 and TSH levels, was termed central hypothyroidism. Clinical and serological findings and extrapancreatic lesions were compared between patients with and without these various hypothyroidisms.

Steroid therapy was administered to 70 AIP patients and consisted of initial prednisolone (0.6 mg/kg per day) for 2-4 wk that was gradually tapered to a maintenance dose of 2.5-5 mg/d over a period of 2-3 mo. Maintenance therapy was administered for 1-2 years to prevent relapse. The serum levels of FT3, FT4, and TSH in the 6 patients with subclinical hypothyroidism and the 2 patients with central hypothyroidism were measured after treatment with prednisolone.

This study was approved by the institutional review board. Informed consent for invasive modalities had been obtained prior to performance from all study participants.

Statistical analysis

Statistical analyses were performed using paired *t*-test in Figure 1 and Fisher's exact test and the Mann-Whitney *U*-test in Table 1. A *P* value of less than 0.05 was regarded as indicating a statistically significant difference. The statistical methods of this study were reviewed by a biostatistician.

RESULTS

Of the 77 study patients with AIP, 8 (10%) had hypothyroidism. Of these 8 patients, 6 patients had subclinical hypothyroidism with a normal FT4 and a high TSH level, and 2 patients had central hypothyroidism with low FT3, FT4 and TSH levels. There were no

Table 1 Clinical and serological differences in autoimmune pancreatitis patients with hypothyroidism and euthyroidism

	Hypothyroidism (n = 8)	Euthyroidism (n = 69)	P value
Age	70 (58-85) ¹	66 (63-68)	0.421
Sex (M/F)	6/2	44/25	0.571
IgG (mg/dL)	2315 (961-4557)	1829 (883-4135)	0.487
IgG4 (mg/dL)	366 (26-715)	304 (11-2490)	0.482
Rheumatoid factor (+)	1/6	21/65	0.324
Antinuclear antibody (+)	2/7	32/69	0.242
Anti-thyroglobulin antibody (+)	0/7	3/36	-
Anti-thyroidperoxidase antibody (+)	1/6	0/0	-
Extrapancreatic lesions (+)	2/8	27/69	0.912

¹Median (range). M: Male; F: Female; IgG4: IgG4-related disease.

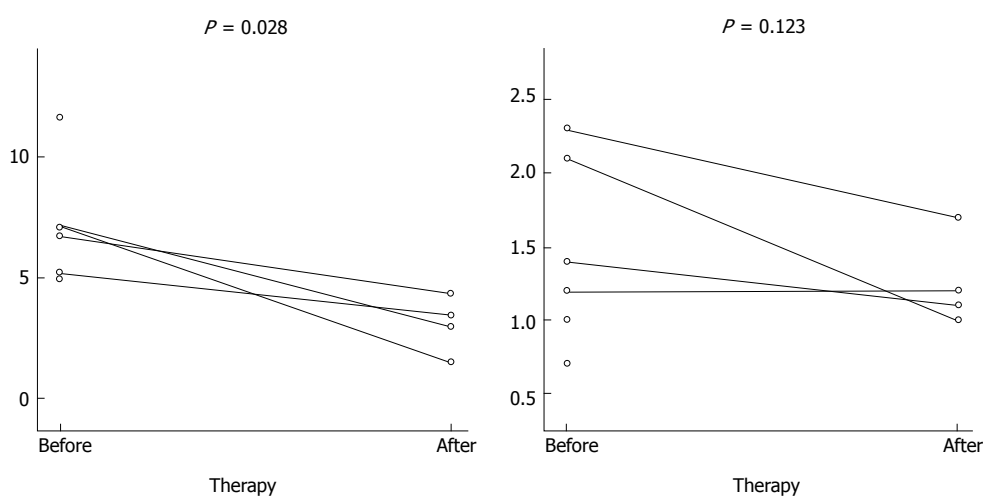


Figure 1 Changes in thyroid stimulating hormone and free thyroxine levels after steroid therapy of autoimmune pancreatitis patients with subclinical hypothyroidism.

patients with clinical hypothyroidism who required thyroid hormone supplements. The remaining 69 patients had euthyroidism with normal FT4 and TSH levels (Table 2). A past history of hypothyroidism had not been identified for any patient. A significant goiter of the thyroid was not observed in any patient. Enlargement of the pituitary stalk was observed on CT and MRI and decreased levels of other pituitary hormones (adrenocorticotropic hormone (ACTH), luteinizing hormone (LH), and follicle-stimulating hormone (FSH) were observed in the 2 patients with central hypothyroidism.

There were no significant differences in age; male to female ratio; serum concentrations of IgG and IgG4; the presence of anti-thyroglobulin antibody, RF, or ANA; or presence of extrapancreatic lesions between the 6 patients with subclinical hypothyroidism and the patients with euthyroidism. Male preponderance was at comparable levels in patients with hypothyroidism and in those with euthyroidism (Table 1).

The AIP of all patients responded well to steroids. After steroid therapy, serum TSH values had decreased significantly from a median value of 6.95 μ IU/mL to a value of 3.24 μ IU/mL ($P = 0.029$) and the FT4 values had decreased from a median value of 1.3 ng/dL to a value of 1.15 ng/dL ($P = 0.146$) in the 6 patients with

subclinical hypothyroidism (Figure 1).

In the 2 patients with central hypothyroidism, the TSH and FT4 values had increased to the normal range one month after starting corticosteroid therapy (Figure 2). The enlargement of the pituitary stalk and decreased levels of other pituitary hormones had also improved.

One patient with normal FT4 and TSH levels had a benign cyst in the thyroid on ultrasonography, and low density areas suggesting adenomas in the thyroid were pointed out on CT.

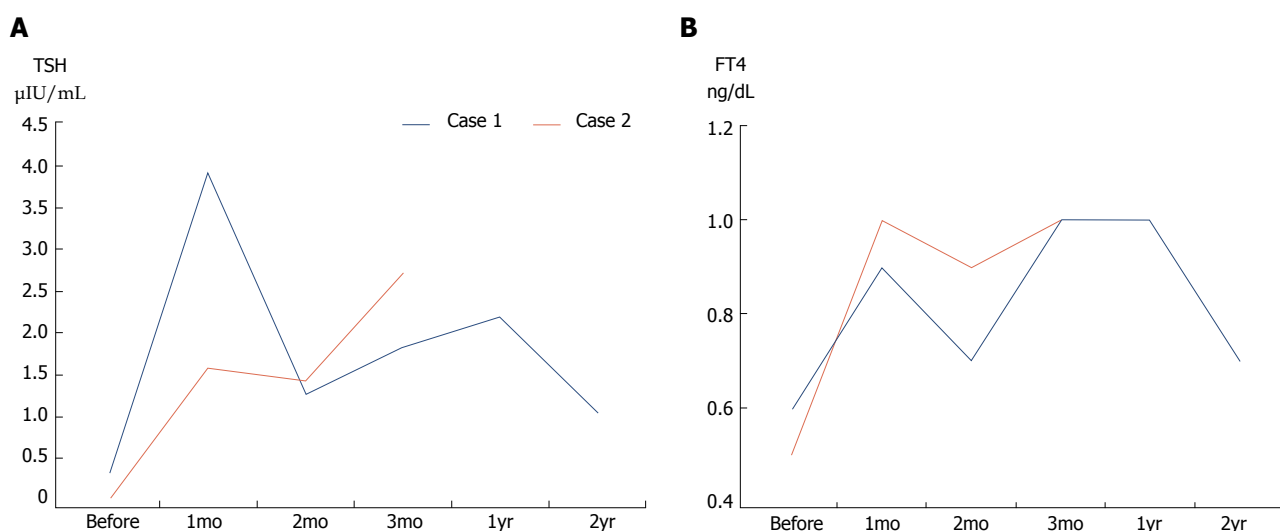
DISCUSSION

AIP is now recognized as a pancreatic manifestation of IgG4-RD. IgG4-RD is a systemic disease that is characterized by organ enlargement, male preponderance, elevated serum IgG4 levels, marked infiltration of IgG4-positive plasma cells and lymphocytes with fibrosis, and steroid responsiveness. Many patients with IgG4-RD have lesions in several organs, synchronously or metachronously, and various other IgG4-RDs are frequently associated with AIP^[2,3].

In the present study, hypothyroidism was observed in 8 (10%) of 77 AIP patients of whom 6 (8%) patients had subclinical hypothyroidism with a normal

Table 2 Free T3, free T4 and thyroid stimulating hormone levels in autoimmune pancreatitis patients with subclinical hypothyroidism, central hypothyroidism and euthyroidism

	Subclinical hypothyroidism (n = 6)	Central hypothyroidism (n = 2)	Euthyroidism (n = 69)
Free T3 (2.0-3.8 pg/mL)	1.5 (1.1-2.0) ¹	1.6 (1.6-1.7)	2.1 (0.7-3.2)
Free T4 (0.7-1.5 ng/dL)	1.3 (0.7-2.3)	0.5 (0.5-0.6)	1.1 (0.9-1.5)
TSH (0.4-4.80 µIU/mL)	6.95 (5.04-11.6)	0.19 (0.04-0.34)	1.60 (0.48-4.46)

¹Median (range).**Figure 2** Changes in (A) thyroid stimulating hormone and (B) free thyroxine levels after steroid therapy of autoimmune pancreatitis patients with central hypothyroidism. TSH: Thyroid stimulating hormone; FT4: Free thyroxine.

FT4 and a high TSH level, and 2 patients had central hypothyroidism with low FT3, FT4 and TSH levels. In a study by Komatsu *et al*^[4], the prevalence of hypothyroidism in AIP patients was reported as 26.8% (11/41), and 6 patients had clinical hypothyroidism with a low FT4 level of whom 5 patients were treated with thyroid hormone supplements. Sah *et al*^[5] reported the detection of clinical hypothyroidism requiring thyroxine supplementation in 14 (14.4%) of 97 AIP patients. In a study by Abraham *et al*^[6], the prevalence of AIP patients with hypothyroidism was 18.2% (2/11). Watanabe *et al*^[8] reported that hypothyroidism was found in 22 (19%) of 114 patients with IgG4-RD. The prevalence of hypothyroidism in our AIP patients was lower than those reported in the literature, but the prevalence in the general population has been reported as 4.6%^[9].

The AIP patients with and without hypothyroidism in the present study were predominantly elderly males. Although these findings were similar to those of Komatsu's report^[4], they differed from the findings of Sah's report^[5], in which the AIP patients with hypothyroidism (71 ± 8 years) were older than those without hypothyroidism (57 ± 16 years). However, in Sah's^[5] report, 11 of the 14 AIP patients with hypothyroidism were already on thyroxine supplementation at the time of presentation with AIP. In Komatsu's^[4] report, AIP patients with hypothyroidism showed a significantly higher frequency of anti-

thyroglobulin antibody (63.6%) than euthyroid subjects (20.0%). However, in our study only 3 euthyroid AIP patients were positive for anti-thyroglobulin antibody. There were no differences in serum IgG4 levels or in the prevalence of other organ involvement between AIP patients with and without hypothyroidism in the present study. These findings were similar to the data reported in the studies of both Komatsu *et al*^[4] and Sah *et al*^[5]. In terms of therapy, the AIP patients with hypothyroidism in our study responded well to steroids, whereas the two other studies^[4,5] reported that steroid therapy could not ameliorate hypothyroidism. In summary, many of the findings in our study differed from those in the previously reported studies including our findings that the prevalence of hypothyroidism in AIP patients was twice that in the general population but was lower than reported data; the hypothyroidism in AIP patients was relatively mild without need of thyroxine supplementation; only 1 anti-thyroidperoxidase antibody and no anti-thyroglobulin antibody was detected in our AIP patients with hypothyroidism; and our hypothyroid AIP patients showed a good response to steroids. However, we cannot explain the reasons behind these discrepancies.

Riedel's thyroiditis is a rare disease that has been described as a part of multifocal fibrosclerosis involving sclerosing cholangitis, retroperitoneal fibrosis, and chronic pancreatitis. However, it is now recognized

clinicopathologically as a thyroid lesion of IgG4-RD^[2,10,11]. In our cohort, only 1 patient was diagnosed as Riedel's thyroiditis based on histological examination of the resected specimen, while this case did not have AIP and was not included in this study.

Hashimoto's thyroiditis is an autoimmune thyroiditis that is almost always associated with diffuse goiter^[12]. In 2009, Li *et al.*^[13] first described a unique subtype of Hashimoto's disease, known as IgG4-related Hashimoto's disease. They classified Hashimoto's thyroiditis into two groups: IgG4-related Hashimoto's thyroiditis with abundant infiltration of IgG4-positive plasma cells, and non-IgG4 Hashimoto's thyroiditis without infiltration of IgG4-positive cells based on IgG4-immunostaining^[13]. Patients with IgG4-related Hashimoto's thyroiditis tended to be younger and male; were more likely to have a shorter duration of disease; and had higher level of anti-thyroglobulin antibodies than patients with non-IgG4 Hashimoto's thyroiditis^[14]. The AIP patients with hypothyroidism in our study showed no goiter, a preponderance of elderly males, and no presence of anti-thyroglobulin antibodies. Since histological examination of the thyroid was not done in any of our cases, a precise judgement regarding whether these cases were IgG4-related Hashimoto's thyroiditis or not could not be made; however, our cases of subclinical hypothyroidism appeared to be different from the so-called IgG4-related Hashimoto's thyroiditis.

Good responsiveness to steroids is one of the major characteristics of IgG4-RD, and the hypothyroidism in our AIP patients improved after steroid administration and was accompanied by improvement of AIP. Thus, this hypothyroidism appeared to be a thyroid lesion associated with AIP. However, it was reported that AIP patients with associated renal lesions or sialadenitis or dacryoadenitis show higher serum IgG4 levels and have more extrapancreatic lesions than those without these lesions, which may suggest higher disease activity^[15,16]. In the present cases, there were no significant differences in serum IgG4 levels or extrapancreatic lesions between AIP patients with and without hypothyroidism. Ultimately, we cannot judge whether the hypothyroidism observed in our AIP patients is a thyroid lesion involved in IgG4-RD from these findings due to lack of evidence of histology and imaging of the thyroid.

In the present study, we experienced two cases of central hypothyroidism that was induced by hypophysitis. Although IgG4-related hypophysitis is a rare lesion of IgG4-RD^[17], we showed that this lesion is one of the causes of hypothyroidism in AIP patients.

There are some limitations to this study. First, due to the retrospective nature of the study, anti-thyroglobulin antibodies and anti-thyroidperoxidase antibody were measured in only 41 and 6 patients. Second, a radiological study of the thyroid was not systemically performed. Third, histology of the thyroid was not examined in any of the patients with hypothyroidism.

In conclusion, the hypothyroidism detected in the AIP patients of this study was present to a mild degree

and was less frequent compared to previously reported cases. Further studies are necessary to clarify whether this hypothyroidism is another manifestation of IgG4-RD.

ARTICLE HIGHLIGHTS

Research background

Autoimmune pancreatitis (AIP) is a pancreatic manifestation of IgG4-related disease (IgG4-RD) and is frequently associated with other IgG4-RDs. AIP has been reported to be complicated with various other IgG4-RDs such as sclerosing cholangitis, sialadenitis, dacryoadenitis, retroperitoneal fibrosis, interstitial lung disease, and tubulointerstitial nephritis.

Research motivation

It was reported for the first time that 26.8% of 41 AIP patients showed hypothyroidism in 2005. However, there are only a few reports regarding thyroid function in AIP patients.

Research objective

The objective of this study was to examine thyroid function and clinical features of hypothyroidism in AIP patients.

Research methods

We examined thyroid function in 77 patients with type 1 AIP (50 males, 27 females; median age 68 years, range 33-85) diagnosed according to the Japanese diagnostic criteria for AIP 2011. We compared clinical and serological findings between patients with and without various categories of hypothyroidism. The change in hypothyroidism after steroid therapy was also examined.

Research results

Eight patients (10%) had hypothyroidism of 6 patients had subclinical hypothyroidism with a normal serum free thyroxine (FT4) and high thyroid stimulating hormone (TSH) level, and 2 patients had central hypothyroidism with low serum free triiodothyronine (FT3), FT4 and TSH levels. A significant goiter of the thyroid was not observed in any patient. There were no significant differences in age; male to female ratio; serum concentrations of IgG and IgG4; presence of anti-thyroglobulin antibody, antinuclear antigen or rheumatoid factor; or presence of extrapancreatic lesions between the 6 patients with subclinical hypothyroidism and patients with euthyroidism. After steroid therapy, both subclinical and central hypothyroidism improved with improvement of the AIP.

Research conclusions

Hypothyroidism was observed in 8 (10%) of 77 AIP patients and was subclinical in 6 patients and central in 2 patients. Further studies are necessary to clarify whether this subclinical hypothyroidism is another manifestation of IgG4-RD.

Research perspectives

Further studies are necessary to clarify whether this hypothyroidism is another manifestation of IgG4-RD.

ACKNOWLEDGMENTS

This work was supported partially by the Research Committee of Intractable Disease (Principal investigator: Kazuichi Okazaki) provided by the Ministry of Health, Labor, and Welfare of Japan.

REFERENCES

- 1 **Kamisawa T**, Funata N, Hayashi Y, Eishi Y, Koike M, Tsuruta K, Okamoto A, Egawa N, Nakajima H. A new clinicopathological

- entity of IgG4-related autoimmune disease. *J Gastroenterol* 2003; **38**: 982-984 [PMID: 14614606 DOI: 10.1007/s00535-003-1175-y]
- 2 **Kamisawa T**, Zen Y, Pillai S, Stone JH. IgG4-related disease. *Lancet* 2015; **385**: 1460-1471 [PMID: 25481618 DOI: 10.1016/S0140-6736(14)60720-0]
 - 3 **Kamisawa T**, Ryu JK, Kim MH, Okazaki K, Shimosegawa T, Chung JB. Recent advances in the diagnosis and management of autoimmune pancreatitis: similarities and differences in Japan and Korea. *Gut Liver* 2013; **7**: 394-400 [PMID: 23898377 DOI: 10.5009/gnl.2013.7.4.394]
 - 4 **Komatsu K**, Hamano H, Ochi Y, Takayama M, Muraki T, Yoshizawa K, Sakurai A, Ota M, Kawa S. High prevalence of hypothyroidism in patients with autoimmune pancreatitis. *Dig Dis Sci* 2005; **50**: 1052-1057 [PMID: 15986853 DOI: 10.1007/s10620-005-2703-9]
 - 5 **Sah RP**, Chari ST. Clinical hypothyroidism in autoimmune pancreatitis. *Pancreas* 2010; **39**: 1114-1116 [PMID: 20861701 DOI: 10.1097/MPA.0b013e3181e2188a]
 - 6 **Abraham SC**, Wilentz RE, Yeo CJ, Sohn TA, Cameron JL, Boitnott JK, Hruban RH. Pancreaticoduodenectomy (Whipple resections) in patients without malignancy: are they all 'chronic pancreatitis'? *Am J Surg Pathol* 2003; **27**: 110-120 [PMID: 12502933 DOI: 10.1097/0000478-200301000-00012]
 - 7 **Shimosegawa T**; Working Group Members of the Japan Pancreas Society; Research Committee for Intractable Pancreatic Disease by the Ministry of Labor, Health and Welfare of Japan. The amendment of the Clinical Diagnostic Criteria in Japan (JPS2011) in response to the proposal of the International Consensus of Diagnostic Criteria (ICDC) for autoimmune pancreatitis. *Pancreas* 2012; **41**: 1341-1342 [PMID: 23086247 DOI: 10.1097/MPA.0b013e3182706ed5]
 - 8 **Watanabe T**, Maruyama M, Ito T, Fujinaga Y, Ozaki Y, Maruyama M, Kodama R, Muraki T, Hamano H, Arakura N, Kadoya M, Suzuki S, Komatsu M, Shimojo H, Notohara K, Uchida M, Kawa S. Clinical features of a new disease concept, IgG4-related thyroiditis. *Scand J Rheumatol* 2013; **42**: 325-330 [PMID: 23496326 DOI: 10.3109/03009742.2012.761281]
 - 9 **Hollowell JG**, Staehling NW, Flanders WD, Hannon WH, Gunter EW, Spencer CA, Braverman LE. Serum TSH, T(4), and thyroid antibodies in the United States population (1988 to 1994): National Health and Nutrition Examination Survey (NHANES III). *J Clin Endocrinol Metab* 2002; **87**: 489-499 [PMID: 11836274 DOI: 10.1210/jcem.87.2.8182]
 - 10 **Dahlgren M**, Khosroshahi A, Nielsen GP, Deshpande V, Stone JH. Riedel's thyroiditis and multifocal fibrosclerosis are part of the IgG4-related systemic disease spectrum. *Arthritis Care Res* (Hoboken) 2010; **62**: 1312-1318 [PMID: 20506114 DOI: 10.1002/acr.20215]
 - 11 **Takeshima K**, Inaba H, Ariyasu H, Furukawa Y, Doi A, Nishi M, Hirokawa M, Yoshida A, Imai R, Akamizu T. Clinicopathological features of Riedel's thyroiditis associated with IgG4-related disease in Japan. *Endocr J* 2015; **62**: 725-731 [PMID: 26052139 DOI: 10.1507/endocrj.EJ15-0175]
 - 12 **Pearce EN**, Farwell AP, Braverman LE. Thyroiditis. *N Engl J Med* 2003; **348**: 2646-2655 [PMID: 12826640 DOI: 10.1056/NEJMra021194]
 - 13 **Li Y**, Bai Y, Liu Z, Ozaki T, Taniguchi E, Mori I, Nagayama K, Nakamura H, Kakudo K. Immunohistochemistry of IgG4 can help subclassify Hashimoto's autoimmune thyroiditis. *Pathol Int* 2009; **59**: 636-641 [PMID: 19712131 DOI: 10.1111/j.1440-1827.2009.02419.x]
 - 14 **Li Y**, Nishihara E, Hirokawa M, Taniguchi E, Miyauchi A, Kakudo K. Distinct clinical, serological, and sonographic characteristics of hashimoto's thyroiditis based with and without IgG4-positive plasma cells. *J Clin Endocrinol Metab* 2010; **95**: 1309-1317 [PMID: 20097712 DOI: 10.1210/jc.2009-1794]
 - 15 **Hamano H**, Arakura N, Muraki T, Ozaki Y, Kiyosawa K, Kawa S. Prevalence and distribution of extrapancreatic lesions complicating autoimmune pancreatitis. *J Gastroenterol* 2006; **41**: 1197-1205 [PMID: 17287899 DOI: 10.1007/s00535-006-1908-9]
 - 16 **Kuruma S**, Kamisawa T, Tabata T, Hara S, Fujiwara T, Kuwata G, Egarashira H, Koizumi K, Setoguchi K, Fujiwara J, Arakawa T, Momma K, Mitsuhashi T, Sasaki T. Clinical Characteristics of Patients with Autoimmune Pancreatitis with or without Mikulicz's Disease and Mikulicz's Disease Alone. *Gut Liver* 2013; **7**: 96-99 [PMID: 23422705 DOI: 10.5009/gnl.2013.7.1.96]
 - 17 **Leporati P**, Landek-Salgado MA, Lupi I, Chiovato L, Caturegli P. IgG4-related hypophysitis: a new addition to the hypophysitis spectrum. *J Clin Endocrinol Metab* 2011; **96**: 1971-1980 [PMID: 21593109 DOI: 10.1210/jc.2010-2970]

P- Reviewer: Eshraghian A, Fan RY, Gómez-Sáez JM **S- Editor:** Cui LJ

L- Editor: Filipodia **E- Editor:** Tan WW





Published by **Baishideng Publishing Group Inc**
7901 Stoneridge Drive, Suite 501, Pleasanton, CA 94588, USA
Telephone: +1-925-223-8242
Fax: +1-925-223-8243
E-mail: bpgoffice@wjgnet.com
Help Desk: <http://www.f6publishing.com/helpdesk>
<http://www.wjgnet.com>

