

Unexpected and durable response with regorafenib in a metastatic colorectal cancer patient without *KDR* mutation

A case report

Gerardo Rosati, MD^{a,*}, Nunzio Del Gaudio, MD^b, Enrico Scarano, MD^c, Rosa Anna Cifarelli, PhD^d, Lucia Altucci, MD, PhD^b, Domenico Bilancia, MD^a

Abstract

Rationale: Regorafenib is an oral multikinase inhibitor and is approved as salvage therapy in the standard treatment of advanced colorectal cancer (CRC). Due to its limited efficacy, toxicity profile, and cost, it is necessary to identify those patients who may have the most benefit from regorafenib. In a previous case report, kinase insert domain receptor (*KDR*) mutation has been associated with exceptional clinical response (CR) in an elderly patient treated with a low dose of regorafenib; thus, it was hypothesized that it could represent a new predictive marker of drug response.

Patient concerns: A heavily pretreated 67-year-old man with a wide peripancreatic recurrence of colon carcinoma and liver metastases was subjected to treatment with regorafenib.

Diagnoses: After 3 months of therapy, a computed tomography scan showed an impressive reduction of disease.

Interventions: Regorafenib was given at full doses (160 mg/die for 21 days, every 4 weeks).

Outcomes: A lasting response without relevant toxicity. No *KDR* mutation relief was detected. After 13 months from the start of treatment, the patient died after the diagnosis of encephalic metastases.

Lessons: Regorafenib can lead to an unexpected and durable CR with consistent progression-free survival and overall survival benefit even in patients affected by polychemotherapy refractory metastatic CRC. Further studies are needed to establish the benefit of *KDR* mutation as predictive marker for regorafenib sensitivity for patients with CRC. We include a detailed revision of prognostic and predictive factors of clinical outcome identified in literature to optimize the use of regorafenib in this setting.

Abbreviations: AE = adverse event, CCL5 = chemokine ligand 5, CR = clinical response, CRC = colorectal cancer, CT = computed tomography, ECOG = Eastern Cooperative Oncology Group, EGFR = antiepidermal growth factor receptor, FDG PET/CT = fluorine-18 fluorodeoxyglucose positron-emission tomography/CT, *KDR* = kinase insert domain receptor, KRAS = Kirsten rat sarcoma viral oncogene homolog, LDH = lactic dehydrogenase, OS = overall survival, PFS = progression-free survival, PS = performance status, TLG = total lesion glycolysis, VEGFR = vascular endothelial growth factor receptor.

Keywords: biomarker, colorectal cancer, *KDR*, prognostic factors, regorafenib

1. Introduction

Regorafenib is an oral multikinase drug that blocks several protein kinases associated with: angiogenesis including vascular

Editor: N/A.

The ethical approval was not considered necessary because the patient's regorafenib treatment was part of the common clinical practice. Written informed consent for the publication of this case report and the associated images was obtained from the patient before submission.

The authors have no funding and conflicts of interest to disclose.

^a Medical Oncology Unit, S Carlo Hospital, Potenza, ^b Department of Biochemistry, Biophysics and General Pathology, University of Campania "Luigi Vanvitelli", Napoli, ^c Radiology Department, S Carlo Hospital, Potenza, ^d Metapontum Agrobios, Metaponto di Bernalda, Matera, Italy.

* Correspondence: Gerardo Rosati, Medical Oncology Unit, S Carlo Hospital, via P Petrone, 1, 85100 Potenza, Italy (e-mail: oncogerry@yahoo.it).

Copyright © 2018 the Author(s). Published by Wolters Kluwer Health, Inc. This is an open access article distributed under the terms of the Creative Commons Attribution-Non Commercial-No Derivatives License 4.0 (CCBY-NC-ND), where it is permissible to download and share the work provided it is properly cited. The work cannot be changed in any way or used commercially without permission from the journal.

Medicine (2018) 97:25(e11178)

Received: 10 March 2018 / Accepted: 29 May 2018

<http://dx.doi.org/10.1097/MD.00000000000011178>

endothelial growth factor receptor (VEGFR) 1 to 3 and immunoglobulin and epidermal growth factor homology domain 2 (TIE2); oncogenesis involving V-kit sarcoma viral oncogene homolog and rearranged during transcription kinase, and tumor microenvironment as the platelet-derived growth factor receptor (PDGFR) and the fibroblast growth factor receptor (FGFR).^[1,2]

Regorafenib is currently used as standard salvage colorectal cancer (CRC) therapy. Two phase III trials reported significant progression-free survival (PFS) and overall survival (OS) benefits for regorafenib compared to placebo in this patient setting.^[3,4] Similar results have been reproduced in real-life clinical practice in a large study of 654 patients, although these data should be carefully interpreted due to retrospective design and exploratory subgroup analyses that were performed in the trial.^[5]

Nevertheless, the advantages obtainable by the administration of regorafenib appear limited and the majority of patients experienced at least 1 adverse event (AE), such as hand-foot skin reaction, diarrhea, fatigue, hypertension, anorexia, oral mucositis, hoarseness, and liver toxicity. Moreover, this agent has high costs and limiting its use only to cases which are strictly necessary might be very helpful for the health care system of any nation. In a French study, it was estimated that the overall mean and median cost for treating 1 patient with regorafenib is 9908 ± 8191 Euros

(€), and €7917, respectively, for a 2.5 months median time of treatment.^[6] The identification of a predictive marker also for regorafenib, as occurred with the Kirsten rat sarcoma viral oncogene homolog (*KRAS*) testing for anti-epidermal growth factor receptor (EGFR) antibodies, may lead to a personalized therapy and avoid unnecessary expense and potential toxicities.

The kinase insert domain receptor (*KDR*) is the human gene encoding for VEGFR-2. Because regorafenib targets VEGFR-2, it was hypothesized that the *KDR* mutation may represent a predictive marker for regorafenib activity.^[7] Loaiza-Bonilla et al reported the case of an elderly woman with mutations of *KRAS* and *KDR* and having an exceptional and lasting clinical response (CR) with a low dose of regorafenib (40 mg/die for 21 days, every 4 weeks). Here, we report the case of a heavily pretreated patient who had a sudden and durable response to regorafenib within 3 months from the start of treatment.

2. Case report

The patient, without *KRAS* mutation and aged 67, had a wide peripancreatic recurrence of colon carcinoma and liver metastases (Fig. 1). His performance status (PS) was optimal (Eastern Cooperative Oncology Group [ECOG]=0). From April 2012, he had undergone 4 previous lines of treatment with the subsequent use of a cetuximab plus irinotecan-based therapy as first line, another with bevacizumab plus oxaliplatin and 5-fluorouracil as second line, yet another with rechallenge of an anti-EGFR drug such as panitumumab within a clinical trial as third line, and finally a rechallenge of an oxaliplatin-based therapy as fourth line. In August 2015, he began a fifth-line treatment with regorafenib (160mg/die). The blood count with platelets was normal. Liver enzymes showed a small increase as well as LDH levels. The therapy was well tolerated without appearance of hypertension and cardiovascular events with only moderate skin toxicity (hand-foot syndrome grade 1). Continuous monitoring of laboratory tests did not show an increase in amylase and lipase levels nor in liver enzymes or in levels of electrolytes. After 3 months of therapy, the patient presented an unexpected CR with extended reduction of local recurrence of both the tumor and liver metastases (Fig. 2). A sudden parallel decrease in levels of

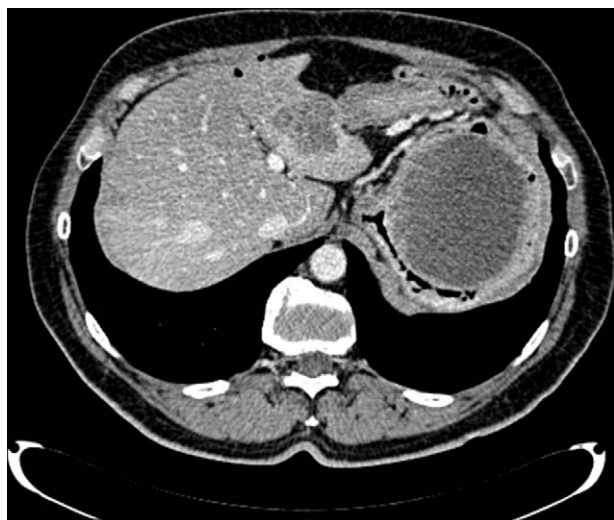

Figure 1. Abdominal computed tomography image prior to treatment with regorafenib (August 2015).

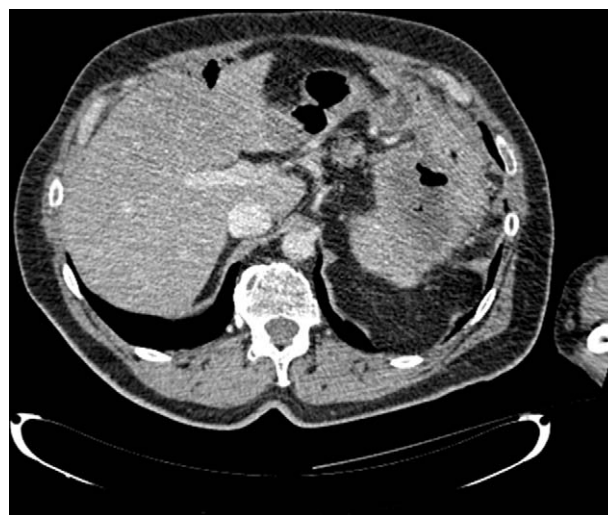

Figure 2. Peripancreatic recurrence of colon carcinoma and liver metastases decreased in size following 3 cycles of regorafenib (160mg/day) (November 2015).

carcinoembryonic antigen was also observed. One year after beginning the treatment with regorafenib, the patient stated to have headache, dizziness, and slurred speech due to the onset of encephalic metastases. Soon after, in September 2016, he died. The possible mutation of *KDR*, sought with the same methodology as that already described by Loaiza-Bonilla et al,^[8] was not found in our patient (Fig. 3).

3. Discussion

The case reported here suggests that regorafenib can lead to an unexpected and durable CR with consistent PFS and OS survival benefit even in patients affected by polychemotherapy refractory metastatic CRC, and in the absence of *KDR* mutation. Consequently, our findings do not support the identification of this mutation to predict regorafenib efficacy.

The possibility of obtaining a CR in this category of patients is very low, ranging from 1% to 4%, as reported, respectively, in the CORRECT and CONCUR trials.^[3,4] Even if the benefit of regorafenib is above all represented by a larger proportion of patients with disease control variable between 41% and 51%, this is not long lasting. In addition, regorafenib has high costs and sometimes a poorly manageable toxicity profile. Is it therefore possible to first identify those patients who may really benefit from this drug?

Taking into account that regorafenib targets mechanisms regulating neoangiogenesis, and since high lactic dehydrogenase (LDH) serum levels are associated with tumor overexpression of VEGF, it has been hypothesized that LDH levels may correlate with tumor angiogenesis and a worse prognosis.^[9,10] In addition, it is known that neutrophils, lymphocytes, and platelet counts have a prognostic role in predicting clinical outcome in CRC patients.^[11,12] Thus, Del Prete et al have analyzed the impact on survival of angiogenesis and inflammation-related factors in a series of 208 patients treated with regorafenib.^[13] At the multivariate analysis, high platelet count and high neutrophil/lymphocyte ratio were significantly related to worse OS, while high LDH serum levels indicated a trend toward a worse clinical outcome. Although this analysis was retrospective, the data are

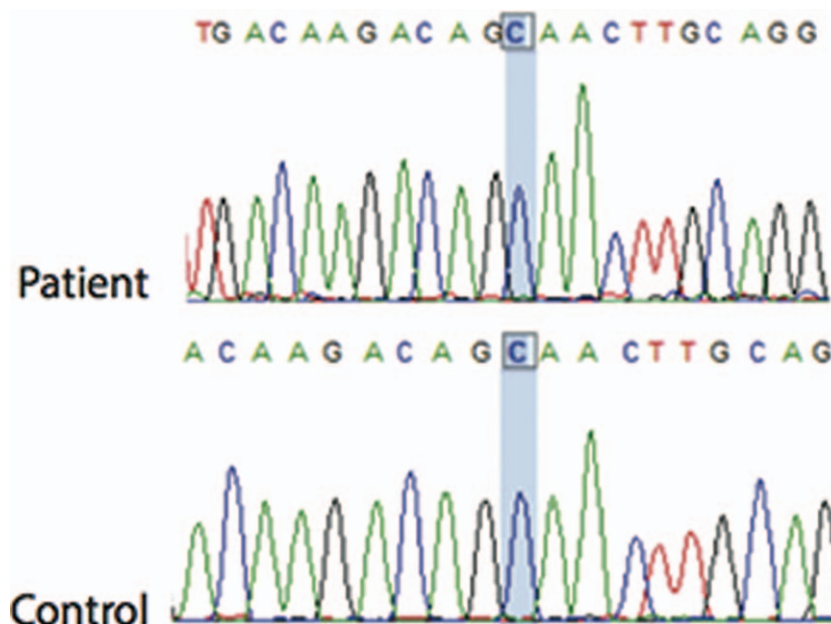


Figure 3. Kinase insert domain receptor (KDR) sequenced region, including position 2881, does not show mutation (highlighted inset). Primer pairs were designed to amplify human KDR fragments, including position 2881.

very interesting since the simple use of laboratory tests (and not biomolecular analyses) could easily identify patients who may have potentially greater or lesser advantages of regorafenib use. This hypothesis was confirmed in our case.

Another Italian study analyzed, with the same limitations, a small series of 105 patients and verified whether different levels of selected circulating angiogenic factors, such as angiopoietin 2 (Ang-2) and TIE-2, could be correlated with clinical outcome during regorafenib treatment.^[14] Low baseline levels of Ang-2 and TIE-2 were associated with longer PFS and OS. About half (45%) of 89 patients with plasma samples at day 15 showed higher levels of Ang-2 when compared to day 1 during therapy. Among them, 21 (53%) achieved disease control, as compared to 14 out of 49 (29%) patients with Ang-2 decreased levels ($P = .03$). Median PFS of patients with increased and decreased levels of Ang-2 were 3.1 and 1.8 months, respectively ($P = .004$). Since Ang-2, as an inhibitor of the TIE-2 receptor ligand, is closely related to the mechanisms regulating tumor angiogenesis, the authors argue that the inhibition of TIE-2 by regorafenib could result in a consequent increase in the levels of Ang-2 and be related to the antitumor activity.

It was reported that VEGF levels are higher in patients with colon cancer than in normal subjects, primarily in advanced stage of disease.^[15] Moreover, a previous study showed that different levels of VEGF during treatment with bevacizumab could be associated with antitumor efficacy more decisively than baseline, while another revealed that treatments with targeted therapies can significantly change the levels of cytokine expression.^[16,17] The authors of this latter analysis examined 11 angiogenic and inflammatory cytokine serum levels in 44 patients treated with regorafenib.^[18] In particular, the chemokine ligand 5 (CCL5) can be detected in close proximity of leukocytes infiltrating the tumor and in addition promotes the metastasis of cancer cells and reduces the immune activity. Low serum levels of CCL5 at baseline were associated with relative tumor shrinkage, better PFS and OS. A decrease on day 21 of VEGF-A levels was

significantly associated with a better PFS. Although this study was limited by its small sample size and further research with large patient cohorts is warranted, CCL5 and serum levels of VEGF-A could easily be used to predict the effectiveness of regorafenib.

A retrospective, exploratory analysis has investigated the clinical activity of regorafenib in biomarker subgroups of the CORRECT study population defined by tumor mutational status or plasma protein levels.^[19] Circulating tumor DNA could offer remarkable advantages over archival tumor tissue specimens, including the simplicity and repetition of the examination, and more precise representation of a tumor's current mutational status. The analyses of plasma and tumor DNA have suggested a clinical benefit favoring regorafenib across patient subgroups irrespective of mutational status of *KRAS* and *PIK3CA*. This is likely due to regorafenib antiangiogenic action mechanism. A working hypothesis is that the increase in circulating DNA concentrations could be associated with the extent of disease spread and therefore reflect the drug's effectiveness. In the analysis of Taberero et al,^[19] circulating baseline DNA concentrations had a prognostic value since patients with higher DNA concentrations had a lower survival median. Finally, measurements of some plasma proteins showed that regorafenib had a greater benefit in PFS and OS in patients with a higher concentration of TIE-1, although the benefit in OS was not significant in multivariate analysis. These results are not surprising, since TIE-1 can interact with the TIE-2 angiopoietin receptor and regorafenib has some inhibitory activity on both TIE-1 and TIE-2 kinases. However, the results of this study should be taken with caution given that they are the result of a retrospective analysis. In addition, the CORRECT study was not specifically powered to assess the clinical activity of regorafenib in biomarker-defined subgroups. The RadioCORRECT study is another post hoc analysis of patients enrolled in the CORRECT trial.^[20] Although this study has several limitations, such as the lack of an a priori statistical analysis that could give more

meaning to the results, the difference in baseline radiologic characteristics of patients treated with regorafenib or placebo and, above all, having considered only patients who had undergone the first post-treatment computed tomography (CT) planned at week 8 with the exclusion of those with resistant and therefore more aggressive tumors, it has identified imaging markers predicting clinical outcomes to regorafenib. In particular, tumor assessment by RECIST 1.1 with changing the size of the planned target lesions at week 8 predicts OS to regorafenib. This conclusion is in accordance with our case in which a dramatic and rapid reduction in size of the tumor resulted in a significant increase in OS.

Another radiologic study evaluated whether fluorine-18 fluorodeoxyglucose positron-emission tomography/CT (FDG PET/CT) was similarly predictive of regorafenib treatment outcome.^[21] In this case, 40 patients were evaluated among various PET parameters. Total lesion glycolysis (TLG) was calculated at baseline and after 2 cycles of treatment. Patients showing lower TLG at baseline displayed significantly longer OS, while patients with higher TLG after treatment had significantly longer PFS and OS. Since these results were demonstrated in a few patients, the measurement of TLG could be both a prognostic and predictive imaging biomarker if these findings were replicated in larger studies.

Finally, the authors of the REBECCA study identified some simple clinical variables (ECOG PS, time from early diagnosis of metastatic disease, initial dose of regorafenib, number of metastatic sites, liver metastases, and *KRAS* mutation) by dividing patients into 3 subgroups, each with different OS and 6-month OS rates.^[5] These results correlated with the population of the CORRECT study when the same variables were taken into account. Although the REBECCA study was retrospective and its conclusions should be interpreted with caution, their authors identified a prognostic model capable of identifying those patients who might benefit most from the use of regorafenib. Our patient, according to its clinical features, was placed in the low risk group (high regorafenib OS benefit) with a maximum prognostic score of 2 and therefore the results of the REBECCA study appear to coincide.

4. Conclusion

The *KDR* mutation was not found in the case of our patient with CR, a rare occurrence with regorafenib use. Thus, this result does not confirm the previously described association between *KDR* mutation and drug efficacy. In the last few years, several biologic markers, radiologic parameters, or clinical prognostic factors have been investigated with the aim of identifying those patients who will most benefit from regorafenib. Prospective clinical studies, specifically designed for this purpose, could clarify whether *KDR* or other prognostic and predictive efficacy factors can be considered in the future.

Author contributions

Conceptualization: Gerardo Rosati.

Data curation: Gerardo Rosati, Nunzio Del Gaudio, Enrico Scarano, Rosa Anna Cifarelli, Lucia Altucci, Domenico Bilancia.

Formal analysis: Gerardo Rosati, Nunzio Del Gaudio, Enrico Scarano, Rosa Anna Cifarelli, Lucia Altucci, Domenico Bilancia.

Funding acquisition: Gerardo Rosati, Domenico Bilancia.

Investigation: Gerardo Rosati, Nunzio Del Gaudio, Enrico Scarano, Rosa Anna Cifarelli, Lucia Altucci.

Methodology: Gerardo Rosati, Nunzio Del Gaudio, Enrico Scarano, Rosa Anna Cifarelli, Lucia Altucci.

Project administration: Gerardo Rosati, Nunzio Del Gaudio, Rosa Anna Cifarelli.

Resources: Gerardo Rosati, Rosa Anna Cifarelli, Domenico Bilancia.

Software: Gerardo Rosati.

Supervision: Gerardo Rosati, Nunzio Del Gaudio, Enrico Scarano, Lucia Altucci, Domenico Bilancia.

Validation: Gerardo Rosati, Nunzio Del Gaudio, Enrico Scarano, Rosa Anna Cifarelli, Lucia Altucci, Domenico Bilancia.

Visualization: Gerardo Rosati, Nunzio Del Gaudio, Enrico Scarano, Rosa Anna Cifarelli, Lucia Altucci, Domenico Bilancia.

Writing – original draft: Gerardo Rosati, Nunzio Del Gaudio, Enrico Scarano, Rosa Anna Cifarelli, Lucia Altucci, Domenico Bilancia.

Writing – review & editing: Gerardo Rosati, Nunzio Del Gaudio, Enrico Scarano, Rosa Anna Cifarelli, Lucia Altucci, Domenico Bilancia.

References

- [1] Strumberg D, Scheulen ME, Schultheis B, et al. Regorafenib (BAY 73-4506) in advanced colorectal cancer: a phase I study. *Br J Cancer* 2012; 106:1722–7.
- [2] Mross K, Frost A, Steinbild S, et al. A phase I dose-escalation study of regorafenib (BAY 73-4506), an inhibitor of oncogenic, angiogenic, and stromal kinases, in patients with advanced solid tumors. *Clin Cancer Res* 2012;18:2658–67.
- [3] Grothey A, Van Cutsem E, Sobrero A, et al. Regorafenib monotherapy for previously treated metastatic colorectal cancer (CORRECT): an international, multicentre, randomised, placebo-controlled, phase 3 trial. *Lancet* 2013;381:303–12.
- [4] Li J, Qin S, Xu R, et al. Regorafenib plus best supportive care versus placebo plus best supportive care in Asian patients with previously treated metastatic colorectal cancer (CONCUR): a randomised, double-blind, placebo-controlled, phase 3 trial. *Lancet Oncol* 2015;16: 619–29.
- [5] Adenis A, de la Fouchardiere C, Paule B, et al. Survival, safety, and prognostic factors for outcome with regorafenib in patients with metastatic colorectal cancer refractory to standard therapies: results from a multicenter study (REBECCA) nested within a compassionate use program. *BMC Cancer* 2016;16:412.
- [6] Calcagno F, Lenoble S, Lakkis Z, et al. Efficacy, safety and cost of regorafenib in patients with metastatic colorectal cancer in French clinical practice. *Clin Med Insights Oncol* 2016;10:59–66.
- [7] Loaiza-Bonilla A, Jensen CE, Shroff S, et al. *KDR* mutation as a novel predictive biomarker of exceptional response to regorafenib in metastatic colorectal cancer. *Cureus* 2016;8:e478.
- [8] Loaiza-Bonilla A, Clayton E, Furth E, et al. Dramatic response to dabrafenib and trametinib combination in a BRAF V600E-mutated cholangiocarcinoma: implementation of a molecular tumour board and next-generation sequencing for personalized medicine. *Ecancermedicalscience* 2014;8:479.
- [9] Azuma M, Shi M, Danenberg KD, et al. Serum lactate dehydrogenase levels and glycolysis significantly correlate with tumor VEGFA and VEGFR expression in metastatic CRC patients. *Pharmacogenomics* 2007;8:1705–13.
- [10] Tas F, Aykan F, Alici S, et al. Prognostic factors in pancreatic carcinoma: serum LDH levels predict survival in metastatic disease. *Am J Clin Oncol* 2001;24:547–50.
- [11] Li MX, Liu XM, Zhang XF, et al. Prognostic role of neutrophil to lymphocyte ratio in colorectal cancer: a systematic review and meta-analysis. *Int J Cancer* 2014;134:2403–13.
- [12] Adams RA, Meade AM, Seymour MT, et al. Intermittent versus continuous oxaliplatin and fluoropyrimidine combination chemotherapy for first-line treatment of advanced colorectal cancer: results of the randomised phase 3 MRC COIN trial. *Lancet Oncol* 2011;12:642–53.

- [13] Del Prete M, Giampieri R, Loupakis F, et al. Prognostic clinical factors in pretreated colorectal cancer patients receiving regorafenib: implications for clinical management. *Oncotarget* 2015;6:33982–92.
- [14] Antoniotti C, Marmorino F, Pennati M, et al. Circulating angiogenesis-related markers as predictors of benefit from regorafenib in metastatic colorectal cancer (mCRC) patients (pts). *Ann Oncol* 2017;28(Suppl 6):vi4.
- [15] Kumar H, Heer K, Lee PW, et al. Preoperative serum vascular endothelial growth factor can predict stage in colorectal cancer. *Clin Cancer Res* 1998;4:1279–85.
- [16] Loupakis F, Cremolini C, Fioravanti A, et al. Pharmacodynamic and pharmacogenetic angiogenesis-related markers of first-line FOLFOXIRI plus bevacizumab schedule in metastatic colorectal cancer. *Br J Cancer* 2011;104:1262–9.
- [17] Mashima T, Ushijima M, Matsuura M, et al. Comprehensive transcriptomic analysis of molecularly targeted drugs in cancer for target pathway evaluation. *Cancer Sci* 2015;106:909–20.
- [18] Suenaga M, Mashima T, Kawata N, et al. Serum VEGF-A and CCL5 levels as candidate biomarkers for efficacy and toxicity of regorafenib in patients with metastatic colorectal cancer. *Oncotarget* 2016;7:34811–23.
- [19] Tabernero J, Lenz HJ, Siena S, et al. Analysis of circulating DNA and protein biomarkers to predict the clinical activity of regorafenib and assess prognosis in patients with metastatic colorectal cancer: a retrospective, exploratory analysis of the CORRECT trial. *Lancet Oncol* 2015;16:937–48.
- [20] Ricotta R, Verrioli A, Ghezzi S, et al. Radiological imaging markers predicting clinical outcome in patients with metastatic colorectal carcinoma treated with regorafenib: post hoc analysis of the CORRECT phase III trial (RadioCORRECT study). *ESMO Open* 2017;1:e000111.
- [21] Lim Y, Bang JI, Han SW, et al. Total lesion glycolysis (TLG) as an imaging biomarker in metastatic colorectal cancer patients treated with regorafenib. *Eur J Nucl Med Mol Imaging* 2017;44:757–64.