

## Case Report

# A case of ruptured infectious anterior cerebral artery aneurysm treated by interposition graft bypass using the superficial temporal artery

Takatsugu Abe, Hidenori Endo, Hiroaki Shimizu<sup>1</sup>, Miki Fujimura<sup>2</sup>, Toshiki Endo, Hiroyuki Sakata, Mika Watanabe<sup>3</sup>, Teiji Tominaga<sup>2</sup>

Department of Neurosurgery, Kohnan Hospital, <sup>2</sup>Department of Neurosurgery, Tohoku University Graduate School of Medicine, <sup>3</sup>Department of Pathology, Tohoku University Graduate School of Medicine, Sendai, <sup>1</sup>Department of Neurosurgery, Akita University Graduate School of Medicine, Akita, Japan

E-mail: Takatsugu Abe - [tabe.rugmed@gmail.com](mailto:tabe.rugmed@gmail.com); \*Hidenori Endo - [hideendo@gmail.com](mailto:hideendo@gmail.com); Hiroaki Shimizu - [hshim@nsg.med.akita-u.ac.jp](mailto:hshim@nsg.med.akita-u.ac.jp); Miki Fujimura - [fujimur@nsg.med.tohoku.ac.jp](mailto:fujimur@nsg.med.tohoku.ac.jp); Toshiki Endo - [endo@nsg.med.tohoku.ac.jp](mailto:endo@nsg.med.tohoku.ac.jp); Hiroyuki Sakata - [sakata@nsg.med.tohoku.ac.jp](mailto:sakata@nsg.med.tohoku.ac.jp); Mika Watanabe - [mkawatan@patholo2.med.tohoku.ac.jp](mailto:mkawatan@patholo2.med.tohoku.ac.jp); Teiji Tominaga - [tomi@nsg.med.tohoku.ac.jp](mailto:tomi@nsg.med.tohoku.ac.jp)  
\*Corresponding author

Received: 07 October 15 Accepted: 25 November 15 Published: 06 January 16

## Abstract

**Background:** To describe the application of an interposition graft bypass using superficial temporal artery (STA) for the treatment of a ruptured anterior cerebral artery (ACA) infectious aneurysm.

**Case Description:** A 30-year-old male suffered from severe headache with high fever. The patient's diagnosis was ruptured infectious ACA aneurysm at the A3 segment with a maximum diameter of 4.5 mm, caused by infectious endocarditis. The patient was initially treated with high-dose intravenous antibiotics. Follow-up digital subtraction angiography (DSA) revealed that the fusiform aneurysm had enlarged to a maximum diameter of 14.0 mm. A left paracentral artery, supplying the motor area of the left lower extremity, originated from the body of this aneurysm. Because the angiographic findings suggested a risk of recurrent bleeding, the patient underwent open surgery. Interposition graft bypass using the STA was performed to reconstruct the left A3 segment in an end-to-side manner (left proximal callosomarginal artery – STA graft – left distal pericallosal artery). Then, the origin of the left paracentral artery was cut and anastomosed to the STA graft in an end-to-side manner. The affected parent artery was trapped, and the aneurysm was resected. Postoperative magnetic resonance imaging showed no ischemic or hemorrhagic complications, and postoperative DSA revealed the patency of the interposition graft. Pathological diagnosis of the resected aneurysm revealed features corresponding to infectious cerebral aneurysm. The postoperative course was uneventful, and the patient was discharged without any neurological deficits.

**Conclusion:** In the treatment of infectious cerebral aneurysms, revascularization should be considered when the affected artery supplies the eloquent area. Interposition graft bypass using the STA is one of the options for revascularization surgery for the treatment of infectious ACA aneurysms.

**Key Words:** Anterior cerebral artery, infectious cerebral aneurysm, interposition graft bypass, subarachnoid hemorrhage, superficial temporal artery

### Access this article online

**Website:**

[www.surgicalneurologyint.com](http://www.surgicalneurologyint.com)

**DOI:**

10.4103/2152-7806.173319

**Quick Response Code:**

This is an open access article distributed under the terms of the Creative Commons Attribution-NonCommercial-ShareAlike 3.0 License, which allows others to remix, tweak, and build upon the work non-commercially, as long as the author is credited and the new creations are licensed under the identical terms.

**For reprints contact:** [reprints@medknow.com](mailto:reprints@medknow.com)

**How to cite this article:** Abe T, Endo H, Shimizu H, Fujimura M, Endo T, Sakata H, et al. A case of ruptured infectious anterior cerebral artery aneurysm treated by interposition graft bypass using the superficial temporal artery. *Surg Neurol Int* 2016;7:5.

<http://surgicalneurologyint.com/A-case-of-ruptured-infectious-anterior-cerebral-artery-aneurysm-treated-by-interposition-graft-bypass-using-the-superficial-temporal-artery/>

## INTRODUCTION

Infectious cerebral aneurysm is relatively rare, accounting for 0.7–6.5% of all intracranial (IC) aneurysms.<sup>[5,8,9]</sup> It often arises in a distal segment of a cerebral artery rather than a proximal segment.<sup>[14]</sup> The middle cerebral artery (MCA) is the most favored site,<sup>[5,6,14]</sup> and fusiform aneurysms are dominant rather than saccular aneurysms.<sup>[6]</sup> Surgical intervention is necessary in cases with hemorrhagic onset or a growing aneurysm. Although open surgery has been considered the first-line treatment, endovascular intervention was recently reported to be also effective at curing the disease.<sup>[2,4,17]</sup> Open surgery is still an essential procedure when revascularization or mass removal is necessary.<sup>[10,14,15]</sup> When revascularization is necessary, it is useful to perform a typical extracranial (EC)-to-IC bypass using superficial temporal artery (STA) branches for most MCA lesions. However, EC-IC bypass is usually difficult in the case of anterior cerebral artery (ACA) lesions because the STA branches may not reach an objective artery at the deep interhemispheric fissure. Here, we report a case of ruptured infectious ACA aneurysm treated by interposition graft bypass using STA.

## CASE REPORT

A 30-year-old male was admitted to our hospital with complaints of a 3-day history of severe headache and high fever. On admission, he presented with disorientation, and his body temperature was higher than 39°C. Blood examination showed a white blood cell count of 12,200 cells/mm<sup>3</sup> and C-reactive protein of 1.22 mg/dl. A computed tomography scan revealed subarachnoid hemorrhage (SAH) with intracerebral hematoma, predominantly in the anterior interhemispheric fissure, and intraventricular hematoma [Figure 1a]. Initial digital subtraction angiography (DSA) demonstrated a fusiform aneurysm with an irregular shape on the left pericallosal artery, 4.5 mm in maximum diameter [Figure 1b]. He had cardiac noise on chest examination by stethoscope, and cardiologists finally diagnosed mitral insufficiency by further study. The detection of *Staphylococcus haemolyticus* in the blood culture led to a definite diagnosis of infective endocarditis (IE). Thus, the fusiform aneurysm of the left ACA was considered to be associated with this IE, and it was diagnosed as infectious cerebral aneurysm. He was initially treated with high-dose intravenous antibiotics (cefazolin 8 g/day and gentamicin 120 mg/day). However, follow-up DSA performed 20 days after the onset revealed the enlargement of the aneurysm to 14 mm in maximum diameter and vasospasm of the left pericallosal artery [Figure 1c]. We decided to perform surgery to prevent recurrent bleeding from the growing aneurysm. The left paracentral artery originated from the dome of this aneurysm, which would perfuse a motor area

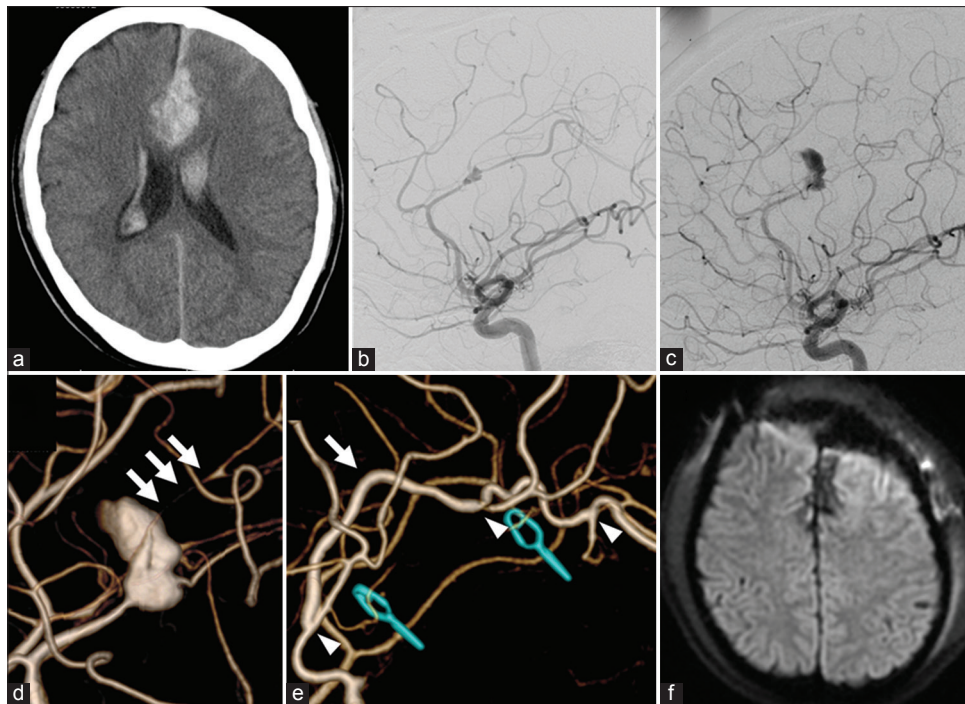
of the right lower limb [Figure 1d]. Thus, the aneurysm could not be occluded without revascularization.

Left frontal craniotomy was performed, and a proximal side of the A2 segment was initially found within the anterior interhemispheric fissure. We distally followed the ACA, and subsequently observed an old SAH. Then, we found the distal part of the A3 segment before approaching to the aneurysm. Considering the risk of premature rupture, we decided to create a bypass in advance of the dissection of the aneurysm. A frontal branch of the left STA, 8 cm in length, was harvested, and this STA was used as an interposition graft to reconstruct the left ACA in an end-to-side manner: Left callosomarginal artery (proximal side) – STA graft – left pericallosal artery (distal side) [Figure 2a and b]. Then, the origin of the left paracentral artery was cut and anastomosed to the STA graft in an end-to-side manner [Figure 2b]. The patency of the graft was confirmed by indocyanine green video angiography. After the creation of the bypass and trapping the parent artery, we went into a hematoma cavity and found the infectious aneurysm. We dissected the aneurysm from the surrounding tissue and then resected the aneurysm. Postoperative magnetic resonance imaging showed no ischemic or hemorrhagic complications, and postoperative DSA revealed the patency of the interposition graft [Figure 1e and f]. The postoperative course was uneventful, and the patient manifested no neurological deficits. The patient was thereafter treated for IE by a cardiologist.

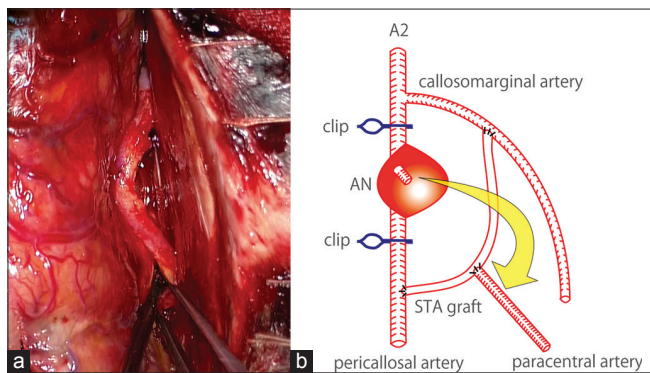
Hematoxylin-eosin stained sections and Elastica–Masson stained sections of the resected aneurysm corresponded to the features of an infectious cerebral aneurysm [Figure 3a]. A rupture of an arterial wall adjacent to the aneurysm had the appearance of a pseudo-aneurysm. The vascular media had become fibrotic, and the smooth muscle was thin. The vascular intima was globally hypertrophic and partially disappeared [Figure 3b]. No bacteria were detected in these sections, but the adventitia was invaded by many inflammatory cells [Figure 3c].

## DISCUSSION

The most common cause of infectious cerebral aneurysms is IE; approximately 65% of such cases are associated with IE.<sup>[5,6]</sup> By contrast, 3–6% of cases with IE have an infectious IC aneurysm.<sup>[6]</sup> Fusiform aneurysms are dominant rather than saccular aneurysms; 52.5% of infectious cerebral aneurysms manifest in a fusiform shape.<sup>[6]</sup> MCA is the most favored site; more than half of infectious cerebral aneurysms arise in the MCA region.<sup>[5,6,14]</sup> Peters *et al.* reported that 77% of infectious cerebral aneurysms occurred in the distal portion of the MCA, and 25% of these cases had multiple aneurysms.<sup>[14]</sup> The most likely mechanism of infectious aneurysm formation is the



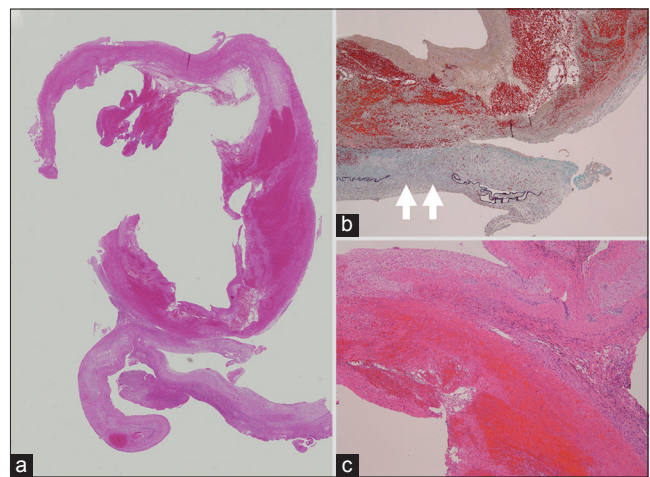
**Figure 1:** Primary computed tomography revealing subarachnoid hemorrhage and intracerebral hematoma predominantly in the anterior interhemispheric fissure (a). Initial digital subtraction angiography demonstrating a fusiform aneurysm of the left pericallosal artery (b). Follow-up digital subtraction angiography performed 20 days after the bleeding revealing enlargement of the aneurysm (c). Three-dimensional digital subtraction angiography indicating the paracentral artery originating from the aneurysmal sac (triple arrows) (d). Postoperative digital subtraction angiography showing disappearance of the aneurysm and patency of the interposition graft bypass. An arrow indicates the graft bypass. Left and right arrowheads indicate the anastomosis sites of the callosomarginal artery-superficial temporal artery-pericallosal artery bypass. Middle arrowhead indicates the anastomosis site of the superficial temporal artery-paracentral artery (e). Postoperative diffusion-weighted imaging showing no ischemic complications (f)



**Figure 2:** An intraoperative photograph showing the anastomosed superficial temporal artery graft (a). Illustration showing an interposition graft bypass using the superficial temporal artery (b)

embolization of septic particles to the arterial wall.<sup>[3,11]</sup> Bacteria in septic emboli escape through the vasa vasorum, resulting in severe inflammation of the adventitia and the inward spread of the infection.<sup>[3,11]</sup> The time interval from septic embolization to aneurysmal formation was found to be <24 h.<sup>[11]</sup>

The optimal treatment strategy for infectious cerebral aneurysm is still controversial because of its rarity. It is generally considered possible to manage unruptured infectious aneurysms with the administration of



**Figure 3:** H- and E-stained section of the resected aneurysm revealing features of a ruptured infectious pseudo-aneurysm (a). The arrows show vascular intima partially absent in an Elastic-Masson stained section (b). The adventitia of the resected anterior cerebral artery was invaded by many inflammatory cells in an H- and E-stained section (c)

antibacterial agents and sequential angiographic follow-up.<sup>[5,14]</sup> For a ruptured aneurysm, however, the mortality rate is increased up to 47% and this medical management is not appropriate.<sup>[14]</sup> When the patient's condition is stable without a potent hematoma or a

risk of ischemic complication, less invasive endovascular management can be a treatment of choice.<sup>[5,14]</sup> With the advancement of techniques and devices, endovascular therapy has recently been reported to be safe and effective for infectious cerebral aneurysms.<sup>[2,4,17]</sup> However, the presence of mass effects from a hematoma or the aneurysm itself is an indication for open surgery.<sup>[5,14]</sup> Furthermore, recent papers recommend revascularization surgery when it is necessary to occlude an affected artery supplying the eloquent area.<sup>[1,13]</sup>

In the present case, resection of the infectious ACA aneurysm with interposition graft bypass using the STA was successfully achieved without ischemic or hemorrhagic complications. In a previous report, ACA aneurysms requiring bypass were found to be rare.<sup>[1,18]</sup> There are no uniform methods for reconstructing the ACA in the treatment of complex ACA aneurysms because of their rarity and the considerable variation in aneurysmal location. Yokoh *et al.* reported three cases with complex anterior communicating artery aneurysm treated with reconstruction of the ACA.<sup>[18]</sup> They raised technical difficulty of the ACA reconstruction and indicated solutions to these problems regarding the extent of the operative exposure, limited mobility of the vessels and the feasibility of the anastomotic procedures. Abla and Lawton recently reviewed 29 articles on bypass surgery for ACA complex aneurysms with their experience of 10 cases.<sup>[1]</sup> In this review, IC-IC bypass was more frequently used than EC-IC bypass. EC-IC bypass is commonly used in the revascularization of the MCA territory. However, STA branches may not reach an objective artery at the deep interhemispheric fissure in the territory of ACA revascularization. It is necessary to use an interposition graft to anastomose the STA to the ACA in the interhemispheric fissure. Instead of EC-IC bypass, IC-IC bypass is the first-line treatment, which includes ACA-ACA *in situ* bypass, reanastomosis, reimplantation, and interposition graft bypass.<sup>[1]</sup> A3-A3 *in situ* bypass (side-to-side anastomosis) has been used most commonly. In the present case, it was necessary to reconstruct not only the main trunk of the ACA but also the paracentral artery. Thus, an interposition graft was considered more suitable than the other IC-IC bypass for reconstructing both arteries in terms of the mobility of the donor artery. Donor arteries for interposition bypass include a radial artery, saphenous vein, or STA.<sup>[1,7,12,16]</sup> A radial artery or saphenous vein graft, which is much longer than an STA graft, is useful for reconstructing a long gap. However, the vascular caliber of the ACA is similar to that of the STA, which is one of the main reasons why we used the STA as a graft.

For infectious cerebral aneurysms, the safety of an interposition graft bypass is unknown. There have been only two reported cases treated with IC-IC interposition graft bypass.<sup>[1,13]</sup> In the first case, A2-A3 interposition graft bypass using the radial artery was conducted for an

A2-A3 infectious aneurysm.<sup>[1]</sup> In the second case, a short segment MCA-MCA jump graft bypass using an STA graft was conducted for an M3 infectious aneurysm.<sup>[13]</sup> The present case is the first report of successful treatment with an interposition graft bypass using the STA for the treatment of an infectious ACA aneurysm. This report could indicate the safety and efficacy of free graft use in the revascularization for infectious cerebral aneurysms.

## CONCLUSION

Revascularization should be considered when the affected artery supplies the eloquent area in the treatment of infectious cerebral aneurysms. In this setting, interposition graft bypass using the STA is one of the options for revascularization surgery in the ACA territory.

## Financial support and sponsorship

Nil.

## Conflicts of interest

There are no conflicts of interest.

## REFERENCES

1. Abla AA, Lawton MT. Anterior cerebral artery bypass for complex aneurysms: An experience with intracranial-intracranial reconstruction and review of bypass options. *J Neurosurg* 2014;120:1364-77.
2. Appelboom G, Kadri K, Hassan F, Leclerc X. Infectious aneurysm of the cavernous carotid artery in a child treated with a new-generation of flow-diverting stent graft: Case report. *Neurosurgery* 2010;66:E623-4.
3. Bohmfalk GL, Story JL, Wissinger JP, Brown WE Jr. Bacterial intracranial aneurysm. *J Neurosurg* 1978;48:369-82.
4. Chapot R, Houdart E, Saint-Maurice JP, Aymard A, Mounayer C, Lot G, *et al.* Endovascular treatment of cerebral mycotic aneurysms. *Radiology* 2002;222:389-96.
5. Chun JY, Smith W, Halbach VV, Higashida RT, Wilson CB, Lawton MT. Current multimodality management of infectious intracranial aneurysms. *Neurosurgery* 2001;48:1203-13.
6. Ducruet AF, Hickman ZL, Zacharia BE, Narula R, Grobelny BT, Gorski J, *et al.* Intracranial infectious aneurysms: A comprehensive review. *Neurosurg Rev* 2010;33:37-46.
7. Gelfenbeyn M, Natarajan SK, Sekhar LN. Large distal anterior cerebral artery aneurysm treated with resection and interposition graft: Case report. *Neurosurgery* 2009;64:E1008-9.
8. Kannoth S, Thomas SV. Intracranial microbial aneurysm (infectious aneurysm): Current options for diagnosis and management. *Neurocrit Care* 2009;11:120-9.
9. Kuo I, Long T, Nguyen N, Chaudry B, Karp M, Sanossian N. Ruptured intracranial mycotic aneurysm in infective endocarditis: A natural history. *Case Rep Med* 2010;2010. pii: 168408.
10. Matsubara N, Miyachi S, Izumi T, Yamanouchi T, Asai T, Ota K, *et al.* Results and current trends of multimodality treatment for infectious intracranial aneurysms. *Neurol Med Chir (Tokyo)* 2015;55:155-62.
11. Molinari GF, Smith L, Goldstein MN, Satran R. Pathogenesis of cerebral mycotic aneurysms. *Neurology* 1973;23:325-32.
12. Mura J, Riquelme F, Cuevas JL, Luna F, Vizhñay P. Simplified azygos anterior cerebral bypass: Y-shaped superficial temporal artery interposition graft from A2 with double reimplantation of pericallosal arteries: Technical case report. *Neurosurgery* 2013;72 (2 Suppl Operative):OnsE235-40.
13. Nussbaum L, Defillo A, Zelensky A, Nussbaum ES. A short segment intracranial-intracranial jump graft bypass followed by proximal arterial

- occlusion for a distal MCA aneurysm. *Surg Neurol Int* 2011;2:98.
14. Peters PJ, Harrison T, Lennox JL. A dangerous dilemma: Management of infectious intracranial aneurysms complicating endocarditis. *Lancet Infect Dis* 2006;6:742-8.
  15. Phuong LK, Link M, Wijdicks E. Management of intracranial infectious aneurysms: A series of 16 cases. *Neurosurgery* 2002;51:1145-51.
  16. Terasaka S, Satoh M, Echizenya K, Murai H, Fujimoto S, Asaoka K. Revascularization of the anterior cerebral artery using a free superficial temporal artery graft: A case report. *Surg Neurol* 1997;48:164-9.
  17. Yen PS, Teo BT, Chen SC, Chiu TL. Endovascular treatment for bilateral mycotic intracavernous carotid aneurysms. Case report and review of the literature. *J Neurosurg* 2007;107:868-72.
  18. Yokoh A, Ausman JI, Dujovny M, Diaz FG, Berman SK, Sanders J, et al. Anterior cerebral artery reconstruction. *Neurosurgery* 1986;19:26-35.