

Discrepancy between Multiparametric Magnetic Resonance Imaging and ⁶⁸Ga Prostate-Specific Membrane Antigen Positron Emission Tomography: A Simultaneous Acquired Positron Emission Tomography-Magnetic Resonance Imaging Case

Abstract

Conventionally, multiparametric magnetic resonance imaging (mpMRI) incorporating T2-weighted, diffusion-weighted, and dynamic contrast-enhanced sequences is considered the standard for detection and staging of clinically important prostate cancer (PCa).^[1] The ⁶⁸Ga gallium (⁶⁸Ga)-labeled positron emission tomography (PET) tracer targeting prostate-specific membrane antigen (PSMA), ⁶⁸Ga-PSMA PET, is a promising tool for detection, localization, and staging carcinoma prostate.^[2] Here, we present a case of PCa, showing incongruence between ⁶⁸Ga-PSMA PET and the corresponding mpMRI findings. Moreover, the final histopathology revealed a surprise, which exemplifies the complementary nature of combining ⁶⁸Ga-PSMA PET and mpMRI in the diagnosis and staging of carcinoma prostate.

Keywords: ⁶⁸Ga-prostate-specific membrane antigen, multiparametric magnetic resonance imaging, positron emission tomography-magnetic resonance imaging, prostate cancer

Introduction

Prostate-specific membrane antigen (PSMA) is a Type II transmembrane glycoprotein that is highly expressed in almost all prostate cancer (PCa) cells, with only 5%–10% of primary PCa not having PSMA expression.^[3] ⁶⁸Ga PSMA positron emission tomography (PET) is considered a highly sensitive and specific study for assessing soft-tissue and skeletal metastases in high-risk PCa,^[4,5] and its positivity directly correlates with tumor stage/grade, serum prostate-specific antigen (PSA) levels, and PSA doubling time.^[3] Multiparametric magnetic resonance imaging (mpMRI) has gained much interest in recent years, both as a diagnostic test for PCa and for monitoring men with localized PCa on active surveillance.^[5] MRI provides precise morphologic evaluation and has higher spatial resolution and provides clearer anatomic delineation of the prostatic fossa and the surrounding anatomical structures.^[6] Although both these imaging modalities are capable of identifying primary/metastatic PCa, they have their own shortcomings, which is where PET-MRI scores as a one-stop-shop for the

evaluation of PCa, by bringing together the best of both these modalities.

Case Report

A 73-year-old gentleman presented with a history of lower urinary tract symptoms including increased urine frequency and weak stream for 3 years. The patient was initially diagnosed as benign prostatic hyperplasia (BPH) and started on alpha blockers. Recent serum PSA level was found to be 17.53 ng/mL. The patient underwent a transrectal ultrasound-guided (TRUS) biopsy, which was reported as acinar adenocarcinoma of prostate with Gleason's score 3 + 4 = 7, involving the right lateral apex region.

The patient subsequently underwent a ⁶⁸Ga gallium (⁶⁸Ga)-PSMA whole-body PET MRI scan (which included a regional mpMRI) for localization and staging of the disease. 4.4 mCi/162.8 MBq of ⁶⁸Ga-PSMA was injected intravenously. One hour later, whole-body PET MRI (head to mid-thigh) was performed on a Siemens Biograph mMR PET (Erlangen, Germany) with 3 Tesla MRI system.

Naveen Jose Moolan, Vijay Harish Somasundaram, Bindu Mangalath Rajamma¹, Palaniswamy Shanmugha Sundaram

Departments of Nuclear Medicine and Molecular Imaging and ¹Pathology, Amrita Institute of Medical Sciences, Kochi, Kerala, India

Address for correspondence:

Dr. Vijay Harish Somasundaram, Department of Nuclear Medicine and Molecular Imaging, Amrita Institute of Medical Sciences, Kochi, Kerala, India. E-mail: vijayharish@gmail.com

Received: 29-05-2020

Revised: 28-07-2020

Accepted: 29-07-2020

Published: 04-03-2021

Access this article online

Website: www.ijnm.in

DOI: 10.4103/ijnm.IJNM_115_20

Quick Response Code:



How to cite this article: Moolan NJ, Somasundaram VH, Rajamma BM, Sundaram PS. Discrepancy between multiparametric magnetic resonance imaging and ⁶⁸Ga prostate-specific membrane antigen positron emission tomography: A simultaneous acquired positron emission tomography-magnetic resonance imaging case. Indian J Nucl Med 2021;36:50-2.

This is an open access journal, and articles are distributed under the terms of the Creative Commons Attribution-NonCommercial-ShareAlike 4.0 License, which allows others to remix, tweak, and build upon the work non-commercially, as long as appropriate credit is given and the new creations are licensed under the identical terms.

For reprints contact: reprints@medknow.com

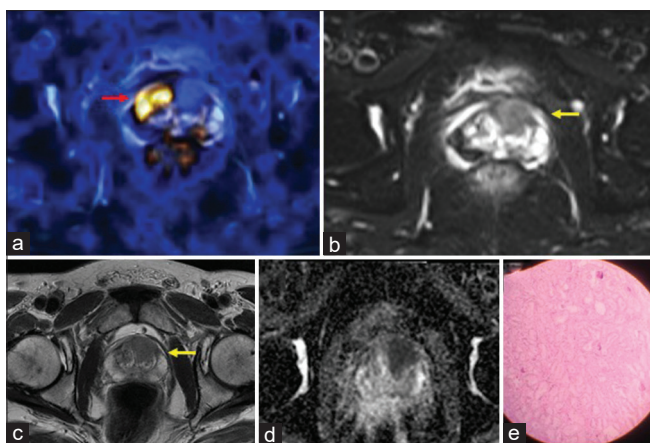


Figure 1: (a) ⁶⁸Gallium-prostate-specific membrane antigen positron emission tomography image fused with the corresponding T2-weighted magnetic resonance imaging (b) showing focal tracer uptake (red arrow) on the side opposite to the magnetic resonance imaging-detected hypointense lesion (yellow arrow). While no obvious magnetic resonance imaging lesion is seen corresponding to the prostate-specific membrane antigen uptake. (c) T2-weighted magnetic resonance imaging of prostate showing a hypointense nodule involving the left anterior and posterior transitional zone at the base with low ADC values (d). (e) Hematoxylin and eosin-stained specimen of radical prostatectomy showing the acinar adenocarcinoma (from both right and left lobe transition zones)

PET-MRI images [Figure 1] revealed a focal ⁶⁸Ga-PSMA uptake in the right transitional zone of the prostate gland involving the midgland and apex regions (red arrow). Although this focus appeared to correlate with the TRUS biopsy site, there was no corresponding MRI detected abnormality. However, the images did show a different T2 hypointense nodule involving the left anterior and posterior transitional zones of the base and midgland regions (yellow arrow). This nodule was ⁶⁸Ga-PSMA nonavid, yet showed strong diffusion restriction with low ADC values along with early contrast enhancement.

The patient underwent robot-assisted radical prostatectomy with bilateral pelvic lymph nodal dissection. Histopathology (HPR) was reported as prostatic acinar adenocarcinoma with Gleason's score of 4 + 3 = 7. Both lobes of the prostate were involved by the tumor (60%–65% of the gland involved), which was seen extending from the base to the apex, with a small focus of extraprostatic extension.

Discussion

Currently, apart from digital rectal examination (DRE) and serum PSA levels, TRUS and mpMRI play an important role in the diagnosis and staging of PCa.^[7] mpMRI has been extensively evaluated as a diagnostic tool, particularly T-staging.^[6] Postbiopsy hemorrhage is one of the primary causes of false negatives on mpMRI, which is why biopsies are routinely planned after imaging. Conditions which may sometimes produce false-positive results on mpMRI include normal anterior fibromuscular stroma and central zones producing low signals, stromal BPH resembling PCa, and acute/chronic prostatitis.^[8] Although the sensitivity

of ⁶⁸Ga-PSMA has been reported to be ≈97%, especially PSA ≥2 ng/ml, its expression is affected by the tumor grade, with low-grade tumors having a lower expression.^[9] While false positives arise due to inflammatory conditions and sometimes even in BPH. The current case is a likely example of tumor heterogeneity producing the differential uptake in ⁶⁸Ga-PSMA.

Few earlier studies suggest that ⁶⁸Ga PSMA PET provides better detection of intraprostatic lesions, with a better sensitivity than that of mpMRI, but with similar specificity.^[10,11] The greatest advantage of mpMRI is its superior anatomic detail and detection of possible extracapsular/seminal vesicle invasion. Due to this, the utility of ⁶⁸Ga PSMA PET in staging primary PCa has sometimes been considered to be “limited.”^[12] With this example, we intend to highlight that no one single imaging modality can be considered perfect, and combining these complementary imaging modalities is always advantageous.

Declaration of patient consent

The authors certify that they have obtained all appropriate patient consent forms. In the form the patient (s) has/have given his/her/their consent for his/her/their images and other clinical information to be reported in the journal. The patients understand that their names and initials will not be published and due efforts will be made to conceal their identity, but anonymity cannot be guaranteed.

Financial support and sponsorship

Nil.

Conflicts of interest

There are no conflicts of interest.

References

- Muehlematter UJ, Rupp NJ, Mueller J, Eberli D, Burger IA. ⁶⁸Ga-PSMA PET/MR-positive, histopathology-proven prostate cancer in a patient with negative multiparametric prostate MRI. *Clin Nucl Med* 2018;43:e282-4.
- Grubmüller B, Baltzer P, Hartenbach S, D'Andrea D, Helbich TH, Haug AR, et al. PSMA ligand PET/MRI for primary prostate cancer: Staging performance and clinical impact. *Clin Cancer Res* 2018;24:6300-7.
- Schwarzenboeck SM, Rauscher I, Bluemel C, Fendler WP, Rowe SP, Pomper MG, et al. PSMA ligands for PET imaging of prostate cancer. *J Nucl Med* 2017;58:1545-52.
- Kuten J, Mabeesh NJ, Lerman H, Levine C, Barnes S, Even-Sapir E. Ga-PSMA PET/CT Staging of newly diagnosed intermediate- and high-risk prostate cancer. *Isr Med Assoc J* 2019;21:100-4.
- Maurer T, Gschwend JE, Rauscher I, Souvatzoglou M, Haller B, Weirich G, et al. Diagnostic Efficacy of (68)Gallium-PSMA Positron Emission Tomography Compared to Conventional Imaging for Lymph Node Staging of 130 Consecutive Patients with Intermediate to High Risk Prostate Cancer. *J Urol* 2016;195:1436-43.
- Hoeks CM, Barentsz JO, Hambrock T, Yakar D, Somford DM, Heijmink SW, et al. Prostate cancer: Multiparametric MR

- imaging for detection, localization, and staging. *Radiology* 2011;261:46-66.
7. Jones D, Friend C, Dreher A, Allgar V, Macleod U. The diagnostic test accuracy of rectal examination for prostate cancer diagnosis in symptomatic patients: A systematic review. *BMC Fam Pract* 2018;19:79.
 8. Quon JS, Moosavi B, Khanna M, Flood TA, Lim CS, Schieda N. False positive and false negative diagnoses of prostate cancer at multi-parametric prostate MRI in active surveillance. *Insights Imaging* 2015;6:449-63.
 9. Mottet N, Bellmunt J, Bolla M, Briers E, Cumberbatch MG, De Santis M, *et al.* EAU-ESTRO-SIOG Guidelines on Prostate Cancer. Part 1: Screening, Diagnosis, and Local Treatment with Curative Intent. *Eur Urol* 2017;71:618-29.
 10. Berger I, Annabattula C, Lewis J, Shetty DV, Kam J, Maclean F, *et al.* ⁶⁸Ga-PSMA PET/CT vs. mpMRI for locoregional prostate cancer staging: Correlation with final histopathology. *Prostate Cancer Prostatic Dis* 2018;21:204-11.
 11. Zamboglou C, Drendel V, Jilg CA, Rischke HC, Beck TI, Schultze-Seemann W, *et al.* Comparison of ⁶⁸Ga-⁶⁸Ga-HBED-CCPSMA-PET/CT and multiparametric MRI for gross tumour volume detection in patients with primary prostate cancer based on slice by slice comparison with histopathology. *Theranostics* 2017;7:228-37.
 12. Tulsyan S, Das C, Tripathi M, Seth A, Kumar R, Bal CS. Comparison of ⁶⁸Ga-PSMA PET/CT and multiparametric MRI for staging of high-risk prostate cancer. *Nucl Med Communicat* 2017;38:1.