



## Case Report

# Endovascular vertebral artery orifice angioplasty for the prevention of acute ischemic stroke following vertebral artery stump syndrome

Ai Okamoto, Ichiro Nakagawa, Masashi Kotsugi, Shohei Yokoyama, Shuichi Yamada, Young-Soo Park<sup>ORCID</sup>, Hiroyuki Nakase

Department of Neurosurgery, Nara Medical University, Kashihara, Japan.

E-mail: Ai Okamoto - aiokamoto@narmed-u.ac.jp; \*Ichiro Nakagawa - nakagawa@narmed-u.ac.jp; Masashi Kotsugi - igustok@narmed-u.ac.jp; Shohei Yokoyama - shoheidon1182@gmail.com; Shuichi Yamada - syamada@narmed-u.ac.jp; Young-Soo Park - park-y-s@narmed-u.ac.jp; Hiroyuki Nakase - nakasehi@narmed-u.ac.jp

### \*Corresponding author:

Ichiro Nakagawa,  
Department of Neurosurgery,  
Nara Medical University,  
Kashihara, Japan.

[nakagawa@narmed-u.ac.jp](mailto:nakagawa@narmed-u.ac.jp)

Received : 04 June 2022

Accepted : 06 August 2022

Published : 26 August 2022

### DOI

10.25259/SNI\_515\_2022

### Quick Response Code:



## ABSTRACT

**Background:** Vertebral artery stump syndrome (VASS) involves repeated acute ischemic stroke (AIS) in the posterior circulation following vertebral artery (VA) orifice occlusion. The presence of VA orifice occlusion makes endovascular thrombectomy (EVT) difficult to achieve and leads to posterior circulation stroke with unfavorable functional outcomes. Here, we report a case of endovascular VA orifice angioplasty for the right VA pseudo-occlusion to prevent AIS following VASS pathology.

**Case Description:** In a 76-year-old man presenting with dizziness, angiography revealed right pseudo-occluded VA at the origin concomitant with the left VA occlusion. The posterior circulation depended on the right VA through collateral flow to the distal portion. Prophylactic endovascular VA angioplasty for the right pseudo-occluded VA at the orifice was achieved to prevent AIS with tandem lesions. In the present case, endovascular VA angioplasty can prevent acute embolic stroke in the posterior circulation following EVT-resistant VASS pathology.

**Conclusion:** Clinicians should be aware that EVT is not easy in AIS following VASS due to access difficulties and the treatment strategy should be carefully considered.

**Keywords:** Acute ischemic stroke, Endovascular angioplasty, Mechanical thrombectomy, Posterior circulation, Vertebral artery stump syndrome

## INTRODUCTION

Vertebral artery stump syndrome (VASS) is a pathophysiology in which embolic strokes develop in the posterior circulation due to stagnating clot fragments through collateral artery flow after vertebral artery (VA) occlusion.<sup>[6]</sup> Importantly, the presence of VA origin occlusion makes endovascular thrombectomy (EVT) difficult to achieve and leads to posterior circulation stroke with severe neurological deficit.<sup>[3]</sup> Although medical and endovascular therapies have been reported for VASS, no reports have described preventive endovascular VA orifice angioplasty for acute ischemic stroke (AIS) due to VASS. We report a case of endovascular angioplasty for the right VA pseudo-occlusion with the left VA occlusion to prevent AIS due to VASS.

## CASE REPORT

### History and examination

A 76-year-old man, with asymptomatic left VA stenosis noted on magnetic resonance angiography (MRA) 3 years earlier, presented with sudden dizziness. MRA showed left VA occlusion [Figure 1a] and no right VA orifice was depicted [Figure 1b]. He had a history of coronary artery disease and was on dual antiplatelet therapy.

He was referred to our department and showed no neurological deficits including dizziness on examination. Digital subtraction angiography showed right VA orifice pseudo-occlusion with faint anterograde flow [Figure 2a]. The right VA was reconstructed with distal inflow through collateral pathways through the deep cervical arteries [Figure 2b]. The left vertebral angiogram revealed left VA occlusion at the C2 level [Figure 2c] and the posterior communicating artery was not visualized on either right or left common carotid artery angiograms. The posterior circulation was mainly fed by the right VA through collateral pathways. Considering the high possibility of stagnating clot fragmentation in the collateral inflow area of the right VA, resulting in the pathogenesis of VASS causing posterior circulation embolic stroke, we decided to perform endovascular angioplasty for the right VA orifice pseudo-occlusion. Written informed consent was obtained from the patient before the intervention.

### Treatment

An 8-Fr OPTIMO balloon guiding catheter (Tokai Medical Products, Aichi, Japan) was positioned at the right subclavian artery near the right VA origin through right common femoral artery access under local anesthesia. A 0.014-inch microguidewire, ASAHI CHIKAI (Asahi Intecc Co. Ltd.,

Aichi, Japan) was passed through the pseudo-occluded VA ostium under guiding balloon inflation. Since near-infrared spectroscopy intravascular ultrasonography did not show a lipid core or mobile plaque, percutaneous transluminal angioplasty (PTA) was performed using a 2.5 mm balloon (Rapid cross: Medtronic, Minneapolis, USA) without distal protection. A balloon expandable bare-metal stent (4 mm diameter, 15 mm length, PALMAZ Genesis; Cordis, Dublin, Ireland) was placed [Figure 3a] because balloon PTA did not provide sufficient dilatation. The stent was postdilated with a 4 mm balloon (Aviator; Cordis) and good revascularization was obtained [Figure 3b]. Immediately after anterograde flow from the right VA origin, the reduction of collateral flow through deep cervical arteries was observed. Intracranial VA angiography showed good depiction of the posterior circulation without distal embolism [Figure 3c].

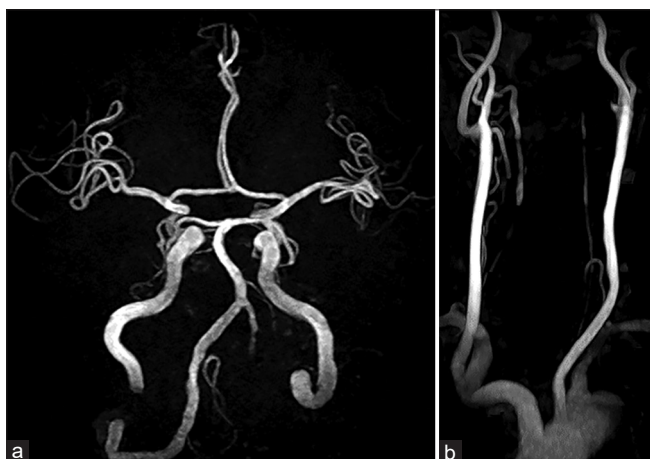### Postoperative course

Postoperative diffusion-weighted imaging showed only a single, small, and bright lesion in the left cerebellar hemisphere and the right VA was visualized well on MRA. He was discharged 8 days after treatment without neurological deficits. Postoperative ultrasonography showed good stent patency and anterograde flow through the right VA orifice at both 1 week and 3 months after treatment. No onset of VASS was seen at the 1-year follow-up and MRA showed no restenosis.

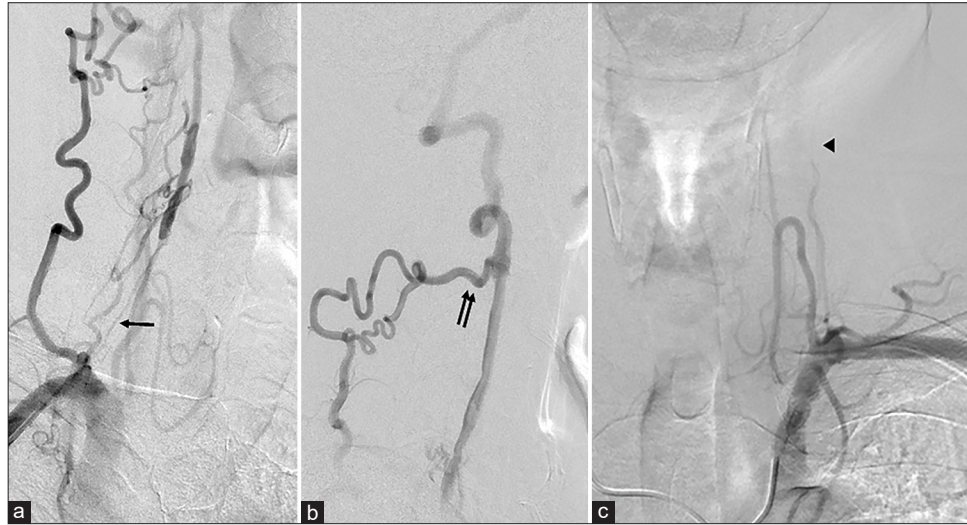
## DISCUSSION

We have reported successful endovascular VA orifice angioplasty for the prevention of acute embolic stroke in the posterior circulation following EVT-resistant VASS pathology.

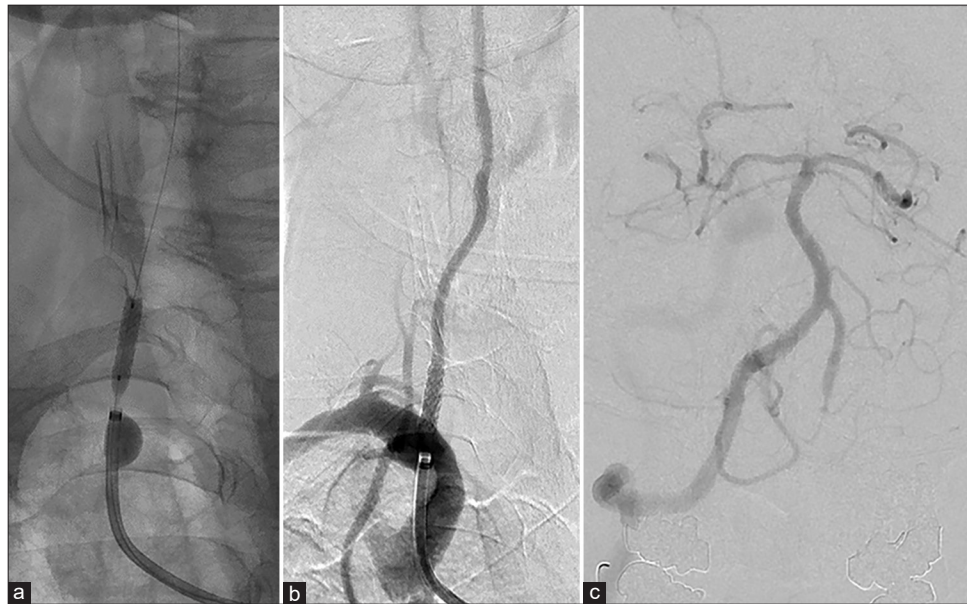Nguyen *et al.* first reported a syndrome of stroke in the posterior circulation after VA occlusion and named this phenomenon “vertebral stump syndrome” after the carotid artery stump and ongoing ischemic events despite the occluded artery.<sup>[6]</sup> Atherosclerotic stenosis of the VA is most frequently (93%) located at the origin.<sup>[5]</sup> The prevalence of VASS was 1.4% in patients with AIS in the posterior circulation and one-third of patients with VASS showed recurrence of ischemic stroke in the posterior circulation during hospitalization and poor prognosis.<sup>[3]</sup> The present case appeared to have been identified just before the onset of AIS with tandem lesions following VASS. The mechanism of VASS appears to be explainable as follows. After the VA is occluded, the distal limit of blood flow can cause propagated thrombus. A low-flow state and persistence of antegrade flow distal to the occlusion due to the collateral circulation may be associated with emboli from the stagnating clot fragment being transported to distal regions.<sup>[2,3,6,8]</sup> Suzuki *et al.* reported that spiral turbulent flow



**Figure 1:** (a) Cerebral magnetic resonance angiography (MRA) shows left vertebral artery (VA) occlusion. (b) Cervical MRA does not depict the right VA orifice.



**Figure 2:** (a) The right anterior oblique view of the vertebral artery (VA) angiogram shows pseudo-occlusion of the right VA orifice with faint antegrade flow (arrow). (b) Lateral view of the right VA lateral angiogram reveals that the right VA is reconstructed with a collateral pathway through the deep cervical arteries (double arrows). (c) The left subclavian angiogram reveals left VA occlusion at the C2 level (arrowhead).



**Figure 3:** (a) A balloon expandable bare-metal stent is placed at the vertebral artery (VA) origin. (b) Good revascularization is achieved after postballoon dilatation. (c) Intracranial VA angiogram shows good depiction of the posterior circulation without distal embolism.

and antegrade flow were observed on the distal side of the VA occlusion on ultrasonography, which may cause embolization. Turbulent flow can also cause platelet-fibrin aggregation and may theoretically lead to embolization.<sup>[8]</sup> Abnormalities in the blood flow, hypercoagulability of the blood, and injury to the vessel wall are related to thrombus formation.<sup>[2]</sup> In this manner, ischemic events from artery-to-artery embolization after vessel occlusion may recur, particularly in the absence

of any other embolic sources or coagulation fibrinolytic disorders. Analysis of case series of VA pseudo-occlusion with contralateral VA occlusion as in the present case may be helpful in understanding the progressive pathophysiology of VASS.

One of the treatments for acute cerebral infarction due to VASS is antiplatelet therapy with clopidogrel, together with intravenous infusion of ozagrel.<sup>[8]</sup> On the other hand,

Kawano *et al.* reported that the rate of relapse in patients receiving antiplatelet therapy was high compared to those receiving anticoagulation therapy, and they recommended anticoagulation therapy.<sup>[4]</sup> If these medical therapies fail, coil embolization to exclude the embolic source may be considered.<sup>[6]</sup> Nii *et al.* reported successful endovascular angioplasty of an extracranial VA occlusion without visualization of the stump of the artery ostium.<sup>[4]</sup> Chen *et al.* also reported endovascular revascularization of proximal extracranial VA occlusion with a technical success rate of 91.3% and a perioperative complication rate of 4.3%.<sup>[1]</sup> These reports indicate that recanalization of the occluded VA is technically possible, but in AIS following VASS, a VA orifice recanalization procedure would delay the time to recanalization of the tandem intracranial lesion and may lead to worse prognosis. In examples of acute embolic basilar artery occlusion (BAO) following VASS, revascularization must be achieved because the patients present with cranial nerve palsies, hemiplegia, tetraplegia, and coma, all of which are associated with high mortality rates. Maeoka *et al.* insisted that two of the 25 cases (8.0%) were diagnosed with embolic BAO due to VASS and clinicians must consider the possibility of acute BAO with VASS.<sup>[4]</sup> However, the presence of VA origin occlusion makes EVT difficult or impossible to perform, because piercing of the occlusive lesion when the origin of the VA is not visualized results in rupture or dissection of the VA, and stroke due to distal embolization.<sup>[7]</sup> Furthermore, the previous report summarized that BAO due to VASS was associated with major morbidity and a high mortality rate even if successful EVT was accomplished.<sup>[4]</sup> Preventing AIS itself is very important and making the access route to approach the embolic lesion also important in advance for AIS of the posterior circulation.

In this case, emergent EVT for intracranial tandem embolic arterial occlusion following VASS may not be achievable because of difficulties reaching the lesion. We, therefore, decided to perform endovascular VA orifice angioplasty for pseudo-occluded VA at the origin not only to prevent AIS following VASS but also to secure the access route for emergent EVT. Although this treatment was intended to prevent the development of AIS following VASS, prospective studies are required to determine whether this prophylactic VA orifice angioplasty treatment will improve the development of AIS and functional prognosis in patients with VA occlusive lesions.

## CONCLUSION

We report a case of endovascular VA orifice angioplasty for the prevention of AIS in the posterior circulation following

VASS. Clinicians should be aware that EVT is not easy in AIS following VASS due to access difficulties, and the treatment strategy should be carefully considered.

## Declaration of patient consent

The authors certify that they have obtained all appropriate patient consent.

## Financial support and sponsorship

Nil.

## Conflicts of interest

There are no conflicts of interest.

## REFERENCES

1. Chen L, Jiang Y, Hu F, He L, Zheng H. Endovascular revascularization of nonacute symptomatic proximal extracranial vertebral artery occlusion. *World Neurosurg* 2020;134:39-44.
2. Kawano H, Inatomi Y, Hirano T, Yonehara T, Uchino M. Anticoagulation therapy for vertebral artery stump syndrome. *J Neurol Sci* 2010;295:125-7.
3. Kawano H, Inatomi Y, Hirano T, Yonehara T. Vertebral artery stump syndrome in acute ischemic stroke. *J Neurol Sci* 2013;324:74-9.
4. Maeoka R, Nakagawa I, Ohnishi H, Kuga Y, Nakase H, Ohnishi H. A thread of hope for successful revascularization for acute embolic basilar artery occlusion due to miserable vertebral artery stump syndrome. A technical report. *J Clin Neurosci* 2020;73:299-303.
5. Moufarrij NA, Little JR, Furlan AJ, Williams G, Marzewski DJ. Vertebral artery stenosis: Long-term follow-up. *Stroke* 1984;15:260-3.
6. Nguyen TN, Raymond J, Mahmoud M, Weill A, Roy D, Guilbert F. Vertebral artery stump syndrome. *J Neurol Neurosurg Psychiatry* 2008;79:91-2.
7. Nii K, Abe G, Iko M, Nomoto Y, Yu I, Sakamoto K, *et al.* Endovascular angioplasty for extracranial vertebral artery occlusion without visualization of the stump of the artery ostium. *Neurol Med Chir (Tokyo)* 2013;53:422-6.
8. Suzuki M, Dembo T, Hara W, Tajima T, Yamashita M, Oji S, *et al.* Vertebral artery stump syndrome. *Intern Med* 2018;57:733-6.

**How to cite this article:** Okamoto A, Nakagawa I, Kotsugi M, Yokoyama S, Yamada S, Park Y, *et al.* Endovascular vertebral artery orifice angioplasty for the prevention of acute ischemic stroke following vertebral artery stump syndrome. *Surg Neurol Int* 2022;13:382.