


Portal Vein Thrombosis and Pyogenic Liver Abscess With Concomitant *Bacteroides* Bacteremia in a Patient With COVID-19 Infection: A Case Report and Brief Review

Journal of Investigative Medicine High Impact Case Reports
Volume 10: 1–4
© 2022 American Federation for Medical Research
DOI: 10.1177/23247096221084513
journals.sagepub.com/home/hic


George Trad, MD¹ , Nazanin Sheikhan, MD¹, Andrew Nguyen, DO¹, Jordan Valenta, DO¹, and Homayon Iraninezhad, DO¹

Abstract

The 2019 coronavirus disease (COVID-19) can present with a wide variety of clinical manifestations, including a hypercoagulable state leading to both arterial and venous thrombosis. Portal vein thrombosis (PVT) in the setting of COVID-19 has rarely been reported in the medical literature. Pylephlebitis with concomitant liver abscess is a rare complication of intra-abdominal infection. Here, we present the case of a 49-year-old man who initially presented with intermittent fevers and generalized weakness of 1-month duration and was subsequently found to have COVID-19 infection, PVT, and *Bacteroides fragilis* bacteremia with associated pyogenic liver abscess. The patient was treated with intravenous antibiotics and oral anticoagulation with plan to follow up outpatient with gastroenterology in 3 months to ensure resolution of PVT and liver abscess.

Keywords

gastroenterology, hematology oncology, pulmonary critical care, infectious disease

Introduction

The 2019 coronavirus disease (COVID-19) can manifest as a profoundly prothrombotic milieu, resulting in arterial and venous thrombosis.¹ The pathophysiology is not well understood, but theories include an amplified inflammatory response that leads to thromboinflammation via mechanisms such as cytokine storm, complement activation, and endotheliitis.¹ The pathophysiology behind portal vein thrombosis (PVT) development is multifactorial and can include malignancies, chronic liver disease, processes confined to the hepatobiliary system, and inherited and acquired thrombophilia.² Pylephlebitis is an infective suppurative thrombosis of the portal vein that has been associated with high morbidity and mortality rate.³ It occurs as a complication secondary to intra-abdominal infections such as diverticulitis or appendicitis. Abdominal pain and fever are the most common symptoms associated with pylephlebitis. Liver abscess is a pus collection in the liver that develops from hepatic injury or secondary to disseminated intra-abdominal infection via the portal circulation.⁴ Liver abscess can be formed secondary to pylephlebitis or vice versa.

Case Presentation

A 49-year-old male patient with no significant medical history presented to our emergency department with a 1-month history of intermittent fever, generalized weakness, sore throat, and myalgias. Prior to symptom onset, the patient had traveled to Hawaii where he reported drinking tap water but denied insect bites, eating exotic foods, or sick contacts. On initial presentation, vital signs were as follows: body temperature, 39.0°C; blood pressure, 128/82 mm Hg; heart rate, 130 beats/min; respiratory rate, 18 breaths/min; and oxygen saturation, 98% on room air. Physical examination was normal. Initial laboratory studies including complete blood

¹Mountain View Medical Center, Las Vegas, NV, USA

Received November 10, 2021. Revised January 17, 2022.
Accepted February 7, 2022.

Corresponding Author:

George Trad, MD, Department of Internal Medicine, Mountain View Medical Center, 3150 North Tenaya Way, Suite 300, Las Vegas, NV 89128, USA.

Email: georgetradmd@gmail.com



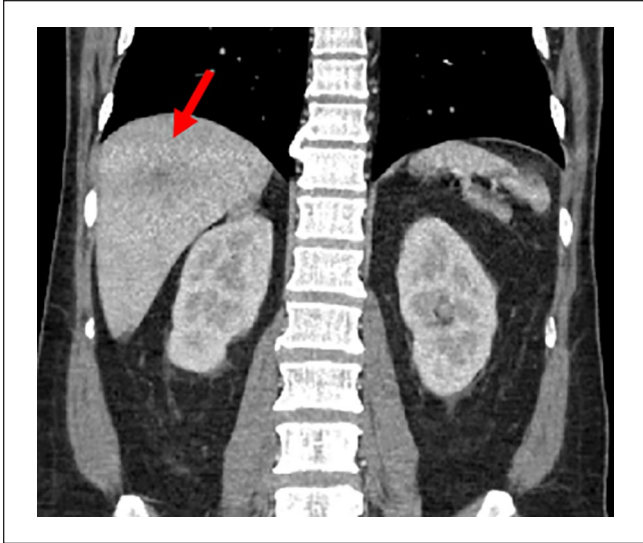

Figure 1. Computed tomography of the abdomen and pelvis showing a 6.2 cm × 5.2 cm mass in the posterior segment of the right hepatic lobe with an associated 1.6 cm central abscess.

count, chemistry panel, and hepatic function panel were notable for a white blood cell (WBC) of 15.0 k/ μ L with a neutrophilia of 88%, aspartate transaminase (AST) of 185 U/L, alanine transaminase (ALT) of 182 units/L, and alkaline phosphatase of 519 U/L. Chest x-ray (CXR) demonstrated minimal streaky airspace opacity within the right upper lung concerning for developing pneumonia. Peripheral blood cultures were obtained. Severe acute respiratory syndrome coronavirus 2 (SARS-CoV-2) rapid antigen test was positive. The constellation of clinical findings was attributed to COVID-19 pneumonia, and the patient was discharged home on azithromycin and amoxicillin/clavulanate.

Three days later, the patient was advised to return to the hospital for admission after 2 sets of peripheral blood cultures grew *Bacteroides fragilis*. The patient endorsed persistent subjective fevers. Vital signs on admission were as follows: body temperature, 36.7°C; blood pressure, 125/86 mm Hg, heart rate, 113 beats/min; respiratory rate, 16 breaths/min; and oxygen saturation, 98% on room air. Repeated laboratory studies including complete blood count, chemistry panel, and hepatic function panel were notable for a WBC of 8.8 k/ μ L, AST of 31 U/L, ALT of 108 U/L, and alkaline phosphatase of 593 U/L. Repeat CXR was negative for acute cardiopulmonary disease. The patient was started on intravenous piperacillin/tazobactam. Computed tomography (CT) of the abdomen and pelvis demonstrated (Figure 1) a 6.2 cm × 5.2 cm mass in the posterior segment of the right hepatic lobe with an associated 1.6 cm central abscess. The CT of the chest with intravenous contrast demonstrated focal atelectasis of the right upper lobe with no radiographic evidence of pneumonia. Abdominal ultrasound with pulsed and color Doppler demonstrated normal hepatopetal flow direction of the right, main, and left portal vein with no evidence

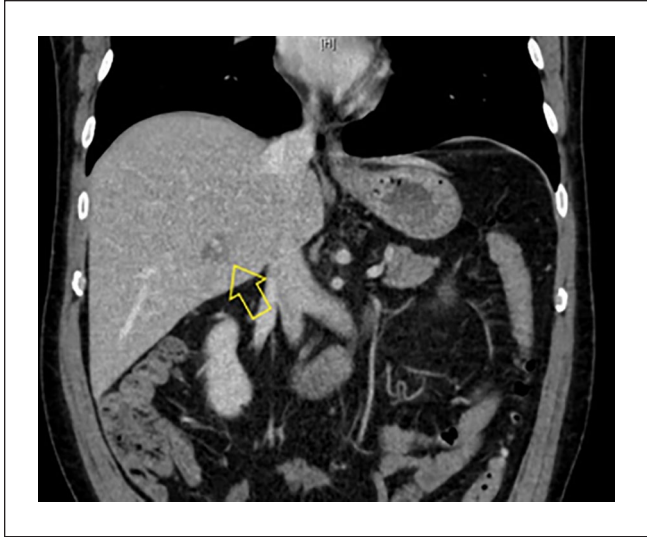

Figure 2. Computed tomography of the abdomen and pelvis demonstrated infiltrative lesion in the right lobe of the liver with thrombosis of the right portal vein.

of PVT. Transthoracic echocardiogram was negative for valvular vegetations. Repeat blood cultures remained negative. The patient received a peripherally inserted central catheter (PICC) and was discharged with a 6-week course of intravenous ertapenem.

Three days following discharge, the patient returned to the emergency department with complaints of persistent fevers, epigastric abdominal pain, and non-bloody diarrhea. Vital signs were within normal limits. Repeated laboratory studies including complete blood count, chemistry panel, and hepatic function panel were notable for a WBC of 5.8 k/ μ L, AST of 86 units/L, ALT of 156 units/L, and alkaline phosphatase of 338 units/L. The CT of the abdomen/pelvis (Figure 2) demonstrated infiltrative lesion in the right lobe of the liver with thrombosis of the right portal vein. Magnetic resonance imaging (MRI) of the abdomen (Figure 3) showed a 5 cm × 3.5 cm multiloculated hepatic abscess and thrombosis of the posterior branch of the right portal vein. Intravenous ertapenem therapy was continued and the patient was started on oral anticoagulation with apixaban. Repeat blood cultures showed no growth. The patient was ultimately discharged with a 6-week course of intravenous ertapenem and a 6-month course of apixaban with plan to follow up outpatient to ensure resolution of PVT and hepatic abscess. Follow-up contrast-enhanced abdominal CT at 8 months revealed resolution of PVT on apixaban therapy.

Discussion

Pylephlebitis is an infective suppurative thrombosis of the portal vein that is a rare and potentially fatal complication of intra-abdominal infections.⁵ Delay in diagnosis and management can lead to mortality rate as high as 25%.⁵ The most

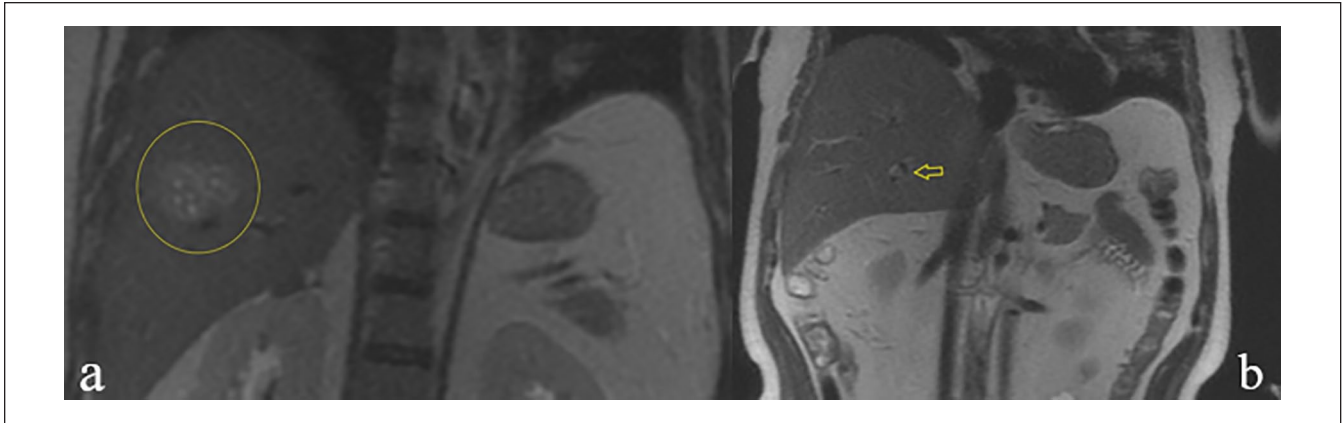


Figure 3. Magnetic resonance imaging of the abdomen showing a 5 cm × 3.5 cm multiloculated hepatic abscess (a) and thrombosis of the posterior branch of the right portal vein (b).

Table 1. Portal Vein Thrombosis in COVID-19 Infection Reported in the English Literature.

Authors	Age	Sex	Presenting symptoms	Diagnostic modality	Inpatient treatment	Outpatient treatment
Jafari et al ¹¹	26	Male	Respiratory distress, fatigue	Contrast-enhanced abdominal CT scan	Unfractionated heparin	Not reported
Franco-Moreno et al ¹²	27	Male	Abdominal pain	Contrast-enhanced abdominal CT scan	Enoxaparin	Acenocoumarol
Rehman et al ¹³	33	Female	Abdominal pain	Contrast-enhanced abdominal CT scan	Enoxaparin	Warfarin
Sinz et al ¹⁴	38	Male	Abdominal pain, nausea, diarrhea	Contrast-enhanced abdominal CT scan	Unfractionated heparin	Warfarin
Randhawa et al ¹⁵	62	Female	Abdominal pain, loss of appetite	Ultrasound abdomen, contrast-enhanced abdominal CT scan	Fondaparinux	Warfarin
Kolli and Oza ¹⁶	44	Female	Abdominal pain	Contrast-enhanced abdominal CT scan	Unfractionated heparin	Warfarin
Jeilani et al ¹⁷	68	Male	Abdominal pain	Contrast-enhanced abdominal CT scan	Dalteparin	Dalteparin

Abbreviation: CT = Computed tomography.

common etiology of pylephlebitis has been diverticulitis and appendicitis, while development of liver abscess has been seen as a complication that follows pylephlebitis.³ Liver abscess leading to PVT has been reported in the medical literature with rare occurrence.⁶ In terms of pathogens, *B fragilis* has been one of the main organisms associated with pylephlebitis. The presence of hypercoagulable state substantially increases the risk of venous thrombosis.⁶ COVID-19 results in a unique thrombotic state that increases the rate of both arterial and venous thrombosis.¹

On initial presentation, our patient was found to have a liver abscess on CT of the abdomen/pelvis. Ultrasound of the abdomen with Doppler flow was negative for PVT. Previous studies have shown that the sensitivity and specificity of PVT detection were 89% and 92%, respectively, with a false negative rate of 0.11 using abdominal ultrasound with Doppler.⁷ Repeat CT of the abdomen/pelvis 10 days later demonstrated PVT. Furthermore, on initial presentation to the emergency department, blood cultures grew *B fragilis*. Moreover, SARS-CoV-2 rapid antigen test was positive. All findings together with the patient's clinical presentation provided strong evidence that our patient developed a

multiloculated hepatic abscess attributable to *Bacteroides* bacteremia with subsequent pylephlebitis in the setting of COVID-19 infection and a hypercoagulable state.

Accumulative data since the beginning of the COVID-19 pandemic have demonstrated that COVID-19 infection is correlated to endothelial cell dysfunction with subsequent excessive thrombin generation, leading to a hypercoagulable state.⁸ Existing evidence-based guidelines recommend prophylactic anticoagulation in all acutely ill hospitalized patients with COVID-19 in the absence of contraindication.⁹ In the setting of PVT, low-molecular-weight heparin (LMWH) is the preferred treatment for patients without malignancy and with severe liver cirrhosis.¹⁰ In patients without malignancy or history of cirrhosis, the use of direct oral anticoagulants is safe and noninferior to LMWH.¹¹

Upon review of the English medical literature, several cases of PVT in the setting of COVID-19 infection have been reported since the beginning of the pandemic (Table 1). Review of the data reveals that the majority of patients were of younger age, with 6 out of 7 patients presenting with abdominal pain, with only 1 patient presenting with respiratory distress. It is also important to note that none of

the patients were hypoxic on initial presentation. Contrast-enhanced abdominal CT was the diagnostic modality of choice in all cases. All patients received therapeutic anticoagulation upon diagnosis and were ultimately discharged on at least 3 months of anticoagulation in the outpatient setting. Given these findings, it is worthwhile for clinicians to include PVT in the differential of patients presenting with abdominal pain in the setting of COVID-19 infection. We recommend obtaining abdominal imaging in critically ill patients with COVID-19 infection who suffer from abdominal pain, either as a presenting symptom or during hospitalization, as prompt treatment can render better outcomes.

Conclusion

The clinical presentation of SARS-CoV-2 infection is highly variable and ranges from asymptomatic carrier, mild upper respiratory infection, severe viral pneumonia, and respiratory failure with end-organ damage and death. The SARS-CoV-2 infection has been associated with a hypercoagulable state with subsequent arterial and venous thrombosis. This case report demonstrates that it is paramount for clinicians to maintain a high clinical suspicion to include pylephlebitis in the differential diagnosis of COVID-19 patients presenting with abdominal pain and fevers. Prompt treatment with anticoagulation and antibiotics is crucial given the high mortality rate if left untreated.

Declaration of Conflicting Interests

The author(s) declared no potential conflicts of interest with respect to the research, authorship, and/or publication of this article.

Funding

The author(s) disclosed receipt of the following financial support for the research, authorship, and/or publication of this article: This research was supported (in whole or in part) by HCA Healthcare and/or an HCA Healthcare affiliated entity. The views expressed in this publication represent those of the author(s) and do not necessarily represent the official views of HCA Healthcare or any of its affiliated entities.

Ethics Approval

Oou institution does not require ethical approval for reporting individual cases or case series.

Informed Consent

Written informed consent was obtained from the patient for their anonymized information to be published in this article.

ORCID iD

George Trad  <https://orcid.org/0000-0001-9702-4970>

References

1. Abou-Ismaïl MY, Diamond A, Kapoor S, et al. The hypercoagulable state in COVID-19: incidence, pathophysiology, and management. *Thromb Research V*. 2020;194:101-115.
2. Trebicka J, Strassburg CP. Etiology and complications of portal vein thrombosis. *Viszeralmedizin*. 2014;30(6):375-380.
3. Spelman D. *Pylephlebitis. UpToDate. Waltham, Mass.: UpToDate, 2021 . Pylephlebitis - UpToDate.* (accessed 10 August 2021).
4. Akhondi H, Sabih DE. Liver abscess. In: StatPearls. Treasure Island, FL: StatPearls Publishing. 2022, pp. 170–173.
5. Choudhry AJ, Baghdadi YMK, Amr MA, Alzghari MJ, Jenkins DH, Zielinski MD. Pylephlebitis: a review of 95 cases. *J Gastrointest Surg*. 2016;20(3):656-661.
6. Valla DC, Condat B. Portal vein thrombosis in adults: pathophysiology, pathogenesis and management. *J Hepatol*. 2000;32(5):865-871.
7. Tessler FN, Gehring BJ, Gomes AS, et al. Diagnosis of portal vein thrombosis: value of color Doppler imaging. *AJR Am J Roentgenol*. 1991;157(2):293-296.
8. Tang N, Bai H, Chen X, et al. Anticoagulant treatment is associated with decreased mortality in severe coronavirus disease 2019 patients with coagulopathy. *J Thromb Haemost*. 2020;18(5):1094-1099.
9. Moores LK, Tritschler T, Brosnahan S, et al. Prevention, diagnosis, and treatment of VTE in patients with coronavirus disease 2019: CHEST guideline and expert panel report. *Chest*. 2020;158(3):1143-1163.
10. Wu M, Schuster M, Tadros M. Update on management of portal vein thrombosis and the role of novel anticoagulants. *J Clin Transl Hepatol*. 2019;7(2):154-164.
11. Jafari S, Naseri R, Khalili N, et al. Portal vein thrombosis associated with COVID-19: points to consider. *BJR Case Rep*. 2020;6(3):20200089.
12. Franco-Moreno A, Piniella-Ruiz E, Montoya-Adarraga J, et al. Portal vein thrombosis in a patient with COVID-19. *Thrombosis Research*. 2020;194:150-152.
13. Rehman A, Thoppil A, Wallach S. Portal vein thrombosis and splenic infarction in a COVID-19 patient. *Cureus*. 2021;13(8):e16843.
14. Sinz S, Glaser-Gallion F, Steffen T. Portal vein thrombosis in COVID-19 infection. *Surg Case Rep*. 2021;7:87.
15. Randhawa J, Kaur J, Randhawa H, Kaur S, Singh H. Thrombosis of the portal vein and superior mesenteric vein in a patient with subclinical COVID-19 infection. *Cureus*. 2021;13(4):e14366.
16. Kolli S, Oza V. SARS-CoV-2 and portal vein thrombosis: a rare gastrointestinal manifestation of COVID-19. *Cureus*. 2021;13(4):e14340.
17. Jeilani M, Hill R, Riad M, Abdulaal Y. Superior mesenteric vein and portal vein thrombosis in a patient with COVID-19: a rare case. *BMJ Case Rep*. 2021;14(6):e244049.