



ELSEVIER

Contents lists available at [ScienceDirect](https://www.sciencedirect.com)

Trauma Case Reports

journal homepage: www.elsevier.com/locate/tcr

Severe fishhook-related ocular injury: A case series

Takashi Ono^{a,b,*}, Shigefumi Takahashi^a, Yosai Mori^a, Ryohei Nejima^a,
Takuya Iwasaki^a, Yasushi Kataoka^a, Takashi Miyai^b, Kazunori Miyata^a

^a Department of Ophthalmology, Miyata Eye Hospital, Miyakonojo, 6-3, Kuraharacho, Miyakonojo, Miyazaki 885-0051, Japan

^b Department of Ophthalmology, the University of Tokyo, 7-3-1, Hongo, Bunkyo-ku, Tokyo, Japan

ARTICLE INFO

Keywords:

Corneal perforation
Fishhook
Ocular injury
Posterior segment complication

ABSTRACT

This study examined the treatment, clinical course, and prognosis of two patients who visited our institution with severe ocular fishhook-related injuries with complications. The first patient was a 57-year-old man injured in the right eye by a fishhook lacerating the right upper eyelid. Although no aqueous humor leakage was observed, intraocular hemorrhage was severe, and the best-corrected visual acuity (BCVA) was “counting fingers” at 15 cm. The eyelid was sutured and vitreous surgery with cataract surgery was performed for traumatic cataract, vitreous hemorrhage, and retinal detachment. The patient experienced recurring iritis and the BCVA recovered to 20/100 eight months postoperatively. The second patient was a 62-year-old man who incurred a penetrating right-eye fishhook injury on a ship with BCVA of “hand motion.” The sclera and iris were ruptured with severe hemorrhage and a shallow anterior chamber without leakage of aqueous humor. A damaged lens and vitreous hemorrhage were observed with intraocular pressure of 38 mmHg. The ruptured sclera was sutured and vitreous surgery with lensectomy was performed. After 16 months, the BCVA improved to 20/40; however, glaucoma control was maintained by topical medication. Therefore, ocular fishhook-related injury could result in irreversible visual impairment. It is important to pay attention and protect the eyes from moving fishhooks during fishing.

Plain language summary: There are few reports on fishhook injury of the eye with resulting complications such as retinal detachment. We present the characteristics of the injury, treatment, clinical course, and prognosis of two patients with severe fishhook-related injuries of the eye with complications. Following treatment, most complications, including vitreous hemorrhage, detached lens, and retinal detachment, safely resolved in these cases; however, both patients required further treatment for recurring inflammation of the iris or glaucoma. The visual acuity of both patients improved over several months. Fishhook-related injuries of the eyes might result in irreversible visual impairment. It is important to pay attention and protect the eyes from moving fishhooks during fishing.

Introduction

Fishing is a major commercial industry and a popular recreational sport worldwide. Fishing is generally considered safe since it is

* Corresponding author at: Department of Ophthalmology, Miyata Eye Hospital, Miyakonojo, 6-3, Kuraharacho, Miyakonojo, Miyazaki 885-0051, Japan.

E-mail address: taono-ky@umin.ac.jp (T. Ono).

<https://doi.org/10.1016/j.tcr.2021.100574>

Accepted 5 December 2021

Available online 8 December 2021

2352-6440/© 2021 The Authors. Published by Elsevier Ltd. This is an open access article under the CC BY-NC-ND license

(<http://creativecommons.org/licenses/by-nc-nd/4.0/>).

not a contact sport; however, the incidence of fishhook-related dermatitis or penetrating soft tissue injuries is approximately 40% [1]. In ophthalmology, such injuries may occasionally result in serious visual loss owing to penetration of the fishhook into the eyelid [2] and/or cornea [3], reaching the retina [4]. Several previous studies have reported good visual prognoses in patients with corneal fishhook injury following prompt and proper treatment [3]. However, few reports have mentioned ocular fishhook injury with posterior segment complications, such as retinal detachment [4]. Since such injuries sometimes result in severe complications, detailed report of clinical course following the injury would be beneficial to clinicians. To examine the characteristics of the injury, treatment, clinical course, and prognosis of patients with severe ocular fishhook-related injuries with complications, we describe two such cases with posterior segment complications.

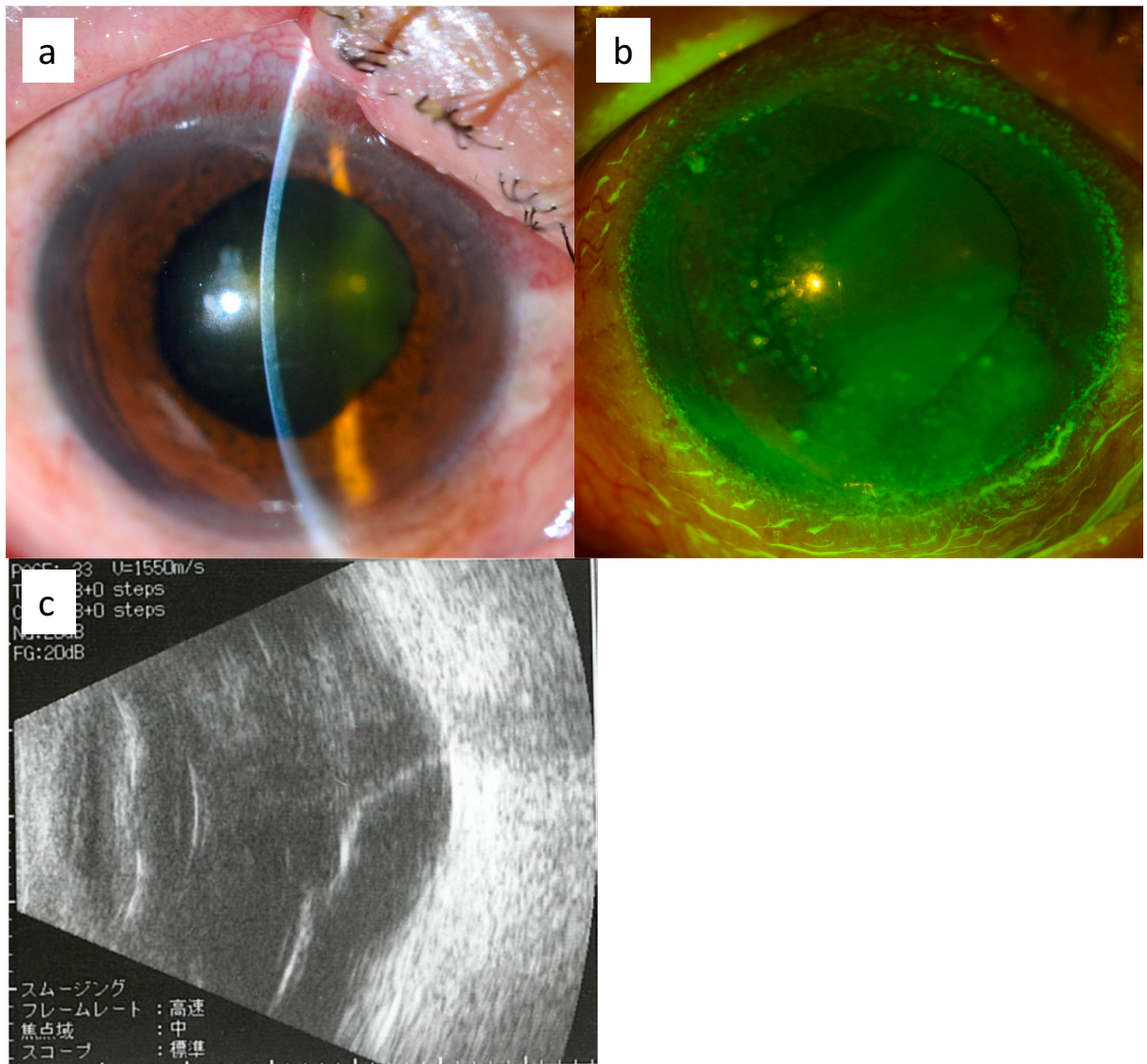


Fig. 1. Images of the right-eye anterior segment of a 57-year-old man who was injured by a fishhook.

- (a) Slit-lamp examination of the deep anterior chamber shows the thickened cornea, Descemet membrane folds, and hyperemia at the initial presentation.
 (b) No corneal epithelial defect or aqueous humor leakage observed after corneal fluorescein staining.
 (c) Vitreous hemorrhage and retinal detachment observed via echography.

Case reports

Case 1

A 57-year-old fisherman in a pelagic tuna fishing boat, suffered a right-eye injury by a tuna fishhook 2 weeks before visiting our clinic. The patient noticed a decrease in visual acuity and visited a local ophthalmologist in Ecuador. The patient was referred to our hospital after returning to Japan.

At the initial presentation, a painless lacerated wound was observed in the right upper eyelid. The anterior chamber was deep, and 2+ cell, 3+ flare, and Descemet membrane folds with hyperemia were observed (Fig. 1a). Fluorescein staining suggested no aqueous humor leakage (Fig. 1b). Gonioscopic examination identified recession of the iridocorneal angle and traumatic mydriasis. The best-corrected visual acuity (BCVA) was “counting fingers” at 15 cm, and the intraocular pressure (IOP) was 11 mmHg in the right eye. The BCVA remained 6/4 in the left eye. The fundus could not be observed due to intraocular hemorrhage. The upper eyelid wound was

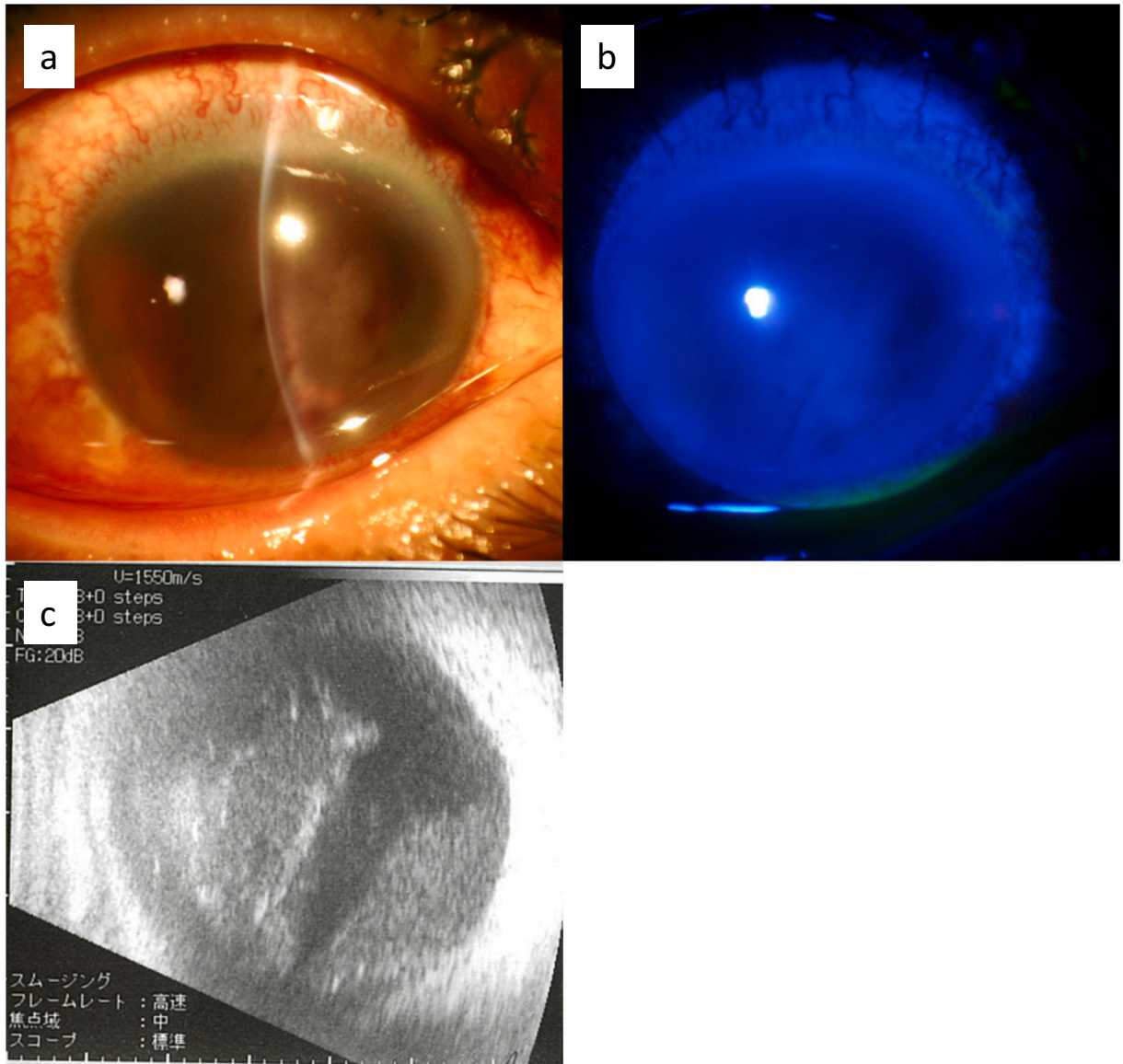


Fig. 2. Images of the right-eye anterior segment of the 62-year-old man who was injured by a fishhook.

- (a) Slit-lamp examination shows intraocular hemorrhage, thickened cornea with hyperemia, detached lens, and shallow anterior chamber at the initial presentation.
 (b) No corneal epithelial defect or aqueous humor leakage observed after corneal fluorescein staining.
 (c) Substantial vitreous hemorrhage is observed via echography.

sutured using three 7–0 sutures during the first visit, and topical treatment with 0.5% moxifloxacin and 0.1% betamethasone four times a day, tropicamide with phenylephrine twice a day, 1% atropine once a day, and 0.3% ofloxacin ointment was initiated. Furthermore, vitreous and cataract removal was performed the following day to treat the vitreous hemorrhage, macular hole, and retinal detachment detected via echography (Fig. 1c). Sulfur hexafluoride (SF₆) was injected intravitreally, and the treatment was revised postoperatively to 0.5% moxifloxacin and 0.1% betamethasone four times a day and 0.1% bromfenac twice a day. Two weeks later, the detached retina was completely reattached; the BCVA was 20/700. One month postoperatively, traumatic mydriasis persisted; however, the BCVA had recovered to 20/200 without any inflammation. Topical medication was discontinued 2 months postoperatively, and the intraocular lens was sutured 5 months after the injury. BCVA recovered to 20/100 eight months postoperatively and showed no further improvement owing to recurring post-traumatic iritis.

Case 2

A 62-year-old fisherman was referred to our hospital with a chief complaint of persistent pain in the right eye. The patient stated that a fishhook had penetrated his right eye 3 days back while on a ship; he reported “light sensation” following the injury. Accordingly, the doctors at the primary care hospital initiated treatment comprising topical levofloxacin and betamethasone four times a day, 0.5% timolol twice a day, and 500 mg/day oral acetazolamide and referred the patient to our hospital.

Hyperemia was observed in the right eye at the initial presentation. The anterior chamber was shallow, and the sclera and iris were ruptured with severe hemorrhage (Fig. 2a). The lens was damaged and detached inside the anterior chamber. Fluorescein staining showed no aqueous humor leakage (Fig. 2b). The patient's BCVA was “hand motion,” and the right-eye IOP was 38 mmHg. Echography showed severe vitreous hemorrhage without retinal detachment (Fig. 2c).

The ruptured sclera, in which the iris was stuck, was sutured using three 8–0 nylon sutures during the initial visit. The postoperative recovery was uneventful, and the pain resolved. The anterior chamber became deep, and the corneal edema improved; however, the BCVA was “light sensation” with an IOP of 2 mmHg.

Five days later, the detached lens moved to the anterior side, and the IOP increased to 30 mmHg. The corneal edema exacerbated, making it difficult to observe the fundus through the cornea. This was accompanied by increased intraocular hemorrhage. Since conservative treatment with 500 mg/day oral acetazolamide did not improve the high IOP and edematous cornea, vitreous surgery with lensectomy was performed 1 week after the initial visit. SF₆ was injected intravitreally. The postoperative intraocular inflammation had improved, and the IOP reduced to <20 mmHg, which was controlled with topical administration of 0.004% travoprost and 2% carteolol. Postoperative BCVA improved to 20/100 after 2 weeks, with further improvement (20/40) 16 months after the intraocular lens was sutured following the initial injury. However, glaucoma treatment had to be continued.

Discussion

This study retrospectively examined two severe cases of ocular fishhook injury with complications. Most fishhook injuries are limited to the anterior segment of the eyes, while severe ophthalmological cases are rare [5]. We presented two such rare cases with posterior segment complications. Vitreous hemorrhage, detached lens, and retinal detachment were safely resolved in these cases; however, both patients required further treatment after the surgery for recurring iritis or glaucoma. The BCVA had recovered from “counting fingers” at 15 cm and “light sensation” to 20/100 and 20/40, respectively.

Some surgical techniques for fishhook-related injuries involving the cornea and corneal limbs have been reported, including the “advance and cut,” “back-out,” “snatch,” and “needle-cover” methods [6–9]. It is important to prevent damage to the peripheral tissues during surgery. Furthermore, as the sharp barb is designed not to release the fish once it is hooked, it is expected to increase human ocular tissue damage. Since our patients were fishermen injured on ships during pelagic fishery far from the shore, their visit to our hospital was delayed. During this time, the penetrating fishhooks had already been removed. Further, the fishhooks must have been large as there were used for fish weighing more than 150 kg. If the infected fishhook had remained inside the eye, it would have required a much more complicated surgery to preserve the peripheral ocular tissue.

Fishhook-related injuries can also cause ocular infections [10]; however, no ocular infection was observed in our patients. Since fishing is an outdoor activity, the wound could be infected through the perforation site. The irregularly shaped fishhooks and wild bait might cause infection, because they could be contaminated by bacteria. Furthermore, foreign bodies could lead to ocular infection and/or delayed wound closure. We did not detect foreign bodies in our patients' eyes during the surgery. However, some fishhook metal debris might have been retained. In addition to careful long-term postoperative observation, prompt and prophylactic antibiotic treatment is advisable to prevent ocular infection following the initial presentation, even if no infection is evident.

In conclusion, this research suggested that fishhook-related ocular injury might lead to severe irreversible visual impairment. It is advisable for fishermen to wear protective glasses while fishing to prevent such injuries. Furthermore, though our patients were older, children should also be well-protected, based on the results of a previous report [10].

Acknowledgments

None.

References

- [1] S.W. Marshall, K. Kucera, D. Loomis, M.A. McDonald, H.J. Lipscomb, Work related injuries in small scale commercial fishing, *Inj Prev.* 10 (2004) 217–221.
- [2] K. Purtskhvanidze, M. Saeger, F. Treumer, B. Nölle, J. Roeder, Open globe and penetrating eyelid injuries from fish hooks, *BMC Ophthalmol.* 19 (2019) 26.
- [3] N. Yüksel, O. Elibol, Y. Çağlar, Penetrating corneal fish-hook injury, *Ophthalmologica* 208 (1994) 112–113.
- [4] L.P. Aiello, M. Iwamoto, D.R. Guyer, Penetrating ocular fish-hook injuries. Surgical management and long-term visual outcome, *Ophthalmology* 99 (1992) 862–866.
- [5] J. Choovuthayakorn, P. Chavengsaksongkram, N. Watanachai, W. Chaidaroon, Penetrating eyelid and ocular fishhook-related injury, *Case Rep. Ophthalmol.* 10 (2019) 41–46.
- [6] M.G. Grand, L.A. Lobes Jr., Technique for removing a fishhook from the posterior segment of the eye, *Arch. Ophthalmol.* 98 (1980) 152–153.
- [7] S.A. Bhalerao, P. Reddy, P.Y. Gogri, N.R. Banad, S. Vuyyuru, R. Mallipudi, Penetrating injury of the cornea by a barbed fish hook and its surgical management by “cut-it out technique”, *Indian J. Ophthalmol.* 69 (2021) 153–155.
- [8] M.R. Starr, M.B. Choi, M.A. Mahr, P. Mettu, D.F. Patterson, String technique for anterior orbital fish hook removal, *Ophthal. Plast. Reconstr. Surg.* 34 (2018) e136–e137.
- [9] R. Agrawal, A. Laude, M. Taneja, Fish-hook injury of the eye, *Int. Ophthalmol.* 32 (2012) 269–271.
- [10] C.S. Ang, Ocular fishhook injuries, *Med. J. Malays.* 56 (2001) 252–254.