



AUTHORS' CONTRIBUTIONS

Heloisa Del Castanhel Ubaldo

 ORCID 0000-0001-5828-4948

Approval of the final version of the manuscript; Conception and planning of the study; Elaboration and writing of the manuscript; Critical review of the literature

Caio César Silva de Castro

 ORCID 0000-0001-9767-5765

Approval of the final version of the manuscript; Conception and planning of the study; Elaboration and writing of the manuscript; Effective participation in research orientation; Intellectual participation in propaedeutic and/or therapeutic conduct of the cases studied; Critical review of the manuscript

How to cite this article: Ubaldo HDC, Silva de Castro CC. Coexistence of segmental vitiligo, scleroderma en coup de sabre and cleft lip on the same hemiface: association with mosaicism?

An Bras Dermatol. 2019;94(2): 248-50.

Eosinophilic panniculitis associated with toxocariasis in a child*

Julia Kanaan Recuero¹Giovana Binda¹Ana Elisa Kiszewski¹DOI: <http://dx.doi.org/10.1590/abd1806-4841.20198172>

Dear Editor,

Eosinophilic panniculitis (EP) is an uncommon panniculitis and is considered as a reactive process associated with different clinical conditions.¹ Among such conditions we find atopic dermatitis, contact dermatitis, arthropod bites, erythema nodosum, injection granuloma, leukocytoclastic vasculitis, lymphomas (T and B), autoimmunity and infectious processes (*Gnathostoma*, *Streptococcus* and *Toxocara*).^{1,2} We describe herein the case of a 5-year-old girl with papules and nodules in the gluteal region (Figure 1), with an evolution of 3 months, accompanied by bilateral inguinal adenopathy, whose laboratory and anatomopathological investigation indicated eosinophilic panniculitis associated with toxocariasis. In the laboratory analysis, cell blood count (CBC) showed eosinophilia of 2,813 eosinophils (20.4% of total leukocytes), serum IgE at 928 UI/mL (normal 393 UI/mL), and IgG (ELISA) reagent for *Toxocara canis*. Proteinogram, hepatic, renal and thyroid function tests were normal. Anti-HIV, anti-HCV, VDRL and anti-nuclear factor were non-reactive. Parasitological stool examination, direct mycological test and culture (for fungi and mycobacteria) were negative. Qualitative urine test was normal. Imaging tests (abdominal ultrasound and

chest X-ray) did not show any abnormality. Skin biopsy revealed a dense inflammatory infiltrate, predominantly eosinophilic in the papillary and reticular dermis, as well as in the septa and lobules of the subcutaneous adipose tissue (Figure 2). The histopathological diagnosis was compatible with EP. After reagent serology (ELISA) for *Toxocara canis*, intense eosinophilia and compatible histopathology, the diagnosis of EP associated with occult toxocariasis was confirmed. The patient was treated with albendazole 10mg/kg/day for 10 days, with significant reduction of pruritus and cutaneous lesions after 30 days and complete resolution of the condition after 3 months. Control CBC after 60 days of treatment showed significant decrease in eosinophils. Follow-up continued for 6 months, with no evidence of relapse.

EP was first described in 1985 by Burket and Burket.² Patients usually present subcutaneous nodules that involve the trunk, extremities or scalp, but papules, pustules and even ulcers may also be observed. Histopathological studies are necessary for diagnostic confirmation.¹ The peak of EP incidence is between the third and sixth decades of life.³ EP is rare in childhood, and the series with the most cases contain no descriptions of pediatric patients.^{1,2} Association of eosinophilic panniculitis with toxocariasis was documented by Rook and Tajjorton in 1972, in a 72-year-old patient with peripheral eosinophilia, subcutaneous nodules, pruritus and bilateral inguinal adenopathy; the nodule biopsy revealed panniculitis with eosinophilic infiltrate. The fluorescence antibody test for *Toxocara* was positive, and after treatment, the patient presented complete resolution of eosinophilia and cutaneous lesions.³ Cases prior to such publication are inconsistent because they had neither a biopsy nor a confirmatory test for toxocariasis. There are two other confirmed cases of EP associated with toxocariasis in adults, both simulating rheumatic diseases.⁴

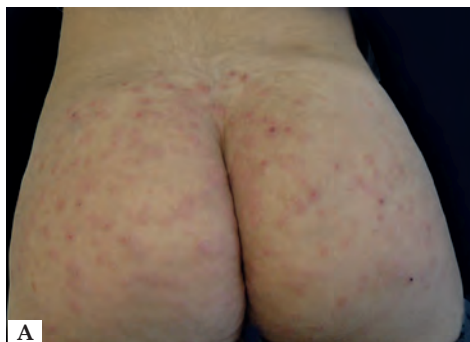

FIGURE 1:
A - Excoriated papules and nodules
B - Complete resolution of lesions three months after treatment

Received 07 February 2018.

Accepted 05 June 2018.

* Work conducted at the Dermatology Service, Universidade Federal de Ciências da Saúde de Porto Alegre, Porto Alegre (RS), Brazil.

Financial support: None.

Conflict of interest: None.

¹ Dermatology Service, Universidade Federal de Ciências da Saúde de Porto Alegre, Porto Alegre (RS), Brazil.

MAILING ADDRESS:

Ana Elisa Kiszewski

E-mail: kiszewski@gmail.com

©2019 by Anais Brasileiros de Dermatologia



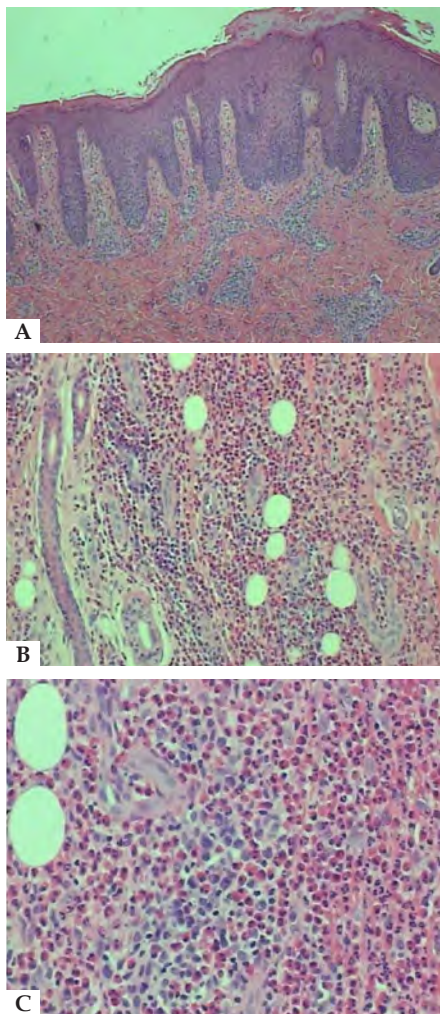


FIGURE 2:
A - Skin showing acanthosis, parakeratosis and inflammatory infiltrate in superficial and deep dermis (Hematoxylin & eosin, x40),
B - Hypodermis with dense inflammatory infiltrate, predominantly eosinophilic (Hematoxylin & eosin, x100) and
C - Eosinophils in septa of subcutaneous adipose tissue (Hematoxylin & eosin, x200)

Histopathological changes of EP consist of intense infiltration of eosinophils in lobules and septa, extending to the reticular dermis or fascia. Flame figures and small areas of subcutaneous necrosis can also be found. Vasculitis is not usually seen by routine light microscopy.²

Once the diagnosis of EP has been established, associated clinical conditions should be investigated. Cases with infectious factors are more frequently related to toxocariasis and gnathostomiasis.² Considering the high prevalence of infestation in the Brazilian population, toxocariasis should always be considered when patients present eosinophilia and/or related symptoms. Human toxocariasis can be classified as visceral larva migrans, ocular and neurological larva migrans, asymptomatic toxocariasis and occult toxocariasis.⁵ In the classic systemic subtype, patients usually present fever, anemia, leukocytosis, nausea, hepatomegaly and pulmonary symptoms in addition to abnormalities in proteinogram, eosinophilia and positive serology. The serological diagnosis is made by ELISA, which uses *Toxocara* excretion-secretion antigens and has high sensitivity and specificity, varying according to the antigens tested. In the case reported here, the absence of hepatomegaly, fever, proteinogram changes and pulmonary symptoms excluded the classical form of toxocariasis. Conversely, eosinophilia, pruritus, cutaneous lesions, and lymphadenitis, as well as the ELISA test reagent for *Toxocara canis*

and the excellent response to therapy confirmed the occult subtype of toxocariasis.⁵ The treatment for toxocariasis may include albendazole, ivermectin or thiabendazole. The first medication is preferable due to better distribution through tissues after metabolized.

In endemic countries for toxocariasis, such as Brazil, the clinical presentation of pruritic nodules associated with eosinophilia should suggest the possibility of EP associated with toxocariasis. □

REFERENCES

1. Adame J, Cohen PR. Eosinophilic panniculitis: Diagnostic considerations and evaluation. *J Am Acad Dermatol.* 1996;34:229-34.
2. Winkelmann RK, Frigas E. Eosinophilic panniculitis: a clinicopathologic study. *J Cutan Pathol.* 1986;13:1-12.
3. Rook A, Staughton R. The Cutaneous Manifestations of Toxocariasis. *Dermatologica.* 1972;144:129-43.
4. Kraus A, Valencia X, Cabral AR, de la Vega G. Visceral larva migrans mimicking rheumatic diseases. *J Rheumatol.* 1995;22:497-500.
5. Carvalho EA, Rocha RL. Toxocariasis: visceral larva migrans in children. *J Pediatr (Rio J).* 2011;87:100-10.

AUTHORS' CONTRIBUTIONS

Julia Kanaan Recuero	ORCID 0000-0003-4308-2184
Conception and planning of the study; Elaboration and writing of the manuscript; Critical review of the literature	
Giovana Binda	ORCID 0000-0002-9127-6736
Conception and planning of the study; Elaboration and writing of the manuscript; Critical review of the literature	
Ana Elisa Kiszewski	ORCID 0000-0002-6287-6302
Approval of the final version of the manuscript; Elaboration and writing of the manuscript; Critical review of the manuscript	

How to cite this article: Recuero JK, Binda G, Kiszewski AE. Eosinophilic panniculitis associated with toxocariasis in a child. *An Bras Dermatol.* 2019;94(2): 250-1.

Dercum's disease: a rare and underdiagnosed disease*

Juliana D'Andrea Molina¹
 Gisele Alborghetti Nai¹
 Tatiana Cristina Pedro Cordeiro de Andrade¹
 Marilda Aparecida Milanez Morgado de Abreu¹

DOI: <http://dx.doi.org/10.1590/abd1806-4841.20198231>

Received 26 February 2018.

Accepted 23 June 2018.

* Work conducted at the Hospital Regional de Presidente Prudente, Universidade do Oeste Paulista, Presidente Prudente (SP), Brazil.

Financial support: None.

Conflict of interest: None.

¹ Dermatology Service, Hospital Regional de Presidente Prudente, Universidade do Oeste Paulista, Presidente Prudente (SP), Brazil.

MAILING ADDRESS:

Juliana D'Andrea Molina

E-mail: julianadandrea@gmail.com

©2019 by Anais Brasileiros de Dermatologia

