

Metastatic testicular cancer presenting with liver and kidney dysfunction treated with modified BEP chemotherapy combined with continuous hemodiafiltration and rasburicase

Mai Kimakura, Toyofumi Abe, Akira Nagahara, Kazutoshi Fujita, Hiroshi Kiuchi, Motohide Uemura and Norio Nonomura

A 25-year-old man was admitted to our hospital complaining of right scrotal pain and upper abdominal pain. A computed tomographic scan indicated a right scrotal mass, a huge liver mass, and multiple lung masses, although there was no enlarged retroperitoneal lymph node swelling. Laboratory tests showed severe liver and kidney dysfunction and high levels of serum α -fetoprotein (11 997 ng/ml). Although needle biopsies of the testicular and liver masses were performed, the tissues were insufficient for a pathological diagnosis. As liver and kidney function worsened, we started chemotherapy with bleomycin, etoposide, and cisplatin (BEP chemotherapy), which was modified because of the liver and renal dysfunction. We also used continuous hemodiafiltration and rasburicase to prevent tumor lysis syndrome. After induction of chemotherapy, the liver and kidney dysfunction improved immediately and the high orchiectomy was performed on day 8 after chemotherapy. The pathological diagnosis was a yolk sac tumor. He underwent four courses

of the BEP regimen and five courses of the TIN regimen (paclitaxel, ifosfamide, and nedaplatin), followed by the resection of liver metastases. There was no evidence of viable cells in the resected liver and no recurrence was evident at 1 year postoperatively. *Anti-Cancer Drugs* 27:364–368 Copyright © 2016 Wolters Kluwer Health, Inc. All rights reserved.

Anti-Cancer Drugs 2016, 27:364–368

Keywords: continuous hemodiafiltration, liver metastasis, rasburicase, testicular cancer

Department of Urology, Osaka University Graduate School of Medicine, Osaka, Japan

Correspondence to Motohide Uemura, MD, PhD, Department of Urology, Osaka University Graduate School of Medicine, 2-2 E4 Yamada-oka, Suita, Osaka 565-0871, Japan

Tel: +81 6 6879 3531; fax: +81 6 6879 3539;
e-mail: uemura@uro.med.osaka-u.ac.jp

Received 11 November 2015 Revised form accepted 15 December 2015

Introduction

One of the standard chemotherapies for advanced testicular cancer is BEP chemotherapy (bleomycin, etoposide, and cisplatin) [1]. In cases of liver and renal dysfunction, the doses of chemotherapeutic agents must be modified with respect to the degree of the organ dysfunction. However, most dose adjustments are empiric and the risk of undertreating the disease remains a concern.

Tumor lysis syndrome (TLS) is characterized by a group of metabolic derangements caused by the massive and abrupt release of cellular components into the blood after the rapid lysis of malignant cells [2]. TLS can be caused by solid tumors with high proliferative rates and rapid response to therapy or bulky disease (>10 cm) [3]. In some cases, TLS can lead to acute renal failure and even death. The best management for TLS is prevention [3].

Here, we report on a patient with advanced testicular cancer presenting with severe liver and kidney

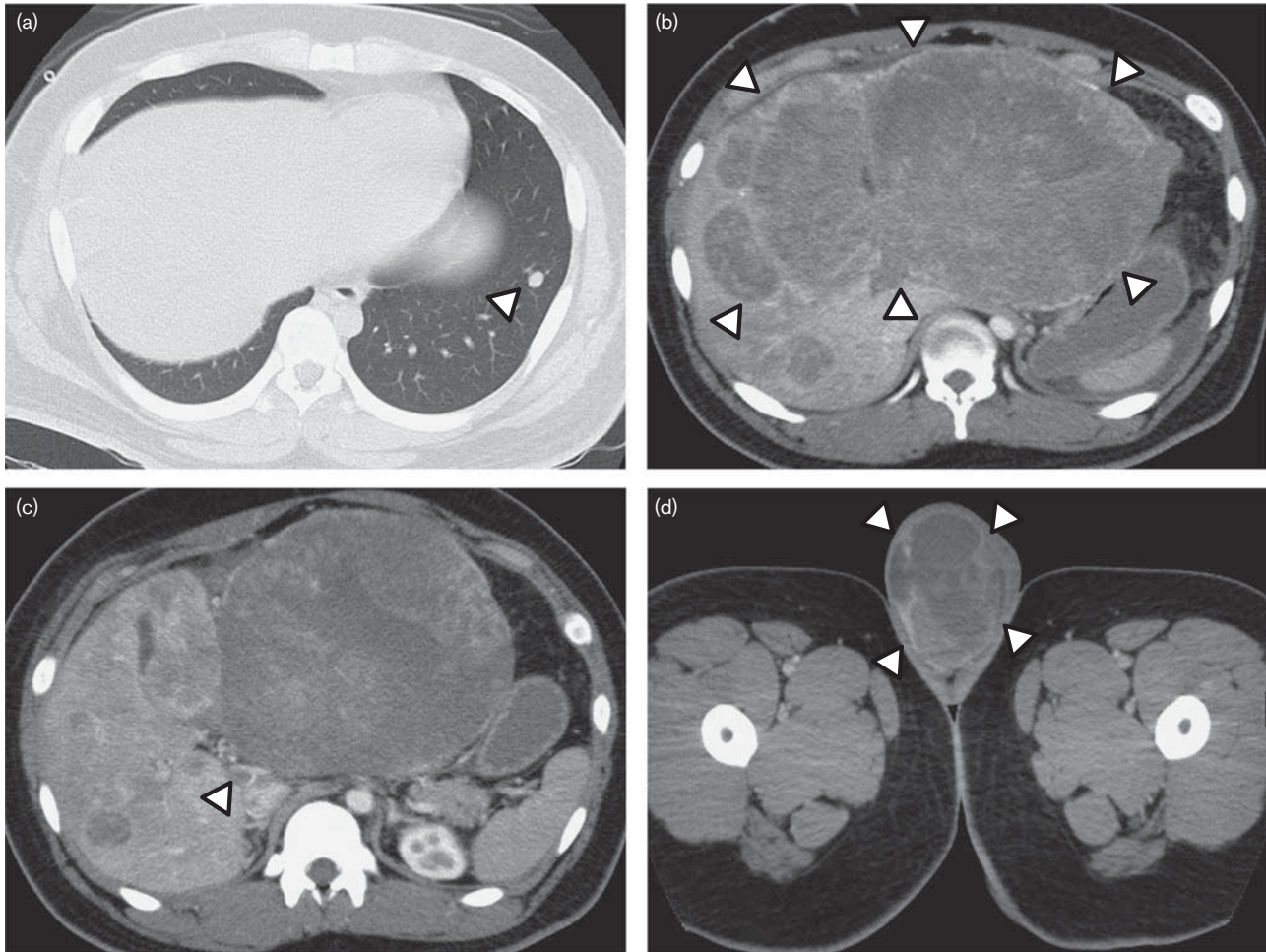
dysfunction who was treated successfully with modified chemotherapy combined with continuous hemodiafiltration (CHDF) and rasburicase.

Case report

A 25-year-old man noticed right scrotal pain in September 2013 and visited a nearby hospital in November 2013 because of worsening scrotal pain in addition to upper abdominal pain. A computed tomography (CT) scan indicated multiple lung masses up to 9 mm, multiple liver masses up to 260 mm with portal vein thrombosis, and an 84 mm right testicular mass (Fig. 1). As liver and kidney function and the patient's general condition worsened, he was referred to our hospital for further examinations and treatments. A blood examination showed severe liver and kidney dysfunction (aspartate aminotransferase 1168 IU/l, alanine aminotransferase 1072 IU/l, total bilirubin 2.7 ng/ml, creatinine 2.50 mg/dl, blood urea nitrogen 51 mg/dl, and uric acid 13.9 ng/ml), and marked elevation of serum testicular tumor markers [α -fetoprotein (AFP) 11 997 ng/ml and lactate dehydrogenase 4296 IU/l]. These results indicated advanced testicular cancer with multiple liver and lung metastases. However, advanced testicular cancer without retroperitoneal lymph node metastases is rare and

This is an open-access article distributed under the terms of the Creative Commons Attribution-Non Commercial-No Derivatives License 4.0 (CCBY-NC-ND), where it is permissible to download and share the work provided it is properly cited. The work cannot be changed in any way or used commercially.

Fig. 1



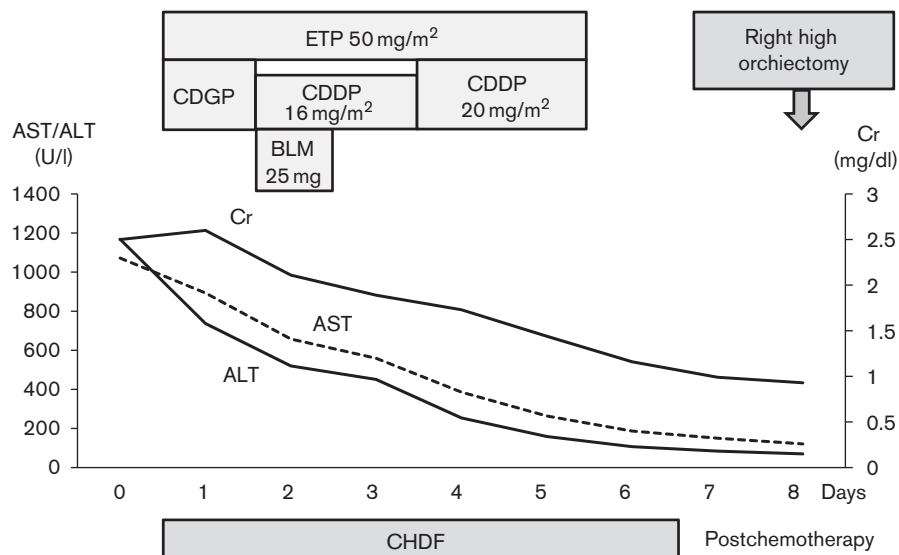
(a) Pulmonary CT showed multiple pulmonary metastases. Abdominal CT showed (b) multiple large liver metastases, (c) thrombosis in a portal vein, and (d) a right testicular tumor. CT, computed tomography.

the CT scan suggested a possibility of liver sarcoma. Although CT-guided needle biopsies of the testicular and hepatic masses were obtained, these tissues were insufficient for definitive pathological diagnosis. To deal with the patient's worsening condition, we started to treat the patient assuming that he had metastatic testicular cancer without a pathological diagnosis.

The chemotherapy regimen with BEP chemotherapy was modified as follows because of severe liver and kidney dysfunction: bleomycin (25 mg/body), etoposide (50 mg/m²), and nedaplatin (20 mg/m²) on day 1. In addition to the modified chemotherapy, CHDF, and rasburicase, a recombinant urate oxidase, were combined to prevent TLS. As liver and kidney function improved quickly after the administration of chemotherapy, nedaplatin was replaced by cisplatin (16 mg/m², 80% dose) on day 2. The cisplatin dose was increased from 16 to 20 mg/

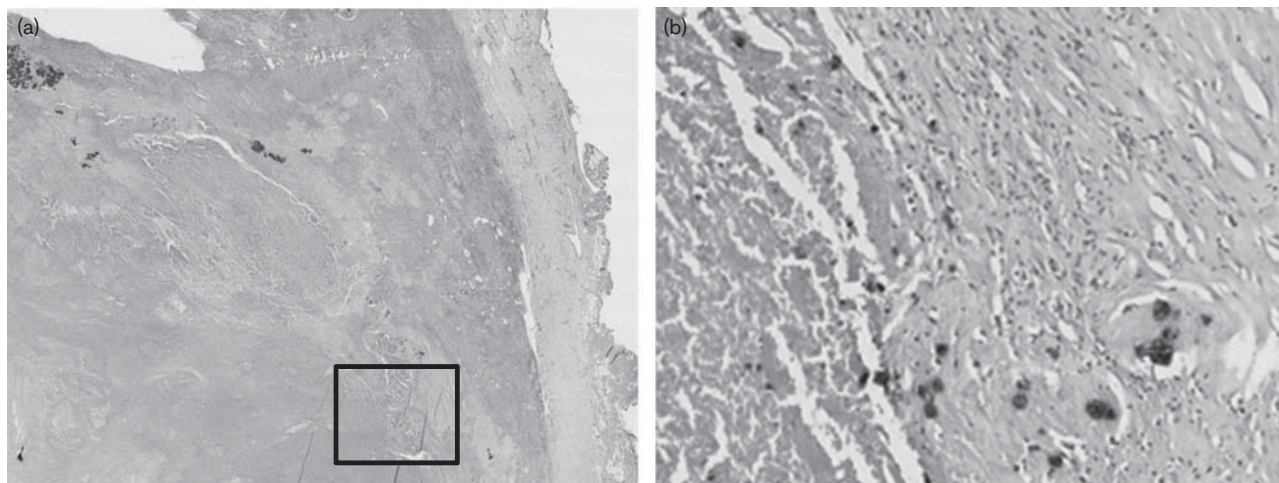
m² on days 4 and 5, and CHDF was discontinued on day 6 as the serum creatinine level recovered to the normal range (Fig. 2). Right high orchiectomy was performed on day 8 and the histopathological diagnosis was yolk sac tumor (Fig. 3). He was diagnosed with testicular non-seminoma with liver and lung metastases (pT2N0M1b, stage IIIC), which carries a poor prognosis on the basis of the International Germ Cell Cancer Collaborative group classification. After one course of the modified chemotherapy, the liver and kidney function recovered to a normal range. Three courses of full dose BEP chemotherapy were administered. As the serum AFP level was not normalized after four courses of chemotherapy, the TIN regimen (paclitaxel, ifosfamide, and nedaplatin) was administered as a salvage chemotherapy [4]. After five courses of TIN chemotherapy, the serum AFP level was normalized, and CT scan indicated a complete response of lung metastasis and a partial response of liver

Fig. 2



The clinical course after admission. ALT, alanine aminotransferase; AST, aspartate aminotransferase; BLM, bleomycin; CDDP, cisplatin; CDGP, nedaplatin; CHDF, continuous hemodiafiltration; Cr, creatinine; ETP, etoposide.

Fig. 3



Microscopic findings of the testicular tumor at (a) low power and (b) high power.

metastasis. Left hepatic lobectomy was performed and there was no histopathological evidence of viable cancer cells in the resected specimen. CT scan and blood test showed no signs of recurrence 1 year after left hepatic lobectomy

Discussion

BEP chemotherapy has been established as the standard of care for germ cell tumors, with marked improvements in patient survival [1]. In treating germ cell tumors with BEP

chemotherapy, the lower total dose and dose intensity of bleomycin and the lower dose intensity of etoposide may be responsible for poor outcomes [5]. However, in our case, because of multiple large liver metastases, the patient presented with severe liver dysfunction and, in addition, kidney dysfunction. Therefore, we needed to modify the chemotherapy regimen. As etoposide is metabolized into inactive forms in the liver [6], dose reduction by 50% in patients with bilirubin between 1.5 and 3 mg/dl is recommended [6,7]. On the basis of these

reports, we reduced etoposide by 50% for the first cycle of chemotherapy. As 60% of bleomycin is cleared by the kidney [6], the dose of bleomycin was reduced to 25 mg/body instead of 30 mg/body. As one of the major side effects of cisplatin is renal toxicity, the administration of cisplatin requires dose adjustments in patients with renal dysfunction and cisplatin is not recommended for patients with creatinine clearance below 60 ml/min [8]. Nedaplatin is a second-generation platinum derivative with reduced nephrotoxicity that exerts antitumor activity against various cancers, including testicular, gynecological, and lung carcinomas [4,9–11]. We substituted nedaplatin for cisplatin to reduce nephrotoxicity at the time of chemotherapy induction. As liver and kidney dysfunction was improved immediately after induction of the chemotherapy, a full dose of standard BEP chemotherapy was administered from the second cycle of the chemotherapy.

We speculate that there could be two reasons for kidney dysfunction in this patient. First, the patient's huge liver metastasis and portal vein thrombosis is similar to the situation of hepatorenal syndrome in patients with chronic previous liver disease. The occurrence of this syndrome is related to the mechanisms associated with ascites development, involving vasoconstriction, low renal perfusion, water and sodium retention, increased plasma volume, and consequent overflow at the splanchnic level [12]. Second, TLS may also occur before chemotherapy [3], and the patient actually presented with hyperuricemia, hyperpotassemia, and kidney dysfunction before chemotherapy, fulfilling diagnostic criteria for TLS [3]. TLS is an oncological emergency that may occur during chemotherapy for highly chemosensitive malignancies [13]. The release of intracellular substances accompanying extensive tumor cell death is considered to be the cause of this syndrome. The production and excretion of a high volume of uric acid causes the deposition of uric acid crystals in the collecting ducts, which results in the development of uric acid nephropathy [14]. In our case, the patient's uric acid level was very high (13.9 mg/dl) before starting chemotherapy. Thus, it is possible the patient's renal failure is because of TLS. The treatment of TLS involves adequate hydration and administration of allopurinol or rasburicase. Before 2002, antihyperuricemic drug therapy was limited to allopurinol. As allopurinol acts by decreasing the formation of uric acid, it is ineffective in reducing levels of uric acid developed before treatment [3]. Rasburicase, a recombinant urate oxidase, which converts uric acid into the more soluble allantoin, was approved for children in 2002 and adults in 2009 [15]. Rasburicase is now a standard of care for patients at high risk of TLS [15]. We administered rasburicase at the time of chemotherapy induction, and serum uric acid rapidly decreased to 0.1 mg/dl at 24 h after administration.

We also used CHDF to prevent the progression of renal failure and TLS. Compared with intermittent hemodiafiltration, the major advantage of CHDF is its reduced rate of fluid removal. CHDF is generally better tolerated than conventional intermittent therapy [16]. As the general condition of the patient worsened, CHDF was administered at the intensive care unit. To avoid drug clearance by dialysis causing a loss of efficacy, CHDF was stopped during an intravenous infusion of chemotherapy drugs.

Thus, the patient with advanced testicular cancer with life-threatening bulky liver metastases that led to liver and kidney dysfunction was managed successfully with modified chemotherapy combined with CHDF and rasburicase.

TLS is observed most frequently in patients with hematologic malignancies such as acute lymphoblastic leukemia after the initiation of cytotoxic therapy, although it may also occur spontaneously and/or in other tumor types with a high proliferative rate, large tumor burden, or high sensitivity to cytotoxic therapy [3]. TLS in patients with testicular cancer is rare, but can be life-threatening [14,17]. Testicular cancer is a chemotherapy-sensitive cancer that is a risk factor for the development of TLS. Attention must be paid to the potential risk of TLS in patients of advanced testicular cancer with bulky metastasis.

Acknowledgements

Conflicts of interest

There are no conflicts of interest.

References

- Williams SD, Birch R, Einhorn LH, Irwin L, Greco FA, Loehrer PJ. Treatment of disseminated germ-cell tumors with cisplatin, bleomycin, and either vinblastine or etoposide. *N Engl J Med* 1987; **316**:1435–1440.
- Seegmiller JE, Laster L, Howell RR. Biochemistry of uric acid and its relation to gout. *N Engl J Med* 1963; **268**:712–716.
- Coiffier B, Altman A, Pui CH, Younes A, Cairo MS. Guidelines for the management of pediatric and adult tumor lysis syndrome: an evidence-based review. *J Clin Oncol* 2008; **26**:2767–2778.
- Nonomura N, Oka D, Nishimura K, Nakayama M, Inoue H, Mizutani Y, *et al.* Paclitaxel, ifosfamide, and nedaplatin (TIN) salvage chemotherapy for patients with advanced germ cell tumors. *Int J Urol* 2007; **14**:527–531.
- Toner GC, Stockler MR, Boyer MJ, Jones M, Thomson DB, Harvey VJ, *et al.* Comparison of two standard chemotherapy regimens for good-prognosis germ-cell tumours: a randomised trial. Australian and New Zealand Germ Cell Trial Group. *Lancet* 2001; **357**:739–745.
- Superfin D, Iannucci AA, Davies AM. Commentary: oncologic drugs in patients with organ dysfunction: a summary. *Oncologist* 2007; **12**:1070–1083.
- Floyd J, Mirza I, Sachs B, Perry MC. Hepatotoxicity of chemotherapy. *Semin Oncol* 2006; **33**:50–67.
- Lichtman SM, Wildiers H, Launay-Vacher V, Steer C, Chatelut E, Aapro M. International Society of Geriatric Oncology (SIOG) recommendations for the adjustment of dosing in elderly cancer patients with renal insufficiency. *Eur J Cancer* 2007; **43**:14–34.
- Fukuda M, Shinkai T, Eguchi K, Sasaki Y, Tamura T, Ohe Y, *et al.* Phase II study of (glycolate-O₂) diammineplatinum(II), a novel platinum complex, in the treatment of non-small-cell lung cancer. *Cancer Chemother Pharmacol* 1990; **26**:393–396.
- Akaza H, Togashi M, Nishio Y, Miki T, Kotake T, Matsumura Y, *et al.* Phase II study of cis-diammine(glycolato)platinum, 254-S, in patients with advanced

- germ-cell testicular cancer, prostatic cancer, and transitional-cell carcinoma of the urinary tract. 254-S Urological Cancer Study Group. *Cancer Chemother Pharmacol* 1992; **31**:187–192.
- 11 Desoize B, Madoulet C. Particular aspects of platinum compounds used at present in cancer treatment. *Crit Rev Oncol Hematol* 2002; **42**:317–325.
- 12 Genzini T, Torricelli FC. Hepatorenal syndrome: an update. *Sao Paulo Med J* 2007; **125**:50–56.
- 13 Baeksgaard L, Sørensen JB. Acute tumor lysis syndrome in solid tumors – a case report and review of the literature. *Cancer Chemother Pharmacol* 2003; **51**:187–192.
- 14 Kawai K, Takaoka E, Naoi M, Mori K, Minami M, Shimazui T, Akaza H. A case of metastatic testicular cancer complicated by tumour lysis syndrome and choriocarcinoma syndrome. *Jpn J Clin Oncol* 2006; **36**:665–667.
- 15 Dinnel J, Moore BL, Skiver BM, Bose P. Rasburicase in the management of tumor lysis: an evidence-based review of its place in therapy. *Core Evid* 2015; **10**:23–38.
- 16 Manns M, Sigler MH, Teehan BP. Continuous renal replacement therapies: an update. *Am J Kidney Dis* 1998; **32**:185–207.
- 17 Kobatake K, Kato M, Mita K. Advanced testicular cancer associated with life-threatening tumour lysis syndrome and choriocarcinoma syndrome. *Can Urol Assoc J* 2015; **9**:62–64.