

Combined limited internal fixation and multiplanar external fixation for immediate weight bearing of fractures around the foot and ankle

Milan K. Sen, MD, FRSCS, FAAOS^{a,b,*}

Abstract

Treatment of fractures around the foot and ankle can be challenging in patients who are unable to remain non weight bearing on their lower extremity. Traditional implants are not sufficient to resist loads incurred during weight bearing and can also lead to complications related to wound healing and infection. We describe a technique for fracture fixation of the foot and ankle that uses low profile implants to minimize soft tissue insult combined with multiplanar external fixation to allow for immediate weight bearing.

Keywords: ankle, external fixation, foot, fracture, internal fixation, trauma, weight bearing

1. Introduction

Internal fixation of injuries around the foot and ankle can be fraught with complications related to wound healing and infection^[1] due to the relative paucity of soft tissue in this area. This applies not only to high energy fractures, but also to low energy injuries because of the disproportionate impact of comorbidities such as diabetes and peripheral vascular disease on perfusion of the lower extremity,^[2] and changes associated with aging.^[3]

In addition, many injuries in the foot and ankle are not amenable to internal fixation strategies that allow for immediate weight bearing. This becomes a problem when treating patients who have bilateral injuries. It is also an issue in patients who have unilateral injuries but are unable to be non-weight bearing on their lower limb due to^[1] weakness or frailty,^[4] or^[2] noncompliance. In the former, it is often critical that they are allowed to begin early weight bearing to prevent complications related to immobility, which have been well described in relation to hip fractures.^[5–7] In lower

extremity fractures around the hip and knee, emphasis has been placed on employing fixation strategies that allow for immediate weight bearing—but these same principles have been difficult to apply to the foot and ankle. For noncompliance due to psychiatric or behavioral issues, the patient is often not considered to be a surgical candidate because of the higher risk of complications.^[8] However, nonsurgical treatment also requires adherent behavior to be successful. Employing this strategy in a noncompliant patient will avoid surgical complications, but deformity and either malunion or nonunion are likely and can result in soft tissue compromise that jeopardizes limb survival.

To address the limitations of internal fixation in the foot and ankle and to allow for immediate weight bearing in the aforementioned patient populations, we have developed a strategy involving static multiplanar external fixation. The fractures are initially treated with limited open reduction and internal fixation using low profile implants to restore alignment and articular congruity with less soft tissue disturbance. A multiplanar external fixator is then used as an adjunct to protect the fixation and allow for early weight bearing by neutralizing the axial load that would otherwise result in fracture displacement and hardware failure. It also has the advantage of providing stability necessary for soft tissue healing. In this article we describe our indications and technique with some case examples.

2. Technique

Depending on the energy of the injury and the severity of the insult to the soft tissues, patients are either immobilized in a well-padded splint or placed in an external fixator—standard delta frame or a “hybrid” type construct as shown in Figure 1A. In unstable periarticular injuries, especially those with acute shortening, or in situations requiring more stability to aid soft tissue recovery, external fixation is preferred. Once the soft tissue swelling has subsided, open reduction and internal fixation of the articular injury is performed.

The preoperative plan must take into consideration not only the bony injury, but also the associated injuries, condition of the soft tissues, medical comorbidities, and behavioral conditions that may impact compliance. Our most common indications for use of limited internal fixation combined with multiplanar external fixation are listed in Table 1.

Source of funding: Nil.

Collection: Early Weightbearing Constructs in the Lower Extremity.

The author has no conflicts of interest to disclose.

The study was deemed exempt from Institutional Review Board and Animal Use Committee Review.

^a Chief of Orthopedic Surgery, Director of Orthopedic Surgery, NYC Health +Hospitals/Jacobi, ^b Associate Professor, The Albert Einstein College of Medicine, The Bronx, NY.

* Corresponding author. Address: 1400 Pelham Parkway South, Bronx, NY 10461. Tel: +718 918 4921; fax: +718 918 4914; e-mail: address: msenmd@gmail.com (M.K. Sen).

Copyright © 2022 The Authors. Published by Wolters Kluwer Health, Inc. on behalf of the Orthopaedic Trauma Association.

This is an open access article distributed under the terms of the Creative Commons Attribution-Non Commercial-No Derivatives License 4.0 (CCBY-NC-ND), where it is permissible to download and share the work provided it is properly cited. The work cannot be changed in any way or used commercially without permission from the journal.

OTA (2022) e194

Received: 22 December 2021 / Received in final form: 4 January 2022 /

Accepted: 4 January 2022

Published online 20 July 2022

<http://dx.doi.org/10.1097/OI9.000000000000194>

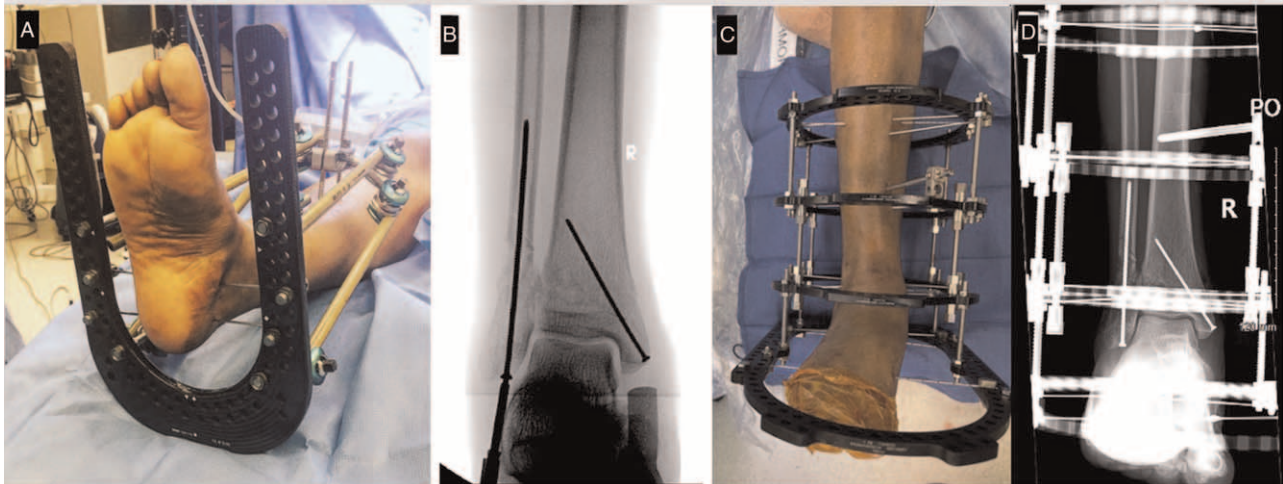


Figure 1. Technique. (A) “Hybrid” uniplanar external fixator. (B) Limited internal fixation with low profile implants. (C) Clinical photo of limb alignment in the multiplanar external fixator. (D) AP x-ray of final fixation construct.

Specific examples of the strategies employed for different fracture types are illustrated in the case examples, but the following general principles apply regardless of the location in the distal tibia, ankle, or foot. The first step is limited internal fixation of the articular injury. Surgical approaches that allow for reduction and fragment specific fixation while minimizing soft tissue dissection are used. Fixation needs to be sufficient to maintain reduction, but will not need to withstand loading, and typically lower profile implants (1/3 tubular or 2.7 and 2.4 mm plates, and screws) are used in favor of the larger anatomic periarticular plates (Fig. 1B).

Once the limited internal fixation is complete, the wounds should be closed and any additional soft tissue management completed. The patient is then positioned supine with a bump under the ipsilateral buttock and the leg supported by blankets or foam to facilitate lateral fluoroscopic imaging. A frame can be preassembled based on measurements taken from the CT (computed tomography) scan and sterilized before the case to save time. Our standard construct for distal tibia and ankle fractures is 2 full proximal rings, 1 full distal ring, and the foot plate. For hindfoot and midfoot injuries the distal tibial ring can be left out. Since length, alignment, and rotation are obtained before frame placement, this is a static frame and hexapod struts are not necessary. Instead, 4 threaded rods can be used to assemble the frame, which provide excellent stability and are also more cost effective. The frame is then placed over the leg. Folded towels placed under the calf, distal tibia, and heel are used to support and center the leg within the frame. Care must be taken to ensure the proximal rings will not touch the calf once the towels are removed.

Table 1
Common indications for limited internal fixation and multiplanar external fixation.

- Bilateral lower extremity articular fractures
- Open fractures of the distal tibia, ankle, or foot
- Inability to ambulate while being non weight bearing on the affected limb due to frailty
- Medical conditions that impact soft tissue healing (diabetes, peripheral vascular disease)
- Substance abuse
- Psychiatric illness

If necessary, additional reduction maneuvers to restore length, alignment, and rotation can be obtained with in-line traction and manipulation under fluoroscopy. Provisional fixation with k-wires can be used if necessary. One must again verify that the ring is not impinging on any soft tissues, and that the tibial crest lines up with the markings for the front of the rings and the foot rests within the “U” shape of the foot plate (Fig. 1C).

Fixation of the ring to the limb begins with fine wire placement. We begin by lining up the distal ring with the distal tibia, parallel to the articular surface on AP (anteroposterior) and lateral fluoroscopy views. The first wire is then inserted in the distal tibia from medial to lateral, parallel to the joint, and capturing the fibula. Frame position is verified, and the wire secured with 110kg of tension. A second and third wire can then be inserted from medial to lateral and secured to the first and second proximal rings, respectively. If satisfied with frame positioning, the surgeon may proceed to fixation of the calcaneus and then the midfoot with medial to lateral wires at 90kg of tension. It is important to attach the anterior half ring to the foot plate before tensioning the midfoot wire.

The leg is now provisionally fixed to the frame. The surgeon must verify satisfaction with the alignment, and with the position of the limb relative to the frame. If at any point adjustments are needed, it is easy to remove a wire, readjust, and insert a new wire. The final step is completing fixation. A posteromedial to anterolateral wire is placed in the foot plate and all the rings. A third wire is added to the proximal tibia rings, medial to lateral but off axis from the first wire. Alternatively, a hydroxyapatite coated 4.5 mm Schanz screw may be used in place of a third wire on 1 or both of the proximal rings. Our preference is to use it only for the second ring and avoid a stress riser at the proximal ring (Fig. 1C and D). A rubber walking “ring” is attached to the foot plate and the patient is allowed to be full weight bearing postoperatively.

3. Case 1: pilon fracture

A 19 year old female involved in a motor vehicle collision presented with an open intra-articular distal tibia fracture. Initial AP x-ray and clinical photograph is seen in Figure 2A and B, respectively. Selective CT cuts demonstrate the articular injury (Fig. 2C and D). Patient was initially placed in a uniplanar external fixator with a foot plate. Once soft tissues

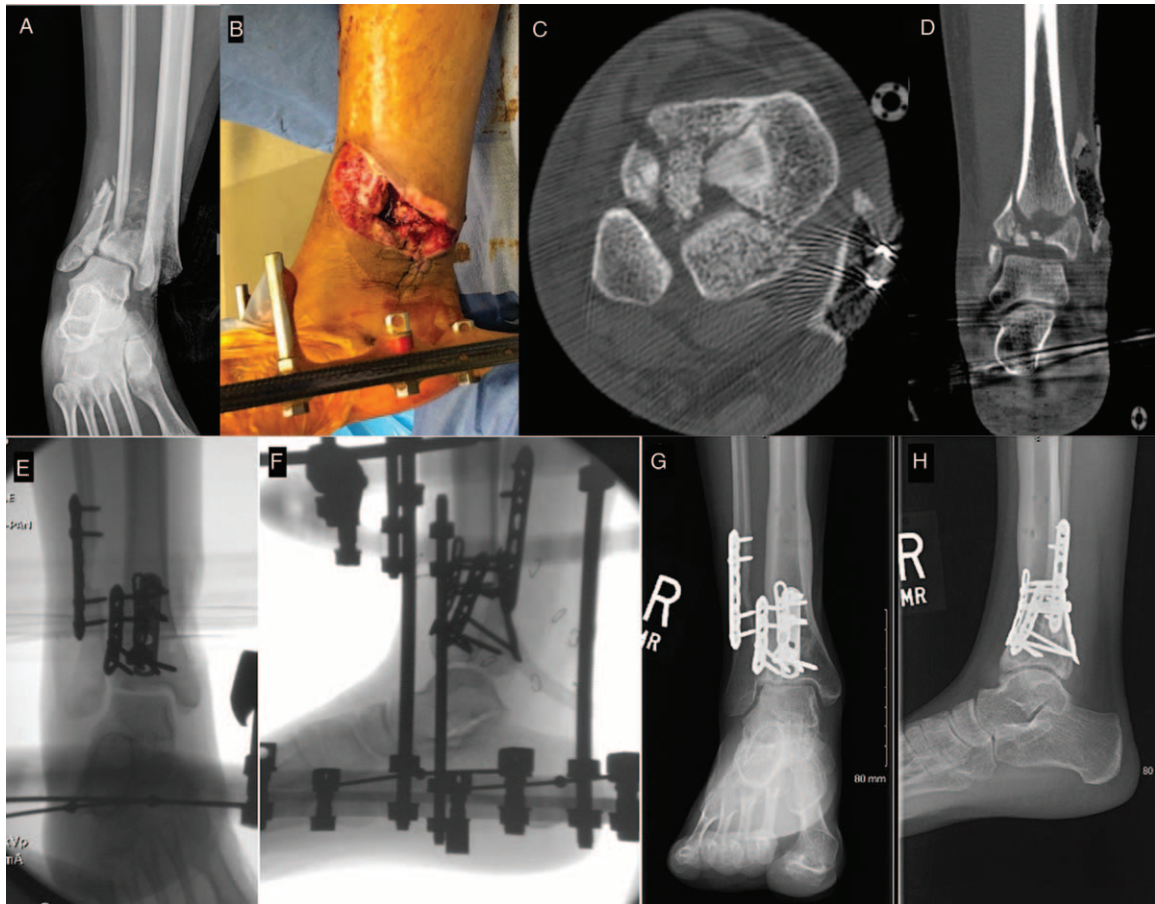


Figure 2. Case 1, pilon fracture. (A) AP x-ray of injury. (B) Clinical photo of soft tissue injury. (C) Axial CT image. (D) Coronal CT image. (E) AP fluoroscopic image of final fixation construct. (F) Lateral fluoroscopic image of final fixation construct. (G) AP x-ray at 26 months postoperatively. (H) Lateral x-ray at 26 months postoperatively.

improved, she underwent open reduction and internal fixation with low profile implants using posterolateral and anterolateral approaches, followed by multiplanar external fixation (Fig. 2E and F). Her wounds healed without any complications. External fixation was removed at 12 weeks postoperatively. At 26 months postoperatively she is ambulating without pain

despite some radiographic evidence of osteoarthritis (Fig. 2G and H).

4. Case 2: midfoot injury

A 22 year old male with antisocial personality disorder presented with a right Lisfranc fracture dislocation (Fig. 3A) and a left

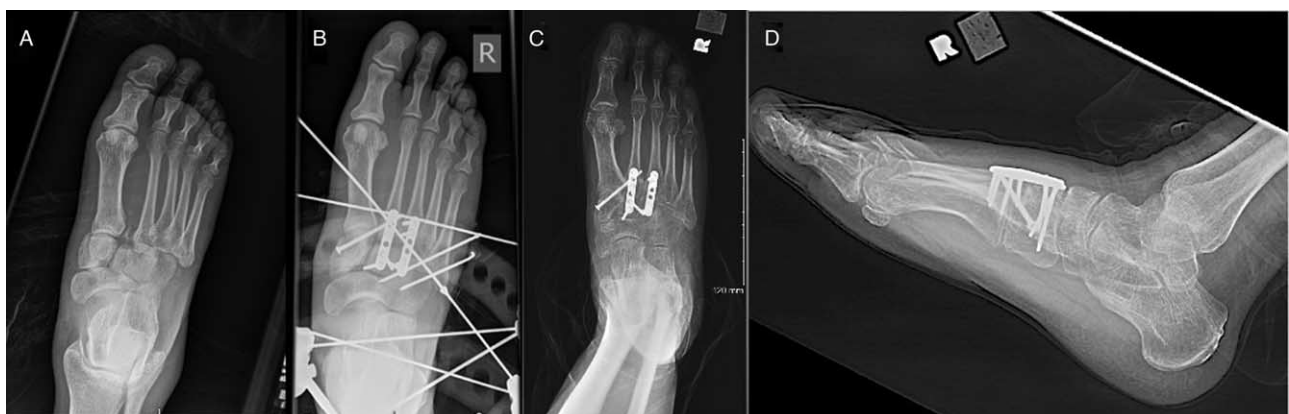

Figure 3. Case 2, midfoot injury. (A) AP x-ray of injury. (B) Postoperative AP x-ray. (C) AP x-ray at 1 year postoperatively. (D) Lateral x-ray at 1 year postoperatively.

distal tibial pilon fracture after jumping down a staircase at a subway station. The left pilon fracture was treated in similar fashion to Case 1. When soft tissues improved the right foot Lisfranc injury was treated with open reduction and internal fixation. Due to the patients nonadherent and defiant behavior a multiplanar external fixator was applied to protect the internal fixation during weight bearing (Fig. 3B). The external fixator was well tolerated and was removed at 12weeks. One year follow up x-rays are shown in Figure 3C and D.

5. Discussion

Historically, there has been a high complication rate associated with open reduction and internal fixation of fractures of the distal tibia, ankle, and foot in certain patient populations.^[1] This is especially true with high energy injuries, and in patients with poor blood supply to the extremities due to medical conditions such as diabetes and peripheral vascular disease. Traditional fixation techniques cause further insult to the soft tissue envelope, and wound complications and infection are common.

Patients who are unable to remain non weight bearing on the extremity due to frailty or compliance issues, and those with bilateral injuries, are also challenging to treat. Neither cast treatment nor traditional internal fixation constructs can always support early weight bearing, which leads to displacement, malunion or nonunion, deformity, pain, and potentially soft tissue breakdown and loss of the limb.

To address this, techniques of limited internal fixation combined with uniplanar external fixation have been described for injuries of the tibial pilon and calcaneus, which minimize soft tissue complications and lower the infection rate.^[9-11] Similar results have been described with uniplanar external fixation of open midfoot fractures and dislocations in adult trauma patients.^[12] Recently, authors have also shown good results with multiplanar fixation of pilon fractures and partial weight bearing in the elderly.^[13] Our experience is that the use of limited internal fixation with multiplanar external fixation provides the same benefits as these other techniques, and allows for immediate full weight bearing without compromising the fragment specific fixation that is achieved with soft tissue friendly low-profile implants. Pin site infections are managed with local wound care and oral antibiotics, and deep infections

and osteomyelitis are rare.^[9,10,12,14] This strategy can be used for injuries of the distal tibia, ankle, hindfoot, or midfoot, and we have also had good success in the elderly and in patients with behavioral or mental health conditions.

References

1. Bear J, Rollick N, Helfet D. Evolution in management of tibial pilon fractures. *Curr Rev Musculoskelet Med* 2018; 11:537-545.
2. Nativel M, Potier L, Alexandre L, et al. Lower extremity arterial disease in patients with diabetes: a contemporary narrative review. *Cardiovasc Diabetol* 2018; 17:138.
3. Inoue T, Maeda K, Nagano A, et al. Undernutrition, sarcopenia, and frailty in fragility hip fracture: advanced strategies for improving clinical outcomes. *Nutrients* 2020; 12:3743.
4. Kammerlander C, Pfeufer D, Lisitano LA, et al. Inability of older adult patients with hip fracture to maintain postoperative weight-bearing restrictions. *J Bone Joint Surg Am* 2018; 100:936-941.
5. Pfeufer D, Zeller A, Mehaffey S, et al. Weight-bearing restrictions reduce postoperative mobility in elderly hip fracture patients. *Arch Orthop Trauma Surg* 2019; 139:1253-1259.
6. Kamel HK, Iqbal MA, Mogallapu R, et al. Time to ambulation after hip fracture surgery: relation to hospitalization outcomes. *J Gerontol A Biol Sci Med Sci* 2003; 58:1042-1045.
7. Frenkel Rutenberg T, Vitenberg M, Haviv B, et al. Timing of physiotherapy following fragility hip fracture: delays cost lives. *Arch Orthop Trauma Surg* 2018; 138:1519-1524.
8. Paredes AZ, Hyer JM, Diaz A, et al. The impact of mental illness on postoperative outcomes among medicare beneficiaries: a missed opportunity to help surgical patients? *Ann Surg* 2020; 272:419-425.
9. Galante VN, Vicenti G, Corina G, et al. Hybrid external fixation in the treatment of tibial pilon fractures: a retrospective analysis of 162 fractures. *Injury* 2016; 47 (Suppl 4):S131-S137.
10. Vicenti G, Carozzo M, Solarino G, et al. Comparison of plate, calcanealplasty and external fixation in the management of calcaneal fractures. *Injury* 2019; 50 (Suppl 4):S39-S46.
11. Meena UK, Bansal MC, Behera P, et al. Evaluation of functional outcome of pilon fractures managed with limited internal fixation and external fixation: a prospective clinical study. *J Clin Orthop Trauma* 2017; 8:S16-S20.
12. Chandran P, Puttaswamaiah R, Dhillon MS, et al. Management of complex open fracture injuries of the midfoot with external fixation. *J Foot Ankle Surg* 2006; 45:308-315.
13. Nozaka K, Miyakoshi N, Saito H, et al. Effectiveness of Ilizarov external fixation in elderly patients with pilon fractures. *J Orthop Sci* 2021; 26:254-260.
14. Papadokostakis G, Kontakis G, Giannoudis P, et al. External fixation devices in the treatment of fractures of the tibial plafond: a systematic review of the literature. *J Bone Joint Surg Br* 2008; 90:1-6.