

# Diagnostic Arthroscopy of the Minipig Stifle (Knee) for Translational Large Animal Research



Dean Wang, M.D., Mark Cubberly, M.D., Wendy E. Brown, Ph.D., Heenam Kwon, Ph.D., Jerry C. Hu, Ph.D., and Kyriacos A. Athanasiou, Ph.D.

**Abstract:** To gain regulatory approval for the clinical use of knee biologics and devices in humans, translational large-animal studies are typically required. Animal models that permit second-look arthroscopy are valuable because they allow for longitudinal assessment of the treated tissue without needing to sacrifice the animal. The minipig is an ideal preclinical animal model for the investigation of therapies for the knee, in part because arthroscopy can be performed in its stifle (knee) joint with the use of standard surgical equipment used in humans. The purpose of this Technical Note is to describe a reproducible technique for diagnostic arthroscopy of the minipig stifle (knee) joint.

Translational animal models are critical tools for investigating new therapies in preclinical studies before progression to human clinical trials. For treatments in the knee, the minipig stifle (knee) is an ideal animal model because of its docile nature, sufficient cartilage thickness,<sup>1</sup> joint loading biomechanics that better simulate the adult human condition compared to other large animals,<sup>2,3</sup> and feasibility of arthroscopy.<sup>4</sup> Yucatan and Göttingen minipigs have been used for the study of anterior cruciate ligament (ACL) and articular cartilage repair strategies.<sup>5,6</sup> Second-look knee arthroscopy is a valuable tool that allows for clear intra-articular visualization of the treated tissue without needing to sacrifice the animal, permitting longitudinal assessment of treatment strategies after surgery. The purpose of this Technical Note is to describe a reproducible technique for diagnostic arthroscopy of the minipig stifle (knee) joint.

## Surgical Technique

### Animal Positioning and Arthroscopy Set-Up

After induction of anesthesia, the minipig is placed supine on the operating room table. A padded bump is placed lateral to the operative leg to limit external rotation of the hip, allowing for more controlled range of motion of the knee. Alternatively, a lateral post may be used to assist with producing a valgus force to open the medial compartment. Standard arthroscopy instruments, including a 2.4-mm arthroscope with a 30° visual angle, 4-mm hook probe, and 2.0-mm arthroscopic shaver (Arthrex Sabre, SJ 2.0 mm × 7 cm), are used (Fig 1). Epinephrine is added to the saline solution bags at a standard dose of 0.33 mg/L. An arthroscopy pump system is used to maintain an intra-articular pressure of 40 mm Hg.

### Diagnostic Technique

The joint line is palpated, and with the knee positioned at approximately 90° to 100° of flexion, the anterolateral and anteromedial portals are outlined with a surgical marker. Compared to the human knee, the patella of the minipig knee is typically positioned more proximally (equivalent to patella alta), and therefore the anterior portals should be made distal to the level of the inferior pole of the patella in order to gain access to the infrapatellar compartment (Fig 2). It is also important to note that minipig knees have a physiological passive range of motion from 42° to 144° of flexion.<sup>7</sup> Pertinent anatomic differences between the minipig and human knee for arthroscopy should be recognized to successfully navigate the joint (Table 1

From the Department of Orthopaedic Surgery (D.W., M.C.) and the Department of Biomedical Engineering (W.E.B., H.K., J.C.H., K.A.A.), University of California Irvine, Irvine, California, U.S.A.

The authors report that they have no conflicts of interest in the authorship and publication of this article. Full ICMJE author disclosure forms are available for this article online, as [supplementary material](#).

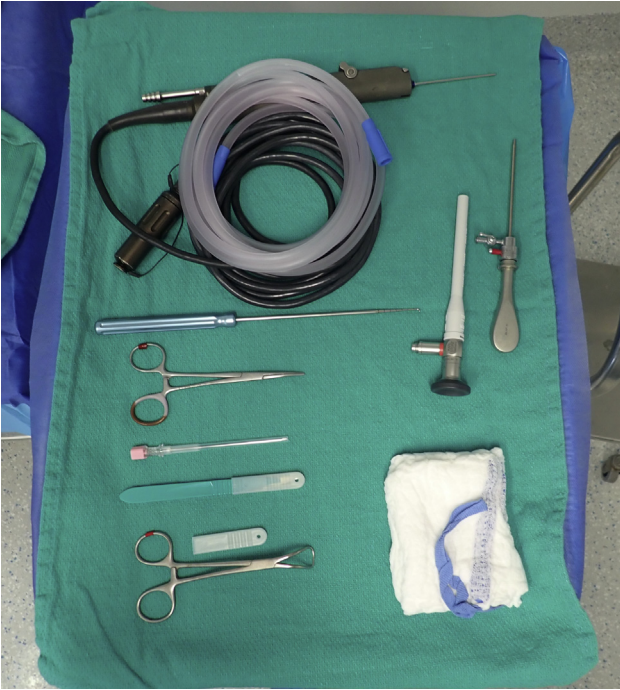Received August 2, 2020; accepted October 8, 2020.

Address correspondence to Dean Wang, M.D., Department of Orthopaedic Surgery, UCI Health, 101 The City Dr S, Pav III, Orange, CA 92868, U.S.A. E-mail: [deanwangmd@gmail.com](mailto:deanwangmd@gmail.com)

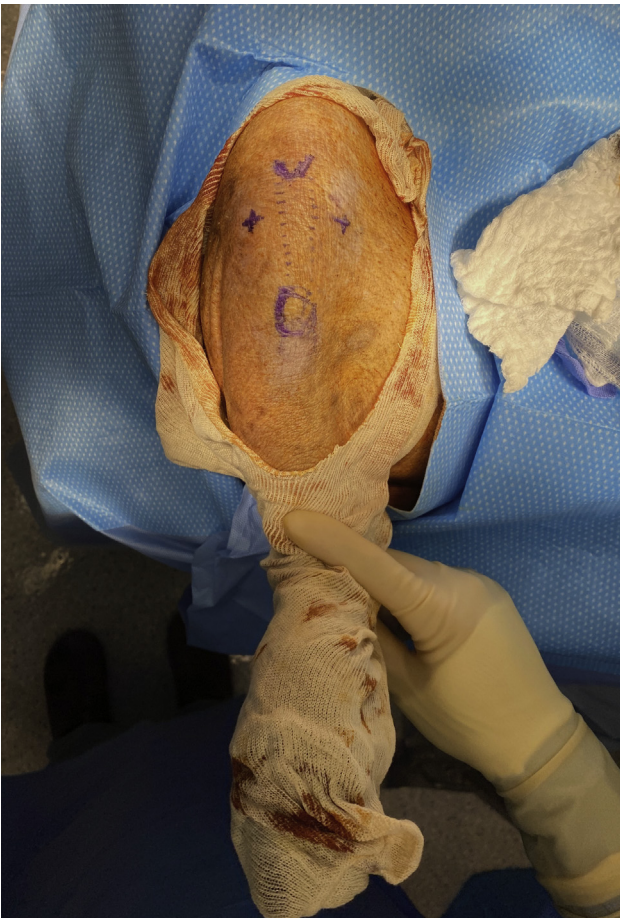© 2020 by the Arthroscopy Association of North America. Published by Elsevier. This is an open access article under the CC BY-NC-ND license (<http://creativecommons.org/licenses/by-nc-nd/4.0/>).

2212-6287/201341

<https://doi.org/10.1016/j.eats.2020.10.005>



**Fig 1.** Arthroscopy setup and instrumentation for diagnostic arthroscopy of the minipig stifle (knee).



**Fig 2.** Right minipig knee with marked anterolateral and anteromedial portals (indicated by +) for arthroscopy. The inferior pole of the patella and tibial tubercle are also marked.

**Table 1.** Pertinent differences between minipig and human anatomy for knee arthroscopy

Difference in minipig knee compared to human knee

Smaller size

More proximal positioning of the patella (patella alta)

Physiologic passive range of motion from 42-144° of flexion

EDL is intra-articular

Elongated patellofemoral joint

Adjustment in arthroscopic surgical technique

Use of 2.4-mm arthroscope, instead of 4.0-mm arthroscope

Placement of anterior portals distal to the level of the inferior pole of the patella when the knee is at 90° of flexion

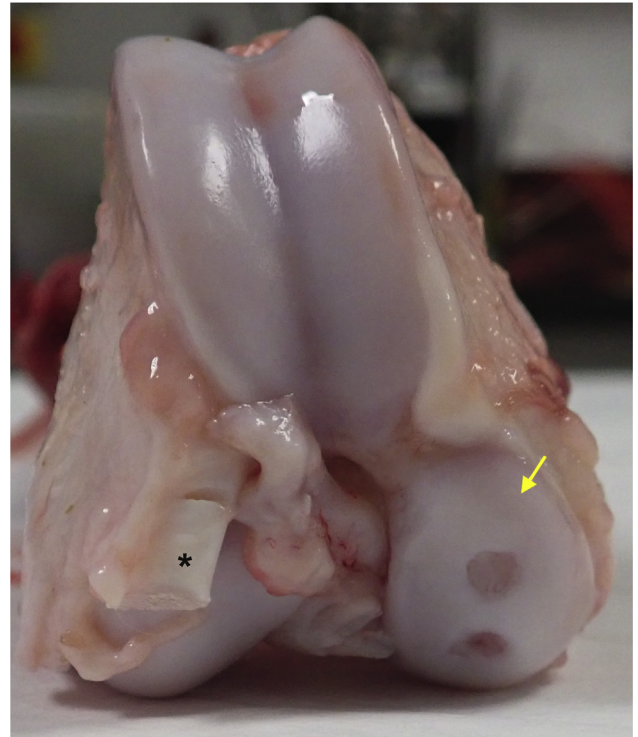
Arthroscope should be first introduced into the infrapatellar compartments

Need to retract EDL to fully visualize the lateral compartment

Through the anterior portals, only the middle and distal trochlea can be visualized. An accessory superolateral or superomedial portal is needed to access the proximal patellofemoral joint

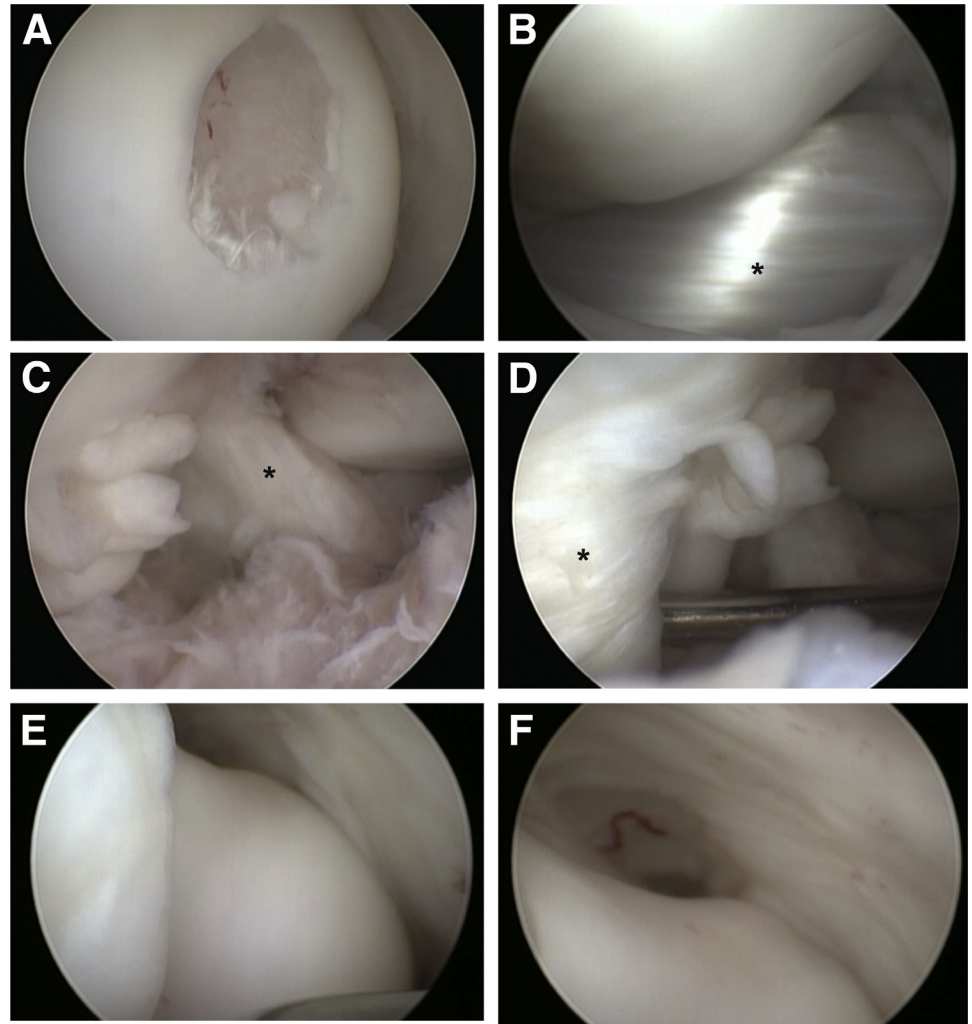
EDL, Extensor digitorum longus.

and Fig 3). The anterolateral portal is established with an 11-blade scalpel, and the arthroscope is placed intra-articularly and directed posterior and medial to the infrapatellar fat pad. The joint is then insufflated. The anteromedial portal can then be made under direct visualization with spinal needle localization and



**Fig 3.** Cadaveric specimen of a right minipig distal femur. Two chondral defects have been created on the medial femoral condyle (yellow arrow). Note the presence of the extensor digitorum longus (cut and marked by \*) originating from the cranio-lateral aspect of the lateral femoral condyle and the relative length of the trochlea compared to that in humans.

**Fig 4.** Viewing from the antero-lateral portal of the right minipig knee, intra-articular arthroscopic visualization of the (A) medial femoral condyle with a surgically created 5-mm chondral defect, (B) medial meniscus (marked by \*), (C) intercondylar notch and anterior cruciate ligament (marked by \*), (D) lateral compartment with an arthroscopic probe behind the extensor digitorum longus and its synovial tendon sheath (marked by \*), which is intra-articular in the minipig stifle, (E) distal trochlea, and (F) medial gutter.



established with the 11-blade scalpel. A hemostat may be used to slightly enlarge the portals to facilitate easy passage of arthroscopic instruments.

After irrigation of the joint, a standard arthroscopic examination can be performed (Video 1). The arthroscope can be directed to the medial compartment to visualize the medial femoral condyle and anterior horn and body of the medial meniscus (Fig. 4A and B). The knee can be extended to visualize the anterior aspect of the medial femoral condyle and flexed to visualize the posterior aspect of the medial femoral condyle. Visualization of the posterior horn of the medial meniscus can be difficult given the small size of the joint, even with a valgus force applied. An arthroscopic hook probe can be introduced through the anteromedial portal for manual palpation. The arthroscope can then be turned to visualize the intercondylar notch (Fig. 4C). The ligamentum mucosum can be released at its origin from the anterior intercondylar notch with an arthroscopic shaver to facilitate retraction of the

infrapatellar fat pad and visualization of the cruciate ligaments.

Visualization of the lateral compartment can be obtained with the arthroscope through the anterolateral portal but may be enhanced by placing the arthroscope through the anteromedial portal with the 30° arthroscope. Unlike in humans, the extensor digitorum longus tendon is intra-articular and originates from the cranio-lateral aspect of the lateral femoral condyle (Figs 3 and 4D). It can obstruct visualization of the anterior lateral femoral condyle. A hook probe may be used to retract the tendon for better visualization of the lateral femoral condyle and meniscus.

Finally, the middle and distal trochlea can be visualized by placing the knee in maximum extension (Fig 4E and F). Because of the elongated anatomy of the minipig trochlea and inability to extend the knee to 0°, the proximal trochlea and patella are typically not well visualized through the anterior portals. Therefore a superolateral or superomedial portal can be made to



**Fig 5.** Mini-pig resting in padded sling to maintain non-weightbearing while recovering from anesthesia after surgery.

access the proximal patellofemoral joint and suprapatellar pouch.

### Postoperative Protocol

The minipig is recovered from anesthesia in a padded suspension sling (Fig 5) to maintain protected weightbearing of the operated limb, followed by transfer to the pen after the animal is capable of standing independently (typically 3-5 hours after extubation). Commercially available minipig slings are commonly used for temporary restraint of the animal to allow for veterinary exams and medical procedures,

and other groups have used them to limit weightbearing of operated limbs after surgery.<sup>8</sup> After transfer to the pen, the minipigs are allowed activity as desired.

### Discussion

The minipig is an ideal preclinical animal model to study knee conditions and therapies because of its docile nature, sufficient cartilage thickness ( $\sim 2\text{-}3$  mm),<sup>1</sup> joint loading biomechanics that better simulate the adult human condition compared to other large animals,<sup>2,3</sup> and feasibility of arthroscopy of the stifle (knee) joint.<sup>4</sup> The porcine knee is much larger than canine knee and compares favorably in size to goat and sheep knees,<sup>7</sup> allowing for arthroscopy with standard surgical equipment used in humans. Many similarities exist between the human and minipig knee, and therefore arthroscopy skill sets are easily translatable between the two species. In fact, porcine knees have proven to be a valid model for arthroscopic surgical training and skill assessment.<sup>9</sup>

Minipigs are among one of several preferred large animal models for the study of knee ligament, cartilage, and meniscus treatments, and the ability to perform knee arthroscopy in these animals is valuable for testing the feasibility of arthroscopic methods and for second-look visualization of the treated tissue without needing to sacrifice the animal. For the Food and Drug Administration approval of new drugs, biologics, and devices, animal studies that assess endpoints such as safety, proof of concept for clinical efficacy, durability, and dose response, are typically required. To gain regulatory approval for clinical use of knee therapies in humans, translational large animal studies that are a minimum of 1 year in length are recommended. Second-look arthroscopic evaluations allow for longitudinal, interim assessments and are more cost-effective than magnetic resonance imaging. The minipig knee can be easily accessed with standard arthroscopy tools with good visualization of the medial and lateral compartments, intercondylar notch, and distal trochlea. Only the proximal trochlea and patella are difficult to visualize through the standard anterior portals. However, in many quadruped animals, an extended open medial or lateral parapatellar arthrotomy with subluxation of the patella often leads to iatrogenic patellar maltracking and instability postoperatively, even after meticulous repair of the retinaculum.<sup>10</sup> Therefore this portion of the trochlea is typically not a region used for scientific investigation.

In summary, the minipig is an ideal preclinical animal model for the investigation of therapies for the knee, in part because its knee joint is large enough to permit arthroscopy with the use of standard surgical equipment. Because the human and minipig knees are

very similar, an arthroscopy skill set for the human knee is easily translatable to the minipig knee.

### References

1. Frisbie DD, Cross MW, McIlwraith CW. A comparative study of articular cartilage thickness in the stifle of animal species used in human pre-clinical studies compared to articular cartilage thickness in the human knee. *Vet Comp Orthop Traumatol* 2006;19:142-146.
2. Jiang CC, Chiang H, Liao CJ, et al. Repair of porcine articular cartilage defect with a biphasic osteochondral composite. *J Orthop Res* 2007;25:1277-1290.
3. Chu CR, Szczodry M, Bruno S. Animal models for cartilage regeneration and repair. *Tissue Eng Part B Rev* 2010;16:105-115.
4. Zelle S, Zantop T, Schanz S, Petersen W. Arthroscopic techniques for the fixation of a three-dimensional scaffold for autologous chondrocyte transplantation: structural properties in an in vitro model. *Arthroscopy* 2007;23:1073-1078.
5. Christensen BB, Foldager CB, Olesen ML, et al. Experimental articular cartilage repair in the Gottingen minipig: the influence of multiple defects per knee. *J Exp Orthop* 2015;2:13.
6. Murray MM, Fleming BC. Use of a bioactive scaffold to stimulate anterior cruciate ligament healing also minimizes posttraumatic osteoarthritis after surgery. *Am J Sports Med* 2013;41:1762-1770.
7. Proffen BL, McElfresh M, Fleming BC, Murray MM. A comparative anatomical study of the human knee and six animal species. *Knee* 2012;19:493-499.
8. Smith AC, Swindle MM. Preparation of swine for the laboratory. *ILAR J* 2006;47:358-363.
9. Martin RK, Gillis D, Leiter J, Shantz JS, MacDonald P. A Porcine Knee Model Is Valid for Use in the Evaluation of Arthroscopic Skills: A Pilot Study. *Clin Orthop Relat Res* 2016;474:965-970.
10. Orth P, Madry H. A low morbidity surgical approach to the sheep femoral trochlea. *BMC Musculoskelet Disord* 2013;14:5.