



Case report

Treatment of a periprosthetic femur fracture around an antibiotic spacer with revision and an antibiotic plate

Joey P. Johnson, MD^{a,*}, Eric M. Cohen, MD^b, Valentin Antoci, MD^b^a Department of Orthopaedic Surgery, Loma Linda University, Loma Linda, CA, USA^b Division of Adult Reconstruction, Department of Orthopaedic Surgery, Warren Alpert Medical School, Brown University, Providence, RI, USA

ARTICLE INFO

Article history:

Received 4 April 2018

Received in revised form

23 August 2019

Accepted 20 September 2019

Available online 26 October 2019

Keywords:

Periprosthetic infection

Periprosthetic fracture

Revision surgery

ABSTRACT

Infection following total hip arthroplasty can be a devastating complication, often necessitating a 2-stage surgery with the temporary placement of an antibiotic spacer. Fracture around this spacer is an uncommon complication that presents serious treatment challenges. Our manuscript details the successful surgical treatment of a previously unreported fracture around an antibiotic spacer, treated with revision to a hemiarthroplasty and placement of an antibiotic plate.

© 2019 The Authors. Published by Elsevier Inc. on behalf of The American Association of Hip and Knee Surgeons. This is an open access article under the CC BY-NC-ND license (<http://creativecommons.org/licenses/by-nc-nd/4.0/>).

Introduction

Total hip arthroplasty is a reliable and effective surgery that accounts for significant improvement in patient pain and reported quality of life measures [1]. As the American population continues to age, the number of patients receiving total joint replacement will continue to rise. Current numbers suggest that more than 4 million total joint arthroplasties will be performed in the United States by 2030 [2]. As the total number of joint arthroplasties increase, complications such as periprosthetic infections and periprosthetic fractures are becoming more common clinical problems [3]. In fact, the number of revision surgeries is expected to rise exponentially faster than primary surgery [4]. Even though the device industry is focusing on new implant design and ongrowth surfaces, the largest economic burden in total joint arthroplasty is periprosthetic infection [5]. Significant time and effort has been invested in developing protocols to prevent periprosthetic infection and minimize the cost associated with treating periprosthetic infection [5,6]. The current gold standard of treating periprosthetic infections

remains a 2-stage approach with explantation of components and insertion of a temporary antibiotic-loaded spacer [7,8]. The success of this approach has a reported 70%–90% cure rate [9]. Unfortunately, a 2-stage procedure is not without complications, often leading to further bone loss, stiffness, dislocation, and even periprosthetic fracture. The combination of deep infection and subsequent periprosthetic fracture around an antibiotic spacer is uncommon, devastating, and likely necessitates prolonged antibiotic treatment, multiple operative interventions, and leads to poor outcomes [10–12].

The current published literature suggests that the combination of infection, spacer placement, and subsequent periprosthetic fracture is a very rare occurrence and has only been previously described in case reports. As a result, there is no consensus on an appropriate treatment protocol. We present the case of a patient who sustained a femoral neck fracture and was treated acutely with a total hip arthroplasty at an outside facility. She subsequently developed a deep periprosthetic infection 3 years after her index surgery, which was treated with explantation and placement of antibiotic spacer. Her clinical course was further complicated by a postoperative Vancouver C periprosthetic femur fracture distal to her antibiotic spacer that was placed to treat the infection [13]. To address this clinical problem, we report on a novel method of treatment with the use of an antibiotic-coated locking plate in combination with revision arthroplasty using an antibiotic-loaded cemented hemiarthroplasty for definitive treatment of her fracture and infection.

No author associated with this paper has disclosed any potential or pertinent conflicts which may be perceived to have impending conflict with this work. For full disclosure statements refer to <https://doi.org/10.1016/j.artd.2019.09.007>.

* Corresponding author. Department of Orthopaedic Surgery, Loma Linda University, 11406 Loma Linda Drive, Suite 128, Loma Linda, CA 92354, USA. Tel.: +1 909 558 2808.

E-mail address: joey.johnson12@gmail.com

<https://doi.org/10.1016/j.artd.2019.09.007>

2352–3441/© 2019 The Authors. Published by Elsevier Inc. on behalf of The American Association of Hip and Knee Surgeons. This is an open access article under the CC BY-NC-ND license (<http://creativecommons.org/licenses/by-nc-nd/4.0/>).

Case history

A 63-year-old healthy female sustained a left femoral neck fracture and presented to an outside hospital where she was treated with a cemented stem total hip arthroplasty. Her only comorbidities at the time of injury were hyperlipidemia and hypertension. The patient tolerated the procedure well, sustained no complications, and had a full functional recovery. Three years after her index surgery, she returned to her treating physician with increasing left hip and thigh pain. Inflammatory labs were elevated, imaging was concerning for early osteolysis, and her hip aspirate was inconclusive. She returned to the operating room, where frozen section and gross inspection were consistent with infection. Complete explant of the total hip commenced through a top-out technique not requiring osteotomy. During the surgery, it was noted that a cortical breach occurred; this was used as a window to remove cement and was later prophylactically stabilized with a cerclage wire. Her implants were removed, and a PROSTALAC (DePuy Synthes, West Chester, PA) prefabricated antibiotic hip spacer impregnated with tobramycin and vancomycin was placed. Intraoperative cultures grew out *Enterobacter cloacae* and *Staphylococcus epidermidis*, and she was started on a course of intravenous vancomycin and oral levofloxacin. Two months later, she had continued hip pain, increasing erythrocyte sedimentation rate and C-reactive protein, and concern for persistent infection. The decision was made to return to the operating room for repeat debridement, removal of antibiotic spacer, and placement of a new prefabricated antibiotic hip spacer. Cultures from this second intervention grew *Staphylococcus hominis*, and, according to sensitivities, intravenous vancomycin was continued. Unfortunately, 2 weeks following this operative intervention, she fell at home and sustained a femur fracture around the stem of her antibiotic spacer. The patient was transferred to our Level 1 Trauma tertiary referral center for further care. She provided informed consent for the publication of her clinical material at the time of admission. Imaging revealed a Vancouver C femur fracture distal to the implant

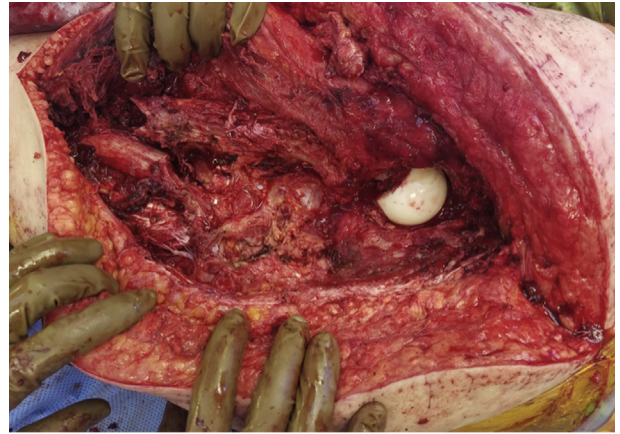


Figure 2. Lateral approach to the fracture site with the PROSTALAC implant dislocated.

and also the presence of a retained intramedullary cement plug from a previous surgery (Fig. 1). C-reactive protein was 71 mg/L, and erythrocyte sedimentation rate was 60 mm/h.

The patient was taken to the operating room with plan for explantation of components, extensive irrigation and debridement including recovery of the remaining cement, fracture fixation, and placement of a new antibiotic spacer. In the lateral decubitus position, her previous posterolateral approach was used and extended distally into a subvastus approach to visualize the fracture (Fig. 2). The hip did not show any gross signs of infection. Once her antibiotic hip spacer was removed, a thorough debridement was undertaken, and samples from the hip joint, spacer, fracture site, soft tissues, and canal were sent for gram stain and culture. The fracture site was opened, and the distal cement fragments were retrieved using curettes and a long pituitary rongeur. Interestingly, we identified and removed the plastic centralizer from her index surgery, which had not been mentioned in prior operative reports. To

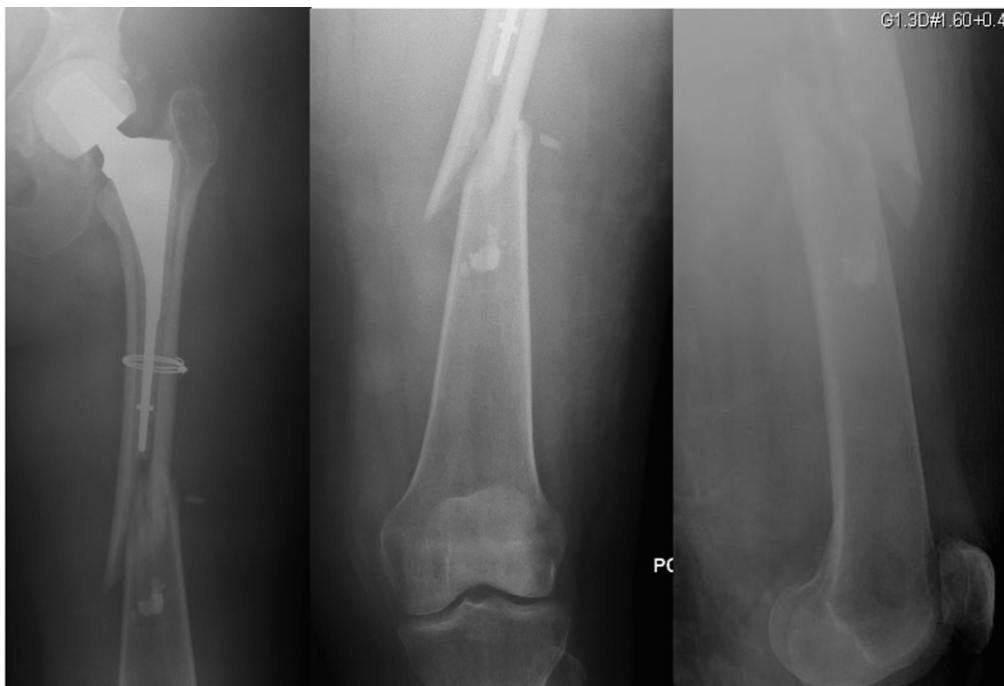

Figure 1. Injury films demonstrating retained cement distal to the fracture site, and the PROSTALAC spacer.

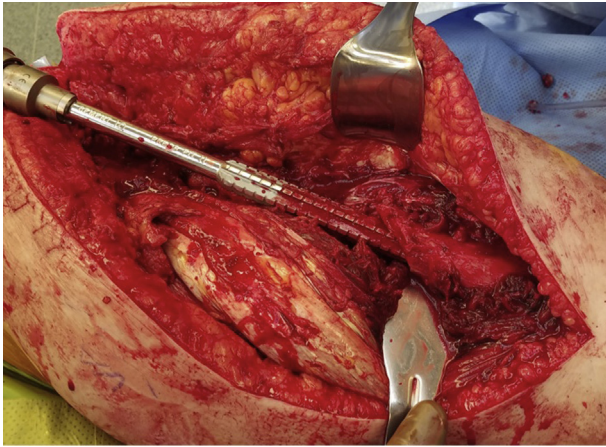


Figure 3. To allow for adequate debridement and removal of all remaining cement, the reamer was introduced to the distal fragment.

ensure all cement was removed, the proximal and distal fragments were reamed before fracture reduction (Fig. 3). Once debridement was complete, the wound and canal were thoroughly irrigated with 9 L of pulse lavage fluid, covering all surfaces including the entire femur using a long nozzle tip.

Attention was then turned to the femur fracture, which was reduced and provisionally stabilized with two 18-gauge wires prior to the placement of one Dall-Miles cable (Stryker Inc, Kalamazoo, MI) (Fig. 4). After reduction, the canal was again reamed with flexible reamers up to 16.5 mm. Then 2 packets of cement were impregnated with 600 mg of rifampin, 2.4 g of tobramycin, and 4 g of vancomycin, which was used to coat the implant inside the split chest tube (Fig. 5) [13]. Although the femur was being irrigated, reduced, and stabilized, a Synthes Endurance Revision Stem 250 mm bowed hemiarthroplasty (DePuy Synthes) was prepared on the back table. This implant was placed into a 36 French chest tube, which served as an antibiotic cement mold; the chest tube was split so the implant would fit. A 16-hole, 4.5-mm Synthes Lateral Locking plate (DePuy Synthes) was contoured, locking towers were applied so that the screw holes would remain patent and not be covered by cement, and then the impregnated cement was applied to the lateral border of the plate with the cement spatula (Fig. 5) [12]. By using rifampin, the cure rate of cement was slowed drastically which allowed plenty of time for molding and contouring [14].

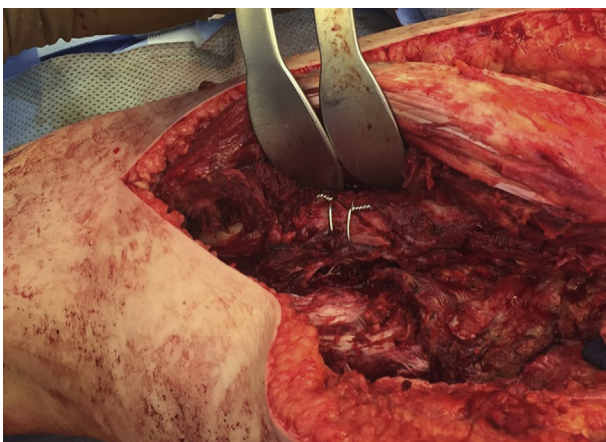


Figure 4. Provisional reduction of the femur undertaken with Dall-Miles cable passers and two 18-gauge wires.

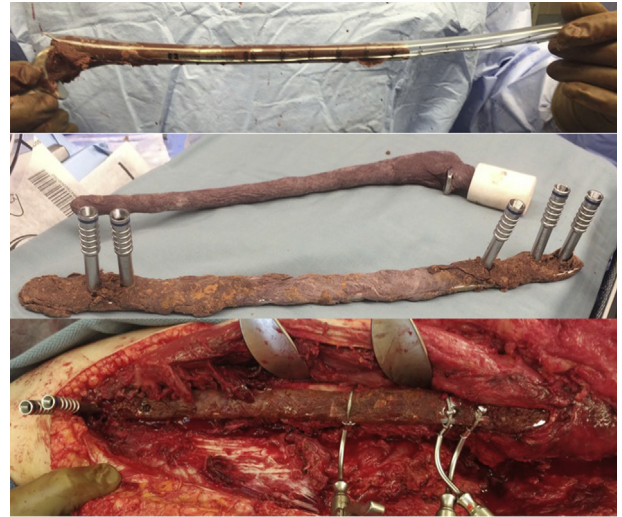

Figure 5. Cement coating of hemiarthroplasty using a split chest tube. Cement application to the locking plate with locking towers in place to maintain patency of screw holes. Lateral plate applied to the femur with cerclage cables placed for fixation.

Once all surfaces were prepared, the hemiarthroplasty implant was then seated by careful impaction, essentially obtaining press-fit stability. A metal hemiarthroplasty head was used filling the hollow hemiarthroplasty head with remaining cement. The hip was reduced and appeared to be stable both anteriorly and posteriorly, while leg length remained symmetrical. The lateral locking plate was fixed using cerclage wires and cables proximally, and a combination of locking screws, nonlocking screws, and cerclage wires distally (Fig. 6). The wound was closed, and an incisional negative pressure vacuum dressing (Kinetic Concepts Inc, San Antonio, TX) was used. Postoperatively, the patient was kept on intravenous vancomycin and levofloxacin for 6 weeks. Her intraoperative cultures were negative; this is likely due to her previous courses of antibiotics, and we treated this as a culture negative infection and antimicrobial therapy was selected based on her previous sensitivities. She was made touchdown weight bearing for 4 weeks followed by transition to partial weight bearing and full weight bearing by 10 weeks.

At 6-month follow-up, the patient was independent with no assistive devices. All of her wounds had healed. She had a mild limp which was expected considering her multiple surgeries, muscle scarring, and atrophy. The patient denied any thigh or groin pain and declined any further revision surgery to a total hip replacement. Imaging showed interval healing and consolidated callus formation around her initial fracture site (Fig. 7). Also at 6 months, her inflammatory markers had normalized. At 18 months, the patient was ambulating without pain, her fracture had healed (Fig. 8), she had not reaccumulated infection, and her Short Form-36 physical functioning score was 60 and her Harris Hip Score was 67.6.

Discussion

Periprosthetic infection represents a devastating complication associated with total joint arthroplasty, leading to disability, significant pain and suffering, and a huge expense to the healthcare system [15,16]. The gold standard for chronic periprosthetic infection involves explantation of components and revision to prosthetic with antibiotic-loaded acrylic bone cement. Nevertheless, the success of cure after a failed 1 or 2 stage is variable and often reported at less than 65% [17,18]. Retention of the antibiotic spacer is common, and chronic suppression is an option that may improve outcomes [19,20].

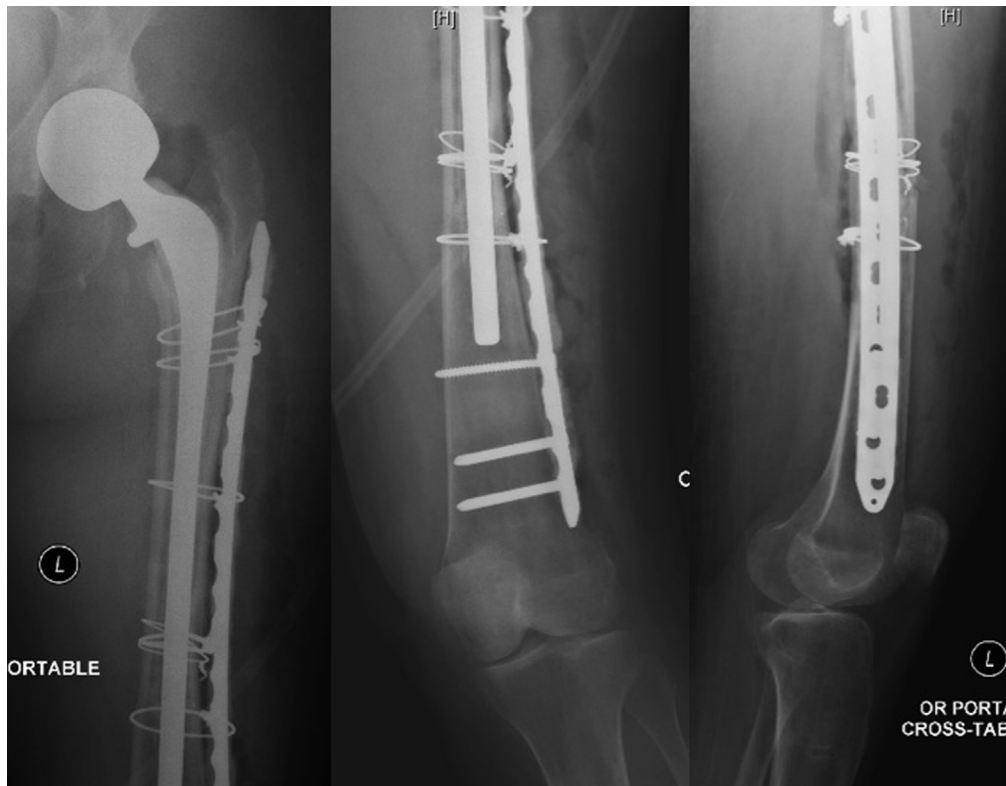

Figure 6. Postoperative films demonstrating fracture fixation and a long stem hemiarthroplasty.

At the same time, the rise of repeat surgery and revision hip arthroplasty has led to a rapid rise in periprosthetic fracture rates that account to over 4% in primary cases and more than 6% after revisions [21]. These fractures are difficult to treat and are associated with poor outcomes and increased mortality following total joint arthroplasty [22]. One study reports up to 7.3% mortality at 6 months and 7.3% of re-revision in the periprosthetic fracture

patients compared to matched controls [23]. There are several accepted treatment protocols proposed based on the Vancouver classification [24–26]. The management of Vancouver B fractures is still open to debate, with 1 study suggesting a 3-fold increase in mortality with fixation compared to revision arthroplasty [27]. In the case of Vancouver C fractures, open reduction with internal fixation is the standard recommended treatment, often with locked

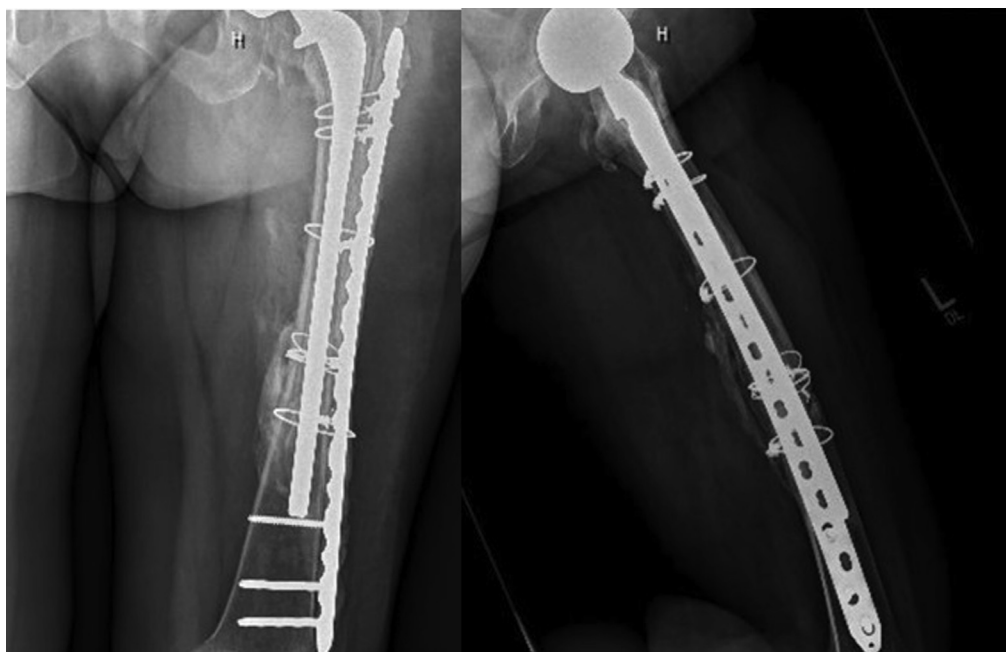


Figure 7. Follow-up films 6 months after hemiarthroplasty/plate fixation procedure showing robust interval callus formation.

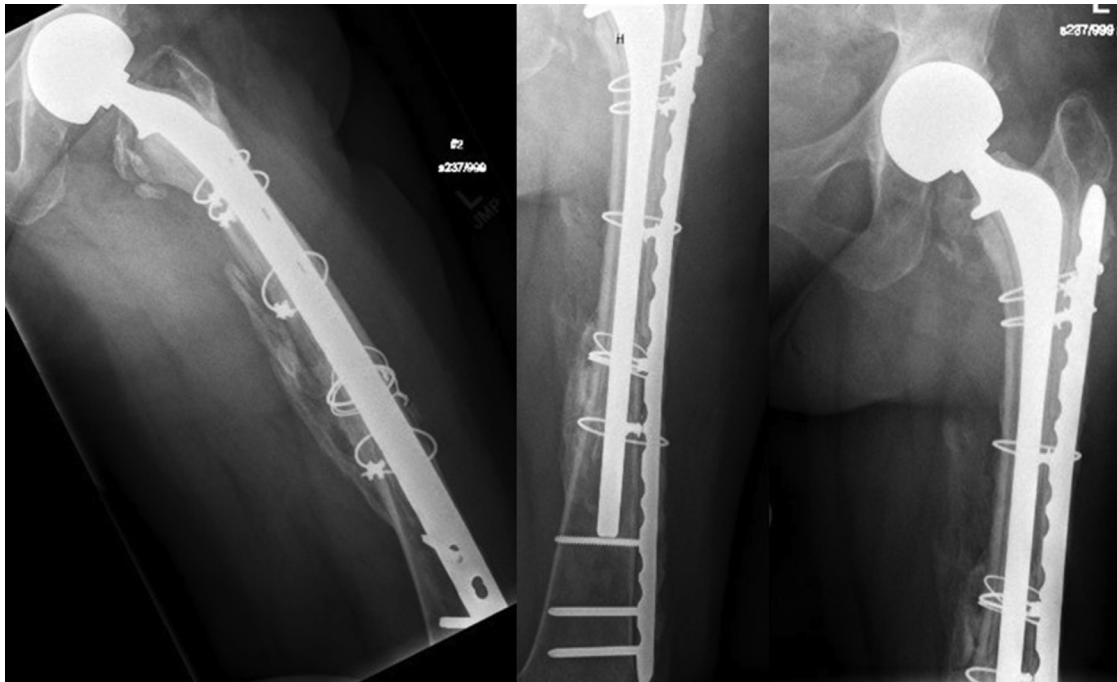


Figure 8. Follow-up films 18 months after surgery showing a united fracture.

plating using cerclage wires or cables proximally to reinforce the construct [26,28,29]. The combination of a Vancouver C fracture in the presence of the antibiotic hip spacer is more difficult to address.

Few case reports exist for infections associated with periprosthetic fractures, and there are no case reports of fractures around the base of antibiotic spacers with active infection. Liporace et al [12] describe a case in which a patient developed a deep infection after an intraoperative fracture during total hip arthroplasty. This infection was treated with an antibiotic spacer and antibiotic plate, and was later revised to a cementless total hip replacement. In this case, the infection seemed to have been related to fracture fixation, rather than the index arthroplasty procedure. Sherman et al [11] present a similar report wherein a patient developed a periprosthetic infection subsequent to a total hip revision complicated by a postoperative fracture requiring fixation. The authors report on a novel antibiotic spacer and revision to total femur, which was necessary because of the massive bone loss. Similarly to Liporace et al, the infection reported by Sherman et al was related to the periprosthetic fracture treatment rather than the total joint replacement.

Considering that the most recent revision for active infection in our patient was 2 weeks prior to the femur fracture and the chronic nature of her case, this would still be considered an active infection requiring further management as a periprosthetic deep infection. Although the primary goal would seem to be fracture management, the presence of deep infection required a change from the standard protocol. We surveyed 5 fellowship-trained academic arthroplasty surgeons from 3 different Level 1 institutions and received varied input regarding management. The possible treatment options suggested included (1) a lateral approach to the femur and fracture fixation with periprosthetic plate, (2) revision arthroplasty with a long stem antibiotic hip spacer, (3) revision arthroplasty as a single stage procedure to a long stem press-fit implant, (4) revision arthroplasty to a long stem antibiotic hip spacer and fracture fixation with lateral plate, and (5) explantation of components and protected weight bearing as in the case of resection arthroplasty with possible placement of an antibiotic-impregnated cement nail.

Considering that the presence of cement remnants in the medullary canal was a likely nidus of infection, we felt that the combination of an antibiotic-coated cemented hemiarthroplasty and antibiotic plate would achieve both fracture union and treatment of the patient's periprosthetic infection. We hoped that this would be the patient's final procedure even though the option to perform a final stage revision total hip arthroplasty remains available. In a shared decision process with the patient, all available options were carefully presented to the patient. The decision was that simultaneously stabilizing the fracture and treating the infection, with the possibility of not performing any additional surgeries in the future, would be the optimal solution. Eighteen months after her procedure, the patient is able to ambulate comfortably and independently, and she does not desire any further operative interventions.

Summary

We report on the novel combination of an antibiotic-coated plate and an antibiotic-coated long stem hemiarthroplasty for the treatment of a Vancouver C femur fracture around a prefabricated antibiotic hip spacer. The current case is unique and represents the first case report of a Vancouver C femur fracture around an antibiotic hip spacer. The use of rifampin in antibiotic cement allowed significantly slower cure rates, allowing for easier coating and careful molding of cement around the implants [14]. Ultimately, this combination of treatment modalities addresses the need to treat both the fracture and the deep infection during a single stage procedure. This approach maximizes the patient's return to normal function and ambulatory status, while limiting the number of future operations that the patient would require. Although there is currently no standard treatment protocol for this specific clinical scenario, the management approach used in this case was effective and may be applicable to similar cases. Nevertheless, we recommend great caution, careful planning, extensive patient counseling, and consideration of individual patient goals prior to the initiation of any treatment for a periprosthetic fracture in the setting of deep infection.

References

- [1] Liebs TR, Herzberg W, R uther W, et al. Quality adjusted life years gained by hip and knee replacement surgery and its aftercare. *Arch Phys Med Rehabil* 2016;97:691.
- [2] Kurtz S, Ong K, Lau E, Mowat F, Halpern M. Projections of primary and revision hip and knee arthroplasty in the United States from 2005 to 2030. *J Bone Joint Surg Am* 2007;89:780.
- [3] Pivec R, Issa K, Kapadia BH, et al. Incidence and future projections of periprosthetic femoral fracture following primary total hip arthroplasty: an analysis of international registry data. *J Long Term Eff Med Implants* 2015;25:269.
- [4] Kurtz S, Mowat F, Ong K, Chan N, Lau E, Halpern M. Prevalence of primary and revision total hip and knee arthroplasty in the United States from 1990 through 2002. *J Bone Joint Surg Am* 2005;87:1487.
- [5] Klouche S, Sariali E, Mamoudy P. Total hip arthroplasty revision due to infection: a cost analysis approach. *Orthop Traumatol Surg Res* 2010;96:124.
- [6] Gottschalk MB, Johnson JP, Sadlack CK, Mitchell PM. Decreased infection rates following total joint arthroplasty in a large county run teaching hospital: a single surgeon's experience and possible solution. *J Arthroplasty* 2014;29:1610.
- [7] Gehrke T, Alijanipour P, Parvizi J. The management of an infected total knee arthroplasty. *Bone Joint J* 2015;97–B:20.
- [8] Chen AF, Heller S, Parvizi J. Prosthetic joint infections. *Surg Clin North Am* 2014;94:1265.
- [9] Parvizi J, Zmistowski B, Adeli B. Periprosthetic joint infection: treatment options. *Orthopedics* 2010;33:659.
- [10] Schwab JH, Pagnano M, Haidukewych GJ, Trousdale R. A technique for treating periprosthetic fractures of the femur associated with deep prosthetic infection. *J Arthroplasty* 2003;18:211.
- [11] Sherman SL, Cunneen KP, Walcott-Sapp S, Brause B, Westrich GH. Custom total femur spacer and second-stage total femur arthroplasty as a novel approach to infection and periprosthetic fracture. *J Arthroplasty* 2008;23:781.
- [12] Liporace FA, Yoon RS, Frank MA, et al. Use of an 'antibiotic plate' for infected periprosthetic fracture in total hip arthroplasty. *J Orthop Trauma* 2012;26:e18.
- [13] Duncan CP, Masri BA. Fractures of the femur after hip replacement. *Instr Course Lect* 1995;44:293.
- [14] Han CD, Oh T, Cho S-N, Yang JH, Park KK. Isoniazid could be used for antibiotic-loaded bone cement for musculoskeletal tuberculosis: an in vitro study. *Clin Orthop* 2013;471:2400.
- [15] Berbari EF, Hanssen AD, Duffy MC, et al. Risk factors for prosthetic joint infection: case-control study. *Clin Infect Dis* 1998;27:1247.
- [16] Widmer AF. New developments in diagnosis and treatment of infection in orthopedic implants. *Clin Infect Dis* 2001;33(Suppl 2):S94.
- [17] Mittal Y, Fehring TK, Hanssen A, Marculescu C, Odum SM, Osmon D. Two-stage reimplantation for periprosthetic knee infection involving resistant organisms. *J Bone Joint Surg Am* 2007;89:1227.
- [18] Kheir MM, Tan TL, Gomez MM, Chen AF, Parvizi J. Patients with failed prior two-stage exchange have poor outcomes after further surgical intervention. *J Arthroplasty* 2017;32:1262.
- [19] Gomez MM, Tan TL, Manrique J, Deirmengian GK, Parvizi J. The fate of spacers in the treatment of periprosthetic joint infection. *J Bone Joint Surg Am* 2015;97:1495.
- [20] Siqueira MBP, Saleh A, Klika AK, et al. Chronic suppression of periprosthetic joint infections with oral antibiotics increases infection-free survivorship. *J Bone Joint Surg Am* 2015;97:1220.
- [21] Marsland D, Mears SC. A review of periprosthetic femoral fractures associated with total hip arthroplasty. *Geriatr Orthop Surg Rehabil* 2012;3:107.
- [22] Zuurmond RG, van Wijhe W, van Raay JJaM, Bulstra SK. High incidence of complications and poor clinical outcome in the operative treatment of periprosthetic femoral fractures: an analysis of 71 cases. *Injury* 2010;41:629.
- [23] Young SW, Walker CG, Pitto RP. Functional outcome of femoral peri prosthetic fracture and revision hip arthroplasty: a matched-pair study from the New Zealand Registry. *Acta Orthop* 2008;79:483.
- [24] Learmonth ID. The management of periprosthetic fractures around the femoral stem. *J Bone Joint Surg Br* 2004;86:13.
- [25] Masri BA, Meek RMD, Duncan CP. Periprosthetic fractures evaluation and treatment. *Clin Orthop Relat Res* 2004:80.
- [26] Beals RK, Tower SS. Periprosthetic fractures of the femur. An analysis of 93 fractures. *Clin Orthop Relat Res* 1996:238.
- [27] Schwarzkopf R, Oni JK, Marwin SE. Total hip arthroplasty periprosthetic femoral fractures: a review of classification and current treatment. *Bull Hosp Jt Dis* (2013) 2013;71:68.
- [28] Kinov P, Volpin G, Sevi R, Tanchev PP, Antonov B, Hakim G. Surgical treatment of periprosthetic femoral fractures following hip arthroplasty: our institutional experience. *Injury* 2015;46:1945.
- [29] Moore RE, Baldwin K, Austin MS, Mehta S. A systematic review of open reduction and internal fixation of periprosthetic femur fractures with or without allograft strut, cerclage, and locked plates. *J Arthroplasty* 2014;29:872.