

Tenoplasty Combined With Amniotic Membrane Transplantation for Patients With Severe Ocular Burns Induced Anterior Segment Necrosis

Wen-yan Peng, MD,^{1,*} Li-wen He, MD, PhD,^{1,*} Peng Zeng, MD,^{2,*} Dong-cui Chen, MD,¹ and Shi-you Zhou, MD, PhD^{1,3}

This article describes a novel surgical technique for successful repair of intractable corneoscleral necrosis caused by severe ocular burns. In this prospective case series, 19 eyes of 15 consecutive patients with sectional scleral necrosis and persistent corneal epithelial defects were treated with tenoplasty and amniotic membrane transplantation. The main outcome measure was the stability of the ocular surface after reepithelialization and repair of defects. All patients underwent successful combined surgery involving tenoplasty and amniotic membrane transplantation, in which the conjunctival and corneal surfaces were reconstructed. The interval from injury to surgery was 37.4 ± 24.5 days (3–91 days), and the ocular surfaces became stabilized in 82.2 ± 35.4 days (26–156 days, median 87 days). At the final visit, all cases presented with corneal opacity and neovascularization to various degrees. The best-corrected visual acuity decreased from 2.83 ± 1.02 LogMAR preoperatively to 2.87 ± 1.31 LogMAR postoperatively. The results imply that tenoplasty combined with amniotic membrane transplantation could provide vascular supply to the ischemic sclera, repair defects in the conjunctiva, and promote corneal reepithelialization, thus facilitating ocular surface stabilization after burns.

Ocular burns are an ophthalmic emergency and are responsible for 11.5% to 22.1% of ocular injuries. They may occur accidentally in the workplace, laboratory, or home, or they may be the intentional result of an assault. Most burns occur in lower socioeconomic groups.^{1,2} Alkali chemicals are responsible for 60% of ocular burns.² Severe ocular burns can lead to anterior segment ischemia, extensive necrosis, and, consequently, corneoscleral melting.^{3,4}

In the acute phase of ocular burns, it is essential to make the ocular surface stable as soon as possible to prevent visual threats such as corneal melting and corneal neovascularization. In recent years, the amniotic membrane has increasingly been

used to treat acute ocular burns due to its anti-inflammatory and anti-fibrotic properties.^{5–9} It is usually used to promote corneal reepithelialization as a patch or to replace the necrotic conjunctiva and superficial cornea as a graft.^{10,11} However, amniotic membrane grafts have failed to repair conjunctival defects when the underlying sclera was ischemic.^{12,13}

In cases of severe burns with scleral necrosis, tenoplasty has been reported to successfully repair the necrotic conjunctival surface by separating a layer of vascularized Tenon's tissue from the adjacent area to cover the ischemic sclera.^{14,15} Tenon's tissue was believed to offer a bridge for migration of conjunctival- and limbal-derived epithelial cells. However, in cases with large scleral necrosis, conjunctiva repair is still challenging due to the shortage of Tenon's tissue in patients with severe burns.

Here, we report a novel surgical technique used to treat intractable ocular burns in 19 eyes of 15 patients, in which a single sheet of amniotic membrane was simultaneously used as a patch to cover the corneal surface and as a graft to repair the conjunctiva defect after transferring the adjacent Tenon's tissue onto the ischemic sclera. The success of the results suggests that this technique could be valuable for concurrently repairing conjunctival and corneal surfaces in patients with intractable corneoscleral ischemia caused by severe ocular burns.

METHODS

All patients were treated in the Corneal Division of Zhongshan Ophthalmic Center at Sun Yat-sen University from October 2012 to August 2018. The study conformed to the tenets of the Declaration of Helsinki. Before surgery, the possible advantages and disadvantages of the procedure were fully explained to all patients. Informed consent was obtained from every patient before surgery. All the patients in this study

¹State Key Laboratory of Ophthalmology, Zhongshan Ophthalmic Center, Sun Yat-sen University, Guangzhou 510060, China. ²Department of Ophthalmology, Guangdong Provincial Key Laboratory of Malignant Tumor Epigenetics and Gene Regulation, Sun Yat-sen Memorial Hospital, Sun Yat-sen University, Guangzhou 510000, China.

*W.-y.P., L.-w.H., and P.Z. contributed equally to this work.

Funding: This work was partly supported by "Guangdong Funding for Scientific and Technological Projects" [Grant number: 2015A050502025] and the "Fundamental Research Funds of the State Key Laboratory of Ophthalmology" [Grant number: 30306020240020149] in China. The sponsors or funding organizations had no role in the design or conduct of this research.

Conflict of interest statement: The authors report no conflicts of interest.

Author contributions: All authors participated in the study design, protocol creation, data analysis, manuscript writing, and critical revisions.

³Address correspondence to Shi-you Zhou, MD, PhD, State Key Laboratory of Ophthalmology, Zhongshan Ophthalmic Center, Sun Yat-sen University, Guangzhou 510060, China. Email: zhoushiy@mail.sysu.edu.cn

© The Author(s) 2020. Published by Oxford University Press on behalf of the American Burn Association.

This is an Open Access article distributed under the terms of the Creative Commons Attribution Non-Commercial License (<http://creativecommons.org/licenses/by-nc/4.0/>), which permits non-commercial re-use, distribution, and reproduction in any medium, provided the original work is properly cited. For commercial re-use, please contact journals.permissions@oup.com

doi:10.1093/jbcr/iraa016

had severe sclerocorneal ischemia due to chemical or thermal burns. They had received emergency treatment, including copious irrigation, intense short-term topical steroids, ocular lubricants, and focal antibiotic eyedrops, in order to prevent secondary infection and promote reepithelialization before enrollment at our hospital. All cases showed no signs of infection, and no microbial cultures were conducted.

The inclusion criteria for enrollment were as follows: 1) a recent history of chemical or thermal eye burns; 2) an adult patient with persistent corneal epithelial, conjunctival, and Tenon's tissue defects as well as ischemic sclera; 3) a circumference of residual healthy corneal limbus greater than two clocks; 4) treatment history of one or multiple patching(s) with amniotic membrane; and 5) failure of systemic administration with vasodilators and topical agents to promote epithelial proliferation for more than 2 weeks. The exclusion criteria were as follows: 1) suspicious ocular surface infection and 2) uncontrolled hypertension, pregnancy, or a history of thromboembolic events.

The procedure was performed after retrobulbar anesthesia with 2% lidocaine and topical anesthesia with proparacaine hydrochloride eye drops (Alcaine® eye drops, Alcon Inc., Texas). One or two limbal traction sutures (6-0 absorbable suture, Vicryl, Ethicon Inc.) were used to rotate the eye in the necessary direction. First, the necrotic superficial sclera and corneal tissues were excised with scissors and a blade. Then, the conjunctival edges surrounding the necrotic area were opened and the residual Tenon's tissues adjacent to the defects were separated and relaxed to cover the ischemic scleral surface. The Tenon's graft was fixed to the superficial sclera with 8-0 Vicryl interrupted suture bites. The bridge to its base should be no less than 5 mm wide. Finally, the exposed Tenon's graft and corneal surfaces were covered by a sheet of a cryopreserved amniotic membrane with the epithelium up (provided by Guangdong Provincial Eye Bank, Guangzhou, China). The amnion was connected to the residual conjunctiva and fixed to the episclera

with 8-0 Vicryl interrupted suture bites and to the cornea with a running 10-0 nylon suture (Figure 1). After surgery, the operated eye was patched for 1 day and then a therapeutic bandage contact lens was worn (Purevision®, Bausch & Lomb Incorporated, Rochester, NY). All patients were administered oral doxycycline (0.1 g, twice daily) for 10 days and topical sodium hyaluronate eye drops (0.3% Hialid eyedrops®, Santen Pharmaceutical Co. LTD., Osaka, Japan) during the follow-up. Patients were examined postoperatively on days 1 and 7, then every week until 2 months postoperative, every month for half a year, and then every 2 months afterward. A best-corrected visual acuity (BCVA) test, digital photography, and other regular examinations were performed at each follow-up visit.

During the close follow-up, the amniotic membrane on the cornea was trimmed along the limbus if the corneal surface was reepithelialized or the amnion was collapsed from the cornea. The criteria for evaluating ocular surface stability are reepithelialization of the ocular surface, repair of necrotic tissue, and fading of ocular congestion. Visual acuity of less than 20/200, counting fingers, and hand motion or light perception were given values of 2, 3, and 4, respectively, for the LogMAR algorithm.

RESULTS

Baseline Characteristics and Surgical Results

In total, 19 eyes (12 left eyes and 7 right eyes) of 15 patients (11 males and 4 females) with ocular burn-induced anterior segment necrosis and corneal epithelial defects were included. Their mean age was 46.0 ± 6.6 years (range: 35–56 years). Among the eyes, one had thermal burns, two had acid burns, and the others had alkali burns. The mean preoperative BCVA was 2.83 ± 1.02 LogMAR (17 eyes with less than 20/200 vision according to the Snellen eye chart). The patients' information is summarized in Table 1.

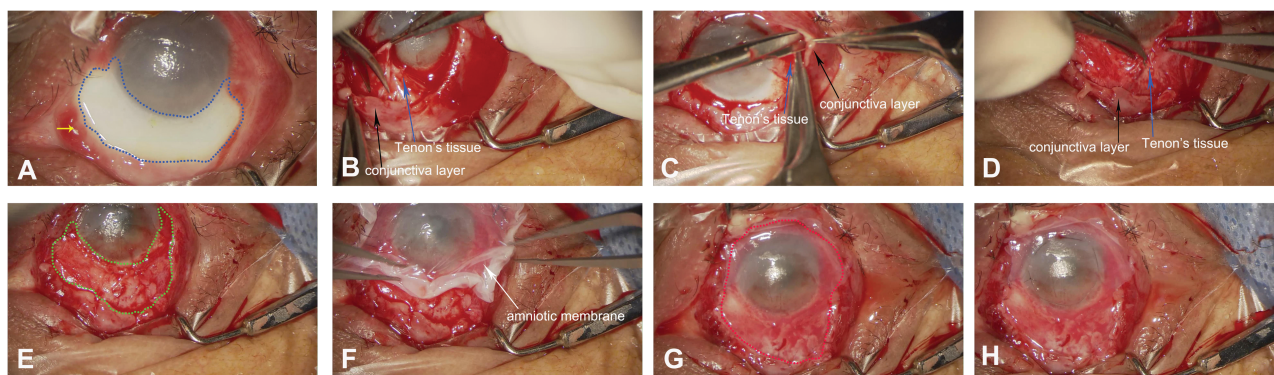


Figure 1. Surgical steps involved in the combination of tenoplasty with amniotic membrane transplantation. A. The chemical injured eye had conjunctival necrosis and limbal failure from 4 to 8 o'clock inferiorly. The defective conjunctiva and ischemic sclera had a breadth of 7 to 8 mm and reached the conjunctival fornix (area in the blue dotted line). The conjunctival border along the necrotic sclera was granulomatous (yellow arrow). B and C. The conjunctival edge surrounding the necrotic area was opened, and the adjacent Tenon's tissues (blue arrow) were separated from the neighboring area beneath the residual conjunctiva layer (black arrow). D and E. The separated Tenon's tissues were freed and fixed onto the ischemic sclera with 8-0 Vicryl interrupted suture bites (green dotted line area in E). F. Placement of the amniotic membrane (white arrow) over the surface of the Tenon's graft and corneal surface. G. The amniotic membrane was trimmed to fit the conjunctival defects and cover—and extend beyond—the entire cornea (area in the red dotted line). H. The amniotic membrane graft was fixed onto the episclera using interrupted 8-0 Vicryl sutures at the junction with residual conjunctiva and the sites 2 mm away from corneal limbus, and then it was anchored onto the cornea using a running 10-0 nylon suture

Table 1. Information about the patients in this study

Patient No.	Age/Sex	Agent/Eye	Scleral Ischemia Before Surgery* (clocks)	Limbal Ischemia Before Surgery (clocks)	Corneal Epithelial Defect (mm)	Other Ocular Findings Upon Presentation	Prior Surgeries	Days Between Injury and Surgery	Pre-VA	Last Visit	Follow-up†
1	40/M	Alkali/L	5.5 mm, 5 clocks	9 clocks	10 × 10 mm	Secondary glaucoma Secondary cataract Corneal ulcer	AMT	72 d	0.3	0.3	58 d
2	35/M	Alkali/R	8.1 mm, 7.5 clocks	9 clocks	Total	Corneal ulcer	3AMT	91 d	HM	LP	113 d
3	43/M	Alkali/L	4.5 mm, 8 clocks	8.5 clocks	Total	Corneal perforation	3AMT	90 d	LP	LP	113 d
4	49/M	Alkali/R	7 mm, 6 clocks	10 clocks	Total	Secondary cataract	AMT	26 d	HM	LP	90 d
		Alkali/R	To the fornix 5 clocks	5.5 clocks	Total	Corneal opacity	AMT	28 d	HM	LP	89 d
5	43/M	Alkali/L	To the fornix 4.5 clocks	6.5 clocks	Total	Corneal opacity	AMT	30 d	HM	LP	87 d
6	52/M	Alkali/R	5.6 mm, 5 clocks	7 clocks	8 × 10 mm	-	AMT	21 d	HM	HM	72 d
7	40/M	Acid/L	6 mm, 10 clocks	10 clocks	Total	Secondary glaucoma	2AMT	33 d	HM	HM	26 d
		Alkali/R	4 mm, 5 clocks	7.5 clocks	Total	Corneal opacity	AMT	18 d	CF	0.02	95 d
8	42/F	Alkali/L	2 mm, 1.5 clocks	6 clocks	6 × 10 mm	-	AMT	25 d	0.3	0.4	88 d
9	44/M	Alkali/L	6 mm, 4 clocks	6 clocks	8 × 10 mm	-	AMT	16 d	CF	0.12	30 d
10	37/M	Thermal/L	6.5 mm, 5.5 clocks	6.5 clocks	6.5 × 9.5 mm	-	AMT	31 d	HM	CF	45 d
		Alkali/R	3.5 mm, 3 clocks	3 clocks	5 × 5 mm	Eyelid burns	2AMT	60 d	HM	CF	54 d
11	52/F	Alkali/R	3 mm, 5 clocks	5 clocks	Total	Corneal ulcer	2AMT	31 d	LP	LP	59 d
12	52/F	Alkali/L	4.5 mm, 6.5 clocks	6 clocks	Total	Age-related cataract	AMT	44 d	HM	LP	64 d
13	54/M	Alkali/R	To the fornix 7 clocks	9 clocks	Total	Secondary glaucoma Corneal opacity	AMT	22d	LP	LP	131 d
14	51/M	Alkali/L	3.5 mm, 3 clocks	5 clocks	total	Eyelid burns	AMT	3 d	CF	CF	60 d
15	56/F	Acid/L	5 mm, 6.5 clocks	9 clocks	8 × 10 mm	Secondary glaucoma Corneal ulcer	2AMT	48 d	HM	LP	156 d

F, female; M, male; R, right eye; L, left eye; AMT, amniotic membrane transplantation; pre-VA, preoperative visual acuity; post-VA, postoperative visual acuity; HM, hand motion; CF, counting fingers; LP, light perception.

*The breadth of scleral ischemia from the corneal limbus (mm).

†The number of days from surgery to stability of the ocular surface.

All patients had received one or multiple amniotic membrane patches (once, $n = 13$; twice, $n = 4$; and triple, $n = 2$). The interval from the burns to the surgery varied from 3 to 91 days (mean: 37.4 ± 24.5 days). After the combined surgery with tenoplasty and amniotic membrane transplantation, all the patients' ocular surfaces were successfully reconstructed and reepithelialized with no corneal and scleral perforation. The burned ocular surface was stabilized within 26–156 days (mean: 82.2 ± 35.4 days; median: 87 days), and the integrity of the eyeballs was restored. At the final visits, all corneas were opaque to different degrees and featured peripheral neovascular vessels. Additionally, focal pseudopterygium was noted in five eyes, secondary glaucoma in seven eyes, secondary cataracts in eight eyes, mild symblepharon in three eyes, and eyelid entropion in five eyes. The mean postoperative BCVA was 2.87 ± 1.31 LogMAR (15 eyes less than 20/200). There was no significant difference in visual acuity between the preoperative and postoperative examinations.

Sample Cases

Case 9. This 44-year-old man experienced an alkali burn in the left eye 31 days before surgery and one prior treatment with amniotic membrane patching (Figure 2). At presentation, there was scleral and limbal ischemia with a breadth of 6.5 mm from 3:30 to 9 o'clock and a corneal epithelial defect of 6.5 mm \times 9.5 mm. His visual acuity was hand motion at 20 cm. After the combined surgery with tenoplasty and amniotic membrane transplantation, the burned ocular surface was successfully reconstructed and stabilized within 45 days. The cornea was opaque with peripheral neovascularization, and the intraocular pressure was higher than normal. Then, the patient was diagnosed as secondary glaucoma and treated with brinzolamide/timolol maleate eye drops (Alcon Laboratories, Inc., Fort Worth, Texas) and 0.2% brimonidine tartrate ophthalmic solution (Allergan Pharmaceuticals Ireland, Westport, County Mayo, Ireland). The BCVA at the final visit was counting fingers at 30 cm.

Case 10. A 37-year-old man with thermal burns presented 60 days before surgery with an opaque cornea, an epithelial defect of 5 mm \times 5 mm, and focal conjunctival and scleral necrosis with a breadth of 3.5 mm from 2 to 5 o'clock in the left eye (Figure 3). He had received amniotic membrane patching twice as part of a prior treatment. Before this treatment, his left eye had visual acuity of hand motion. After the combined surgery, the ocular surface was gradually stabilized, with reepithelialization within 54 days. The cornea was opaque in the center and neovascularized with pseudopterygium in the peripheral. The BCVA was counting fingers at 20 cm at the final visit due to corneal opacity and a secondary cataract.

DISCUSSION

Severe ocular burn is a serious injury with poor prognosis. In some patients, scleral and corneal necrosis usually occurs. Theoretically, all necrotic materials should be debrided and the ocular surface defects should be reconstructed as soon as possible to prevent eyeball perforation and make the ocular

surface stable, which will be helpful for subsequent treatments to recover vision.

In recent years, amniotic membrane transplantation has been recommended as the first choice for treating acute ocular burns. The amniotic membrane was demonstrated to be capable of promoting epithelial differentiation and proliferation, inhibiting corneal neovascularization, and facilitating anti-inflammatory and anti-fibrotic activities.^{16,17} However, in this case series, single or multiple amniotic membrane patches failed to reepithelialize the ocular surface, even though there was a partial residual healthy limbus. Failure was also reported in patients with grade IV burns, even after treatment with repeat amniotic membrane grafts.^{8,9,12,18–22} This failure may be attributed to the destruction of episcleral vasculatures in cases of severe ocular burns. The amniotic graft on the conjunctival surface survived better in eyes with grade II to III burns (using the Roper-Hall classification) than in those with grade IV burns.^{6,11,18,19,23}

For cases of scleral necrosis, tenoplasty was a useful way to provide a vascular pedicle for migration of conjunctival cells, especially those with refractory limbal ischemia, in the early period after severe ocular burns.^{24,25} It was considered a globe-saving procedure that could aid and accelerate reepithelialization of the cornea and conjunctiva. However, in cases with a section of scleral necrosis and diffuse limbal burns, the border of the residual conjunctiva was usually granulomatous and it was possible that the stem cells of both the conjunctival and corneal epithelium would be dysfunctional. In these conditions, there is a risk of delayed reepithelialization on Tenon's tissue's reconstructed conjunctival surface and the burned corneal surface.

Maintenance of globe integrity is a priority for doctors treating eye burns, as the patients may need additional corneal procedures to further improve visual acuity. Persistent corneal and scleral epithelial defects usually lead to ocular perforation, especially after eye burns. Delayed treatment may result in vision loss or even loss of the eye. The current management strategy for facilitating reepithelialization of the burned ocular surface includes placement of bandage contact lens, application of tissue adhesives, and surgical interventions such as tarsorrhaphy or amniotic membrane graft with or without cultivated epithelial cells.²⁶ However, they cannot achieve good results for patients with severe eye burns.

In this study, tenoplasty combined with amniotic membrane transplantation successfully reconstructed the ocular surfaces of patients with severe corneoscleral ischemia. The results showed that this novel technique was effective in providing vascular nourishment and promoting amniotic membrane graft survival. The amniotic membrane on the corneal surface functioned as a patch, reducing corneal inflammation, and promoting proliferation of residual limbal stem cells. This allowed the reepithelialized ocular surface to become stable later on. If the patient had diffused scleral ischemia in more than two-thirds of the area, the residual Tenon's tissues may not be enough to cover the necrotic conjunctival surface. If the entire corneal limbus was destroyed by burns, an amniotic membrane alone is insufficient to restore the limbal anatomy.^{8,11} Currently, for patients with total limbal stem cell deficiency, heterologous or cultured limbal stem cell transplantation is the standard therapy.^{27–29} However, donor

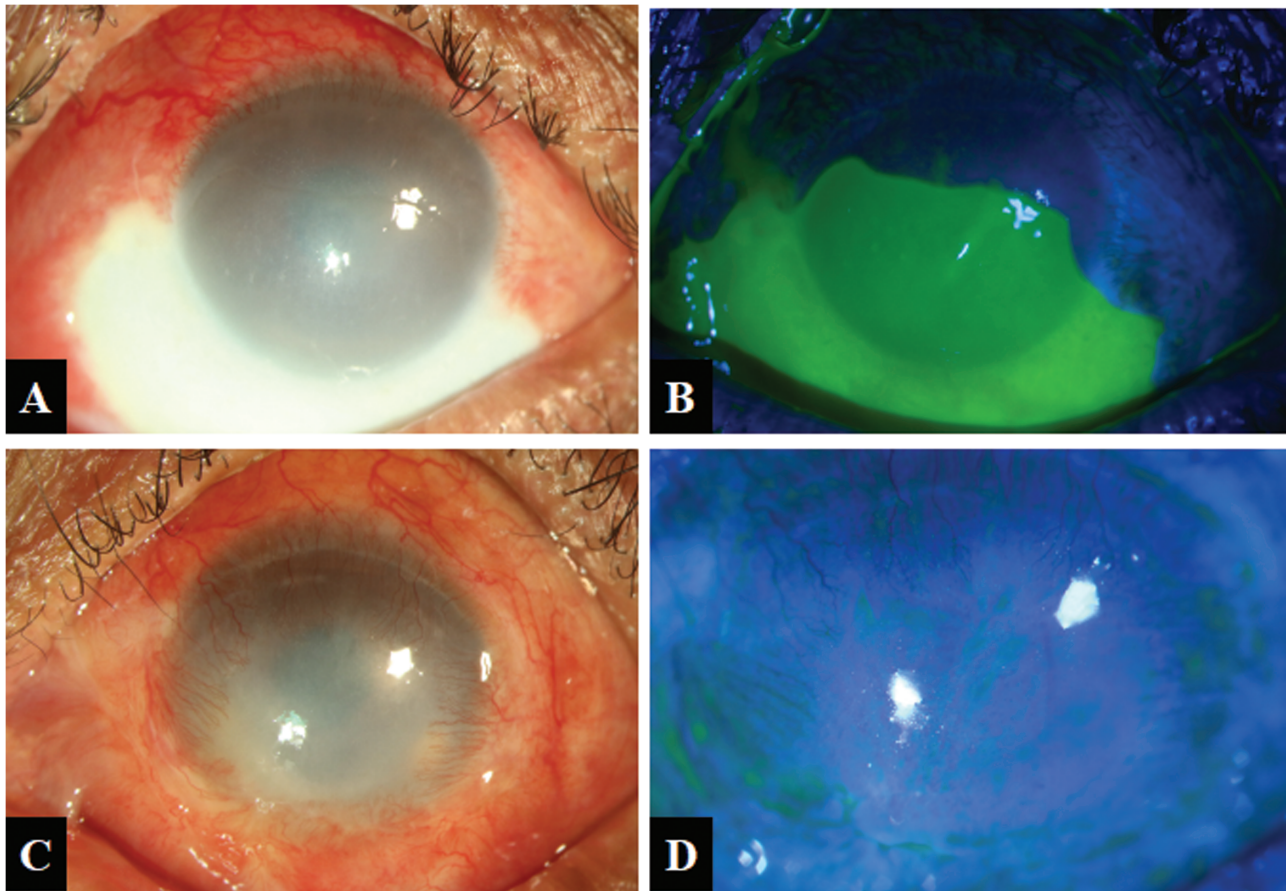


Figure 2. Slit-lamp photographs of case 9. A. Before surgery, the eye burned with sodium hydroxide presented with diffuse conjunctival defects and scleral ischemia with a breadth of 6.5 mm from 3:30 to 9 o'clock. B. Three-fifths of the defective conjunctival surface and inferior corneal surface showed positive fluorescein staining. C. The ocular surface of the burned eye was successfully reconstructed and stabilized 45 days after surgery combining tenoplasty with amniotic membrane transplantation. D. The cornea was opaque and vascularized at the peripheral without fluorescein staining

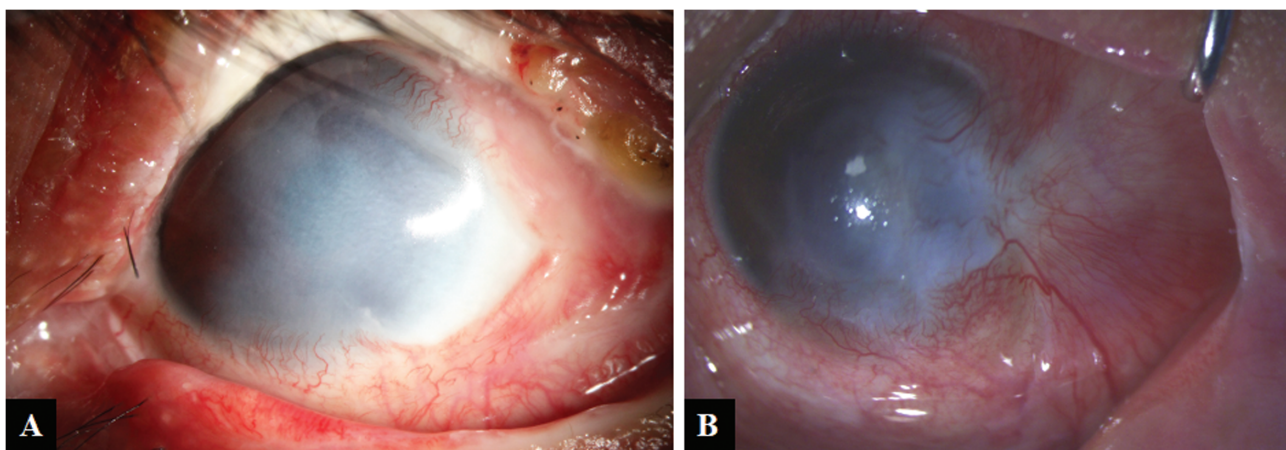


Figure 3. Slit-lamp photographs of case 10. A. Before surgery, the eye burned with liquid aluminum presented with conjunctival defects and scleral ischemia with a breadth of 3.5 mm from 2 to 5 o'clock. Two-thirds of the temporal corneal epithelium was defective. B. The burned ocular surface was successfully reconstructed and stabilized within 54 days after the combined surgery. It presented with corneal opacity, temporal pseudopterygium, and a secondary cataract

limbal allografts transplanted during the acute stage of ocular burns are rejected very quickly, even with systemic immunosuppression methods.²⁸ In this study, the amniotic membrane was used simultaneously as a graft to repair defective conjunctiva and as a patch on the cornea to promote corneal reepithelialization. This combined surgery can be performed at low costs in all hospitals and may be especially beneficial in developing countries.

In three eyes, mild symblepharon was formed without limitation of eye movement when the amniotic membrane graft was gradually resolved after surgery. In these patients, the breadth of the necrotic sclera was such that it reached near the conjunctival fornix. This suggests that the amniotic membrane graft may promote epithelial growth to a greater extent than an alternative conjunctival graft during the acute phase after ocular burns. The amniotic membrane was reported to treat and prevent the formation of symblepharon during the rest phase after burns.^{8,29}

The patients' BCVA was decreased from 2.83 ± 1.02 LogMAR preoperatively to 2.87 ± 1.31 LogMAR postoperatively, even though these eyes achieved ocular surface stability. This finding may be attributed to corneal opacity, secondary glaucoma, and cataracts. These situations need to be treated at appropriate times to prevent vision loss. A stable ocular surface is essential for successful treatment in the future.

CONCLUSION

The combination of a large sheet of an amniotic membrane with a tenonplasty could facilitate reconstruction and promote the stability of a burned ocular surface. The amniotic membrane acts as a graft for conjunctival reconstruction and as a patch for corneal surface reconstruction. The separated Tenon's tissues supply good nourishment to the ischemic sclera and the transplanted amnion. This novel technique may also be used to treat scleral melting caused by pterygium surgery or other factors.

ACKNOWLEDGMENT

The manuscript has not been presented at any meetings or submitted to any other journals.

REFERENCES

1. Wagoner MD. Chemical injuries of the eye: current concepts in pathophysiology and therapy. *Surv Ophthalmol* 1997;41:275-313.
2. Reim M, Redbrake C, Schrage N. Chemical and thermal injuries of the eyes. Surgical and medical treatment based on clinical and pathophysiological findings. *Arch Soc Esp Oftalmol* 2001;76:79-124.
3. White WL, Hollsten DA. Burns of the ocular adnexa. *Curr Opin Ophthalmol* 1994;5:74-7.
4. Kuckelkorn R, Schrage N, Keller G, Redbrake C. Emergency treatment of chemical and thermal eye burns. *Acta Ophthalmol Scand* 2002;80:4-10.
5. Liang X, Liu Z, Lin Y, Li N, Huang M, Wang Z. A modified symblepharon ring for sutureless amniotic membrane patch to treat acute ocular surface burns. *J Burn Care Res* 2012;33:e32-e38.
6. Sharma N, Lathi SS, Sehra SV et al. Comparison of umbilical cord serum and amniotic membrane transplantation in acute ocular chemical burns. *Br J Ophthalmol* 2015;99:669-73.
7. Sridhar MS, Bansal AK, Sangwan VS, Rao GN. Amniotic membrane transplantation in acute chemical and thermal injury. *Am J Ophthalmol* 2000;130:134-7.
8. Meller D, Pires RT, Mack RJ et al. Amniotic membrane transplantation for acute chemical or thermal burns. *Ophthalmology* 2000;107:980-9; discussion 990.
9. Tamhane A, Vajpayee RB, Biswas NR et al. Evaluation of amniotic membrane transplantation as an adjunct to medical therapy as compared with medical therapy alone in acute ocular burns. *Ophthalmology* 2005;112:1963-9.
10. Fish R, Davidson RS. Management of ocular thermal and chemical injuries, including amniotic membrane therapy. *Curr Opin Ophthalmol* 2010;21:317-21.
11. Tandon R, Gupta N, Kalaivani M, Sharma N, Titiyal JS, Vajpayee RB. Amniotic membrane transplantation as an adjunct to medical therapy in acute ocular burns. *Br J Ophthalmol* 2011;95:199-204.
12. Joseph A, Dua HS, King AJ. Failure of amniotic membrane transplantation in the treatment of acute ocular burns. *Br J Ophthalmol* 2001;85:1065-9.
13. Burcu A, Yalniz-Akkaya Z, Ozdemir MF, Erdem E, Onat MM, Ornek F. Surgical rehabilitation following ocular chemical injury. *Cutan Ocul Toxicol* 2014;33:42-8.
14. Kenyon KR. Decision-making in the therapy of external eye disease: noninfected corneal ulcers. *Ophthalmology* 1982;89:44-51.
15. Kuckelkorn R, Schrage N, Reim M. Treatment of severe eye burns by tenonplasty. *Lancet* 1995;345:657-8.
16. Dua HS, Gomes JA, King AJ, Maharajan VS. The amniotic membrane in ophthalmology. *Surv Ophthalmol* 2004;49:51-77.
17. Shay E, Kheirkhah A, Liang L, Sheha H, Gregory DG, Tseng SC. Amniotic membrane transplantation as a new therapy for the acute ocular manifestations of Stevens-Johnson syndrome and toxic epidermal necrolysis. *Surv Ophthalmol* 2009;54:686-96.
18. Arora R, Mehta D, Jain V. Amniotic membrane transplantation in acute chemical burns. *Eye (Lond)* 2005;19:273-8.
19. López-García JS, Rivas Jara L, García-Lozano I, Murube J. Histopathologic limbus evolution after alkaline burns. *Cornea* 2007;26:1043-8.
20. López-García JS, Rivas L, García-Lozano I, Murube J. Analysis of corneal surface evolution after moderate alkaline burns by using impression cytology. *Cornea* 2006;25:908-13.
21. Prabhasawat P, Tesavibul N, Prakairungthong N, Booranapong W. Efficacy of amniotic membrane patching for acute chemical and thermal ocular burns. *J Med Assoc Thai* 2007;90:319-26.
22. Tejwani S, Kolar RS, Sangwan VS, Rao GN. Role of amniotic membrane graft for ocular chemical and thermal injuries. *Cornea* 2007;26:21-6.
23. Kobayashi A, Shirao Y, Yoshita T et al. Temporary amniotic membrane patching for acute chemical burns. *Eye (Lond)* 2003;17:149-58.
24. Kuckelkorn R, Redbrake C, Reim M. Tenonplasty: a new surgical approach for the treatment of severe eye burns. *Ophthalmic Surg Lasers* 1997;28:105-10.
25. Iyer G, Srinivasan B, Agarwal S, Barbhaya R. Visual rehabilitation with keratoprosthesis after tenonplasty as the primary globe-saving procedure for severe ocular chemical injuries. *Graefes Arch Clin Exp Ophthalmol* 2012;50:1787-93.
26. Herndon DN, Jones JH. Total burn care. 5th ed. Edinburgh: Elsevier; 2018.
27. Liang L, Sheha H, Li J, Tseng SC. Limbal stem cell transplantation: new progresses and challenges. *Eye (Lond)* 2009;23:1946-53.
28. Baradaran-Rafi A, Eslani M, Djalilian AR. Complications of keratolimbal allograft surgery. *Cornea* 2013;32:561-6.
29. Shi W, Wang T, Gao H, Xie L. Management of severe ocular burns with symblepharon. *Graefes Arch Clin Exp Ophthalmol* 2009;247:101-6.