

ORIGINAL PAPER

doi: 10.5455/medarh.2017.71.5-11

Med Arch. 2017 Feb; 71(1): 5-11

Received: DEC 25, 2016 | Accepted: JAN 15, 2017

© 2017 Feriha Hadzagic-Catibusic, Edin Avdagic, Smail Zubcevic, Sajra Uzicanin

This is an Open Access article distributed under the terms of the Creative Commons Attribution Non-Commercial License (<http://creativecommons.org/licenses/by-nc/4.0/>) which permits unrestricted non-commercial use, distribution, and reproduction in any medium, provided the original work is properly cited.

Brain Lesions in Children with Unilateral Spastic Cerebral Palsy

Feriha Hadzagic-Catibusic¹, Edin Avdagic², Smail Zubcevic¹, Sajra Uzicanin¹

¹Pediatric Clinic, Clinical Center University of Sarajevo, Bosnia and Herzegovina

²Radiology Clinic, Clinical Center University of Sarajevo, Bosnia and Herzegovina

Corresponding author: Feriha Hadzagic-Catibusic, Patriotske lige 81, 71 000 Sarajevo, Bosna i Hercegovina. Tel. +387 33 566 446, Fax. +387 33 566 525. E-mail: feriha1106@gmail.com

ABSTRACT

Introduction: Unilateral spastic cerebral palsy (US CP) is the second most common subtype of cerebral palsy. **Aim:** The aim of the study was to analyze neuroimaging findings in children with unilateral spastic cerebral palsy. **Material and methods:** The study was hospital based, which has included 106 patients with US CP (boys 72/girls 34, term 82/preterm 24). Neuroimaging findings were classified into 5 groups: Brain maldevelopment, predominant white matter injury, predominant gray matter injury, non specific findings and normal neuroimaging findings. **Results:** Predominant white matter lesions were the most frequent (48/106,45.28%; term 35/preterm 13), without statistically significant difference between term and preterm born children ($\chi^2=0.4357$; $p=0.490517$). Predominant gray matter lesions had 32/106 children, 30.19%; (term 25/preterm 7, without statistically significant difference between term and preterm born children ($\chi^2=0.902$; $p=0.9862$). Brain malformations had 10/106 children, 9.43%, and all of them were term born. Other finding had 2/106 children, 1.89%, both of them were term born. Normal neuroimaging findings were present in 14/106 patients (13.21%). **Conclusion:** Neuroimaging may help to understand morphological background of motor impairment in children with US CP. Periventricular white matter lesions were the most frequent, then gray matter lesions.

Keywords: Unilateral spastic cerebral palsy, brain lesions, child.

1. INTRODUCTION

Cerebral palsy (CP) is the most common cause of motor disability in children, with incidence of 2-2.5 per 1000 live birth (1). Cerebral palsy is a group of permanent disorders of the development of movement and posture, causing activity limitation, that are attributed to non-progressive disturbance that occurred in the developing fetal and infant brain. The motor disorders of cerebral palsy are often accompanied by disturbance of sensation, perception, cognition, communication, behavior, epilepsy and by secondary musculoskeletal problems (2). The Surveillance of Cerebral Palsy in Europe Study Group (SCPE) has proposed three CP type groups: spastic, dyskinetic and ataxic CP. The subtypes of spastic cerebral palsy are unilateral spastic CP (instead of previous term hemiplegia) and bilateral spastic CP (instead of

previous terms diplegia and quadriplegia)(3).

Unilateral spastic cerebral palsy (US CP) is the unilateral motor impairment, congenital or early acquired, isolated or associated with additional impairments. It is the second most common CP subtype, that is reported in around 25% of children with CP (4). Neuroimaging, especially magnetic resonance imaging (MRI) is very useful diagnostic procedure that is commonly used in clinical evaluation of children with CP (5, 6). The brain MRI may help to identify the type and timing of lesions that cause CP and may help to provide early prognosis of motor outcome, but also occurrence and severity of associated disabilities.

2. AIM

The aim of the study was to investigate neuroimaging findings in chil-

dren with unilateral spastic cerebral palsy and compare them between term and preterm (gestation age<37wks) born children.

3. MATERIAL AND METHODS

The study was hospital based, which has included 106 patients with US CP (82 term /24 preterm). Patients with US CP have been followed up at Pediatric Hospital, Clinical Center of University Sarajevo, Bosnia and Herzegovina in outpatient and inpatient settings, during the study period of 20 years (1996-2015). The study has included patients who were born between 1988 and 2013. The inclusion criteria have been: confirmed diagnosis of UC CP by child neurologist at minimal age of three years.

Neuroimaging studies have included computed tomography (CT) and MRI with T1 and T2-weighted images and fluid-attenuated inversion recovery (FLAIR). Neuroimaging studies have been done by 1.5 or 3.0 Tesla machines. They have been interpreted by neuroradiologist.

When both CT and MRI findings were available, the MRI results were preferred.

Neuroimaging findings were classified into 5 groups: a) Maldevelopment; b) Predominant white matter injury; c) Predominant gray matter injury; d) Non specific findings; and e) Normal findings (Table 1).

Type of neuroimaging findings	Description
Brain maldevelopments	Cortical dysplasia, polymicrogyria, pachygyria, heterotopias, schizencephaly, corpus callosum agenesis, hydrocephalus
Periventricular white matter lesions	Signal abnormalities or volume loss in the periventricular white matter
Cortical or deep gray matter lesions	Signal abnormality or volume loss in cortical/subcortical or deep gray matter structures
Non specific finding	Unclassified changes on imaging (delayed myelination, widened Virchow-Robin spaces)
Normal MRI findings	No abnormalities detected

Table 1. Classification of neuroimaging findings

Non specific findings group included abnormal MRI patterns, which did not meet criteria mentioned above.

4. RESULTS

During the study period 106 patients with US CP has been followed up. Among the participants there were 72/106 (67.9%) males and 34/106 (32.1%) females, 82/106 (77.36%) term born and 24/106 (22.64%) preterm born.

Neuroimaging studies have been performed in 105/106 cases (99.05%) of the total cohort. In one case (1/106, 0.94%), parents refused neuroimaging study to be done for their child.

Only brain CT has been done in 18/106 (17%) cases, only brain MRI has been done in 27/106 (27%) cases, while 60/106 (60%) patients had both CT and MRI neuroimaging studies (Table 2).

Neuroimaging studies have been abnormal in 92/106 patients (85.85%). The normal neuroimaging finding were present in 14 out of 106 cases (13.21 %), among

Modality	number of patients	%
CT only	18	17%
MRI only	27	25%
CT + MRI	60	57%
None	1	1%
Total	106	100%

Table 2. Distribution of neuroimaging modalities

Neuroimaging finding	number of patients
ACC	2
ACC+schizencephaly	1
Pachygyria	3
Pachygyria+ AC type I malformation	1
HMEG	1
Schizencephaly+SOD+heterotopia+PMG	1
FCD	1
Total	10

Table 3. Brain maldevelopment neuroimaging findings. ACC=agenesis of corpus callosum, AC type I = Arnold-Chiari type I, HMEG=hemimegalencephaly, PMG=polymicrogyria, SOD=septo-optic dysplasia, FCD=focal cortical dysplasia

them 3/14 have done only CT, while 11/14 had normal brain MRI.

Predominant white matter lesions where the most frequent (48/106,45.28%), term 35/preterm 13, without statistically significant difference between term and preterm born children ($\chi^2=0.4357$; $p=0.490517$). Gray matter lesions had 32/106, 30.19% participants (term 25/preterm 7), without statistically significant difference between term and preterm born children ($\chi^2=0.902$; $p=0.9862$). There was only one case with deep gray matter lesions, all other cases where cortical-subcortical lesions. Brain malformations had 10/106 (9.43%) participants and all of them were term born. Other finding had 2/106 (18.9%) participants and both of them were term born (Figure 1).

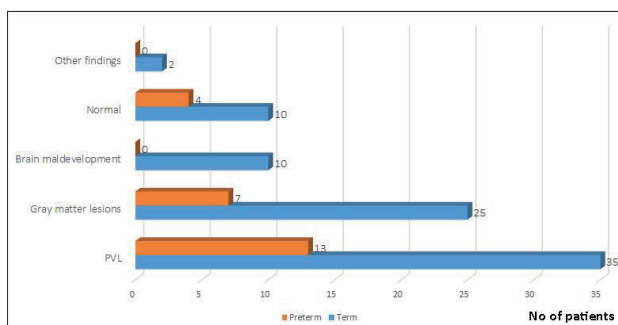


Figure 1. MRI findings in children with US CP

5. DISCUSSION

Different agents affecting the developing brain during the 1st and 2nd trimester of pregnancy may cause various maldevelopment (7). By the end of 2nd trimester the “gross architecture” of the brain is established. During the early 3rd trimester and in the preterm born infants periventricular white matter is especially vulnerable. If some agents, especially inflammation, affect developing brain during in this period, then the brain lesions may appear. By the end of 3rd trimester and in the term born infants gray matter is more vulnerable. Cortical and deep

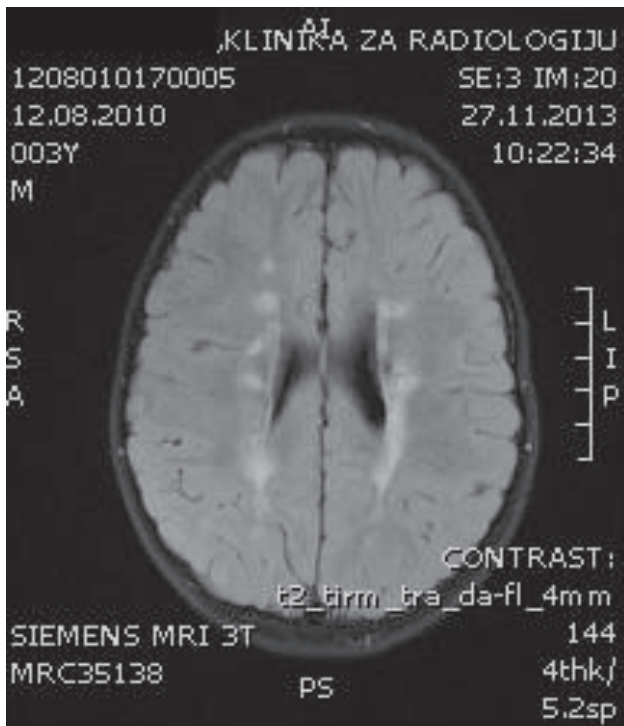


Figure 2. An axial T2 TIRM DARK FLUID MRI scan in a 6 year old boy with right sides US CP due to preterm birth and perinatal asphyxia: Periventricular white matter lesions

gray matter (basal ganglia and thalamus) may be affected (7).

In our study there were 72/106 (67.9%) males and 34/106 (32.1%) females. These results are similar to the results of D. Romeo et co-workers, where with 61% males and 39% females were reported. Sex differences in the immature brain injuries have been explained with greater biological vulnerability of male children. The incidence of cerebral palsy is significantly higher in males than females, due to different resistance to hypoxia and a higher incidence of preterm births in males. The female hormones possess neuroprotective effect. There is larger number of connections and better dendritic arborization in females than males, so the better post-lesional reorganization is possible. The neuroprotective role of estrogen and progesterone has been explained with their antioxidant effect and their membrane stabilizing effect (8).

Information on brain CT or MRI imaging were available in 105/106 cases (99.05%) of the total cohort. In the Quebec Cerebral Palsy Registry neuroimaging information was available for 88% of the total cohort of patients with cerebral palsy (9).

Abnormal brain MRI imaging was present in 92/106 patients (85.85%), which is similar to other studies. Ashwal et al. found brain abnormalities on MRI in 89% of 644 children with CP (9). In Krageloh-Mann study 52 out of 58 patients (90%) with US CP had abnormal MRI imaging (7).

Normal imaging results were found in 14 out of 106 cases (13.21%). 3/14 have done only CT, while 11/14 had normal brain MRI. These children may have cerebral lesions or abnormalities which are so subtle to be detected by neuroimaging modalities which have been used (6).

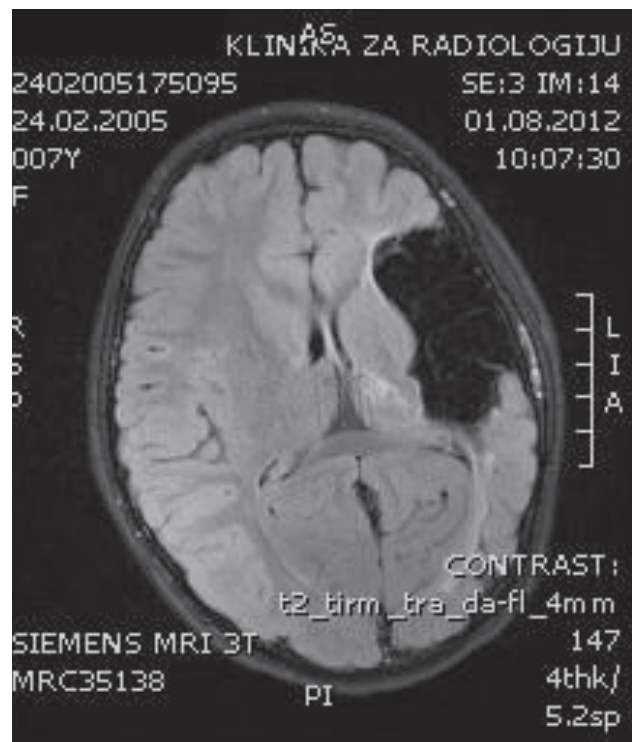

Figure 3. An axial T2 TIRM DARK FLUID MRI scan in a 11 year old girl with right sided UCP due to perinatal stroke: Cortical/subcortical lesion

CT scans are inferior to MRI scans for detecting periventricular white matter lesions (6).

Predominant white matter lesions were the most frequent (48/106, 45.28%), without statistically significant difference between term and preterm born children ($\chi^2=0.4357$; $p=0.490517$) (Figure 2). In Krageloh-Mann's study periventricular white matter lesions (PWM lesions) were present in 36% patients with US CP, but significantly more often in preterm US CP (7).

Predominant gray matter lesions have been visualized in 32/106 participants (30.19%), without statistically significant difference between term and preterm born children ($\chi^2=0.902$; $p=0.9862$). This result is almost identical to Krageloh-Mann, where gray matter lesions have been found in 31% US CP patients (7). But, in our study there were no statistically significant difference between preterm and term US CP patients, while other studies have confirmed that gray matter lesions appear significantly less often in preterm US CP patients (Figure 3).

White and gray matter lesions are the most prevalent type of injury detected by neuroimaging studies in children with US CP (10). They appear as regions of abnormal signal intensity and/or loss of tissue. Periventricular white matter lesions consist of focal and diffuse component. Focal lesions may cause direct motor fiber lesions, with motor impairment as consequence. Diffuse white matter lesions may cause more global dysfunction (11). Gray matter lesions are less common and they may be presented as diffuse or more selective cortical/subcortical lesions and basal ganglia or thalamic lesions. Those lesions may lead to more severe impairments of several functions, in particular motor function (10). Periventric-

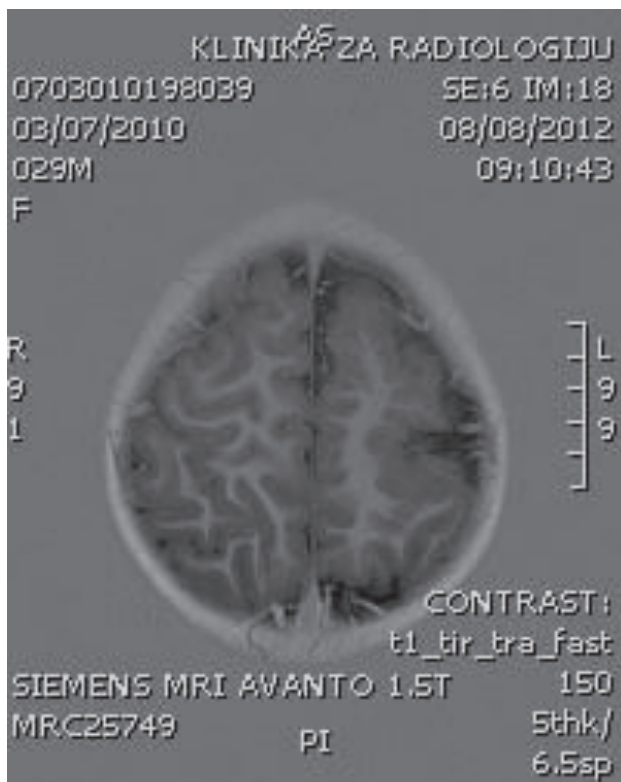


Figure 4. An axial T1 weighted inversion recovery MRI scan in a girl with right sided US CP due to brain maldevelopment (pachygyria and Arnold-Chiari type I malformation)

ular white matter lesions are associated with a milder motor impairment (5).

Brain malformations have been identified in 10/106 (9.43%) children and that is less in comparison to other studies, where brain malformations were present in 16% of US CP cases (7). There were no statistically significant difference between term and preterm born children with brain maldevelopment. The same result have been published by Krageloh-Mann (7).

Malformations of brain development could be single or multiple. The spectrum of brain malformations in our study was: Isolated corpus callosum agenesis (ACC) 2 cases; ACC+ schizencephaly 1 case; pachygyria 3 cases; pachygyria+Arnold-Chiari malformation type I (AC type I) 1 case; hemimegalencephaly (HMEG) 1 case; schizencephaly + septo-optic dysplasia (SOD) + heterotopia + polymicrogyria 1 case and focal cortical dysplasia 1 case (Table 3).

ACC could be isolated or combined with other central nervous system (CNS) or systemic malformations. Epilepsies are reported in up to two thirds of patients with complete or partial ACC. ACC is not indicative for seizure disorder, more often additional malformations of cortical development are causal. Microstructural CC abnormalities are detected by advanced imaging techniques and they constitute a part of diffuse white matter disturbance (12-14). In our study, there were 3 patients with ACC, two of them had epilepsy and all three of them were intellectually disabled. The first one had ACC associated with eye malformations (ipsilesional coloboma iridis and micro cornea) and epilepsy. The second

patient had ACC, schizencephaly and epilepsy. The third patient had ACC and esotropia.

Schizencephaly may be presented as unilateral or bilateral cleft, that is extending from the subarachnoid spaces to the ventricles. In our patient with ACC and schizencephaly, unilateral cleft was present (15).

Pachygyria, as a disorder of cortical development was present in 4 cases. Three of them had pachygyria only, while one patient had pachygyria, AC type I malformation and epilepsy. Three of them were intellectually disabled, one of them had epilepsy and autism (Figure 4).

Hemimegalencephaly was present in one case. It was type one of hemimegalencephaly, without hemispheric hypertrophy and cutaneous or systemic involvement (15). Due to intractable epilepsy, hemispherectomy has been done.

There were one case with multiple brain malformations: schizencephaly+SOD + heterotopia + polymicrogyria and another one with isolated focal cortical dysplasia. The diagnosis of SOD is defined by the presence of two, out of three characteristics (optic nerve hypoplasia, pituitary dysfunction and midline brain defects, such as absent septum pellucidum or agenesis of the corpus callosum). Our patient has no pituitary dysfunction. SOD generally occurs sporadically but environmental, epigenetic and genetic factors are implicated in its etiology (17, 18).

Heterotopia is migration disorder with abnormal location of neurons at any place between the subependymal region of the lateral ventricles and cerebral cortex, due to arrest of radial migration (15).

Polymicrogyria (PMG) is caused by an interruption in normal cerebral cortical development in the late neuronal migration or early postmigrational development periods. Cortical 'clefts' (schizencephaly) and cortical 'bumps' (polymicrogyria) are malformations which are frequently encountered together (15).

Focal cortical dysplasia (FCD) is a malformation of cortical development, which is the most common cause of medically refractory epilepsy in the pediatric population. Both genetic and acquired factors are involved in the pathogenesis of cortical dysplasia (15).

Malformations of cerebral cortical development include a wide range of developmental disorders that are common causes of neurodevelopmental delay and epilepsy. Many genes regulate cortical development and their mutation may cause malformation of cortical development (19-21).

The group of nonspecific neuroimaging findings included 2 cases: Hypomyelination and enlarged subarachnoid spaces.

6. CONCLUSIONS

Brain neuroimaging studies may help to identify the timing of brain lesion and also may help to predict the motor outcome in children with US CP. The neuroimaging studies are essential component of diagnostic algorithm for children with US CP.

• Conflict of interest: none declared.

REFERENCES

1. Rosenbaum P, Rosenbaum L. Cerebral Palsy: From Diagnosis to Adulthood. London: Mac Keith Press, 2012.
2. Rosenbaum P, Paneth N, Leviton A, Goldstein M, Bax M. Definition and classification document. *Dev Med Child Neurol*. 2007; 49(Suppl 2): 8-14.
3. Cans C. Surveillance of cerebral palsy in Europe: a collaboration of cerebral palsy surveys and registers. *Dev Med Child Neurol*. 2000; 42: 816-24.
4. Himmelmann K, Uvebrant P. The panorama of cerebral palsy in Sweden. XI. Changing patterns in the birth-year period 2003-2006. *Acta Paediatr*. 2014; 103(6): 618-24. doi: 10.1111/apa.
5. Himmelmann K, Horber V, De La Cruz J. et al. MRI classification system (MRICS) for children with cerebral palsy: development, reliability and recommendations. *Dev Med Child Neurol*. 2016. doi: 10.1111/dmcn.13166
6. Towsley K, Shevell M, Dagenais L. REPACQ Consortium. Population-based study of neuroimaging finding in children with cerebral palsy. *Eur J Paediatr Neurol*. 2011; 15(1): 29-35. doi: 10.1016/j.ejpn.2010.07.005
7. Krageloh Mann I, Horber V. The role of magnetic resonance imaging in elucidating the pathogenesis of cerebral palsy: a systemic review. *Dev Med Child Neurol*. 2007; 49: 144-51.
8. Romeo Dominico MM, Cioni M, Battaglia LR. Spectrum of gross motor and cognitive functions in children with cerebral palsy: Gender difference. *Eur J Paediatr Neurol*. 2011; 15(1): 53-8. doi: 10.1016/j.ejpn.2010.05.007
9. Ashwal S, Russman BS, Blasco PA. et al. Practice parameter: Diagnostic assessment of the child with cerebral palsy: report of the Quality Standards Subcommittee of the American Academy of Neurology and Practice Committee of the Child Neurology Society. *Neurology*. 2004; 62: 851-63.
10. Pagnozzi AM, Dowson N, Doecke J. et al. Automated, quantitative measure of grey and white matter lesion burden correlates with motor and cognitive function in children with unilateral cerebral palsy. *Neuroimage Clin*. 2016; 11: 751-9. doi: 10.1016/ni.
11. Scheck SM, Fripp J, Reid L et al. Extent of altered white matter in unilateral and bilateral periventricular white matter lesions in children with unilateral cerebral palsy. *Res Dev Disabil*. 2016; 55: 368-76. doi: 10.1016/j.ridd.
12. Balaji SM. Bilateral cleft lip and palate, hypertelorism with agenesis of corpus callosum. *Indian J of Dent Res*. 2016; 27: 100-102.
13. D'Antonio, Pagani G, Familiari A. et al. Outcomes Associated With Isolated Agenesis of the Corpus Callosum: A Meta-analysis. *Pediatrics*. 2016; 138(3). pii:e20160445. doi: 10.1542/peds.
14. Unterberger I, Bauer R, Waiser G, Bauer G. Corpus callosum and epilepsies. *Seizure*. 2016; 37: 55-60. doi: 10.1016/j.seizure.
15. Battal B, Ince S, Akgun V, Kocaoglu M, Oczan E, Tesar M. Malformation of cortical development: 3T magnetic resonance imaging features. *World J Radiol*. 2015; 7(10): 329-35. doi: 10.4329/wjr.v7.
16. Smith K, Gomez-Rubio AM, Harris TS, Brooks LE, Mosquera RA. Unusual Ventilatory Response to Exercise in Patient with Arnold-Chiari Type 1 Malformation after Posterior Fossa Decompression. *Case Rep Pediatr*. 2016: 8359838. doi: 10.1155/2016/8359838.
17. Garvin J, Sampath V, Karody VR. Gastroschisis Complicated by Septo-Optic Dysplasia: Two Distinct Anomalies with a Common Origin. *AJP Rep*. 2016; 6(1): e15-7. doi: 10.1055/s-0035-1563720.
18. Mc Cabe MJ, Hu Y, Gregory LC. et al. Novel application of luciferase assay for the in vitro functional assessment of KAL1 variants in three females with septo-optic dysplasia (SOD). *Mol Cell Endocrinol*. 2015; 417: 63-72. doi: 10.1016/j.mce.
19. Barkovich AJ, Guerrini R, Kuzniecky RI, Jackson GD, Dobyns WB. A developmental and genetic classification for malformations of cortical development: update 2012. *Brain*. 2012; 135(Pt 5): 1348-69. doi: 10.1093/brain/aws019.
20. Liu W, Xiao J, Li J, Hao N, Zhou D. Malformations of cortical development and epilepsy: A cohort of 150 patients in western China. *Seizure*. 2015; 32: 92-9. doi: 10.1016/j.seizure.
21. Biswas A, Furrugh F, Thimuzavukarasu S, Vivekandan R. Cortical Clefts and Bumps: A Continuous Spectrum. *J Clin Diagn Res*. 2016; 10(7): TD 01-2. doi: 10.7860/JCDR/2016/20343.8179.