

## CASE REPORT

# Feline hemotropic mycoplasmosis concurrent with bacterial cystitis in a domestic shorthair cat

Sukumaran Hemasri<sup>1</sup>, Ibrahim Abdul-Azeez Okene<sup>1</sup>, Mohammed Dauda Goni<sup>2</sup>

<sup>1</sup>Faculty of Veterinary Medicine, University Malaysia Kelantan, Kota Bharu, Malaysia

<sup>2</sup>Department of Medical Microbiology and Parasitology, School of Medical Sciences, Universiti Sains Malaysia Health Campus, Kubang Kerian, Malaysia

### ABSTRACT

**Objective:** The main aim of this case report is to present a case of feline hemotropic mycoplasmosis that occurred concurrently with bacterial cystitis following the bite.

**Material and methods:** A 3-year-old intact male domestic shorthair cat weighing 3.7 kg was referred to the Universiti Malaysia Kelantan Veterinary Clinic with clinical signs of hematuria and dysuria. History revealed that it was managed outdoor, fed with kibbles and wet food, but with no vaccination and deworming. Upon physical examination, the cat had a dull appearance, pale mucous membrane, normal respiratory rate, hypothermia, and bradycardia. Upon the examination of the urogenital system, there were urine burns at the anal region, necrotized penile tip, and presence of bite wound observed at the perineal region. Turgid and enlarged urinary bladder was identified upon palpation.

**Results:** Diagnostic investigation revealed the hemotropic mycoplasmosis via microscopy, while urine culture was positive for *Escherichia coli* infection. The cat was successfully treated symptomatically.

**Conclusion:** However, the prognosis of this cat was guarded given that the anemia was unresolved at the point of discharge.

### ARTICLE HISTORY

Received June 20, 2018

Revised: September 03, 2018

Accepted September 07, 2018

Published November 30, 2018

### KEYWORDS

Feline hemotropic mycoplasmosis;  
bacterial cystitis; cat



This is an Open Access article distributed under the terms of the Creative Commons Attribution 4.0 Licence (<http://creativecommons.org/licenses/by/4.0>)

## Introduction

Feline hemotropic mycoplasma is a frequently diagnosed infectious anemia in cats in Malaysia. It may occur concurrently with other diseases, such as feline panleukopenia, feline leukemia, and upper respiratory disease complex. Mycoplasmas are small free-living bacteria that lack a rigid and protective cell wall, it thrives in the environment [1]. Hemotropic mycoplasmas are small wall-less Gram-negative, non-acid-fast unculturable bacteria that survive on the surface of erythrocytes, previously classified as rickettsia under the genera Hemobartonella. However, the results from the sequencing of the 16S rRNA (ribosomal RNA) and ribonuclease (RNase) RNA genes informed the reclassification into the genus Mycoplasma [2]. It consists of two genera of classification which are Hemotropic with prefix “hemo” and the incompletely classified with prefix “candidatus” [3]. Hemotropic mycoplasma is pleomorphic,

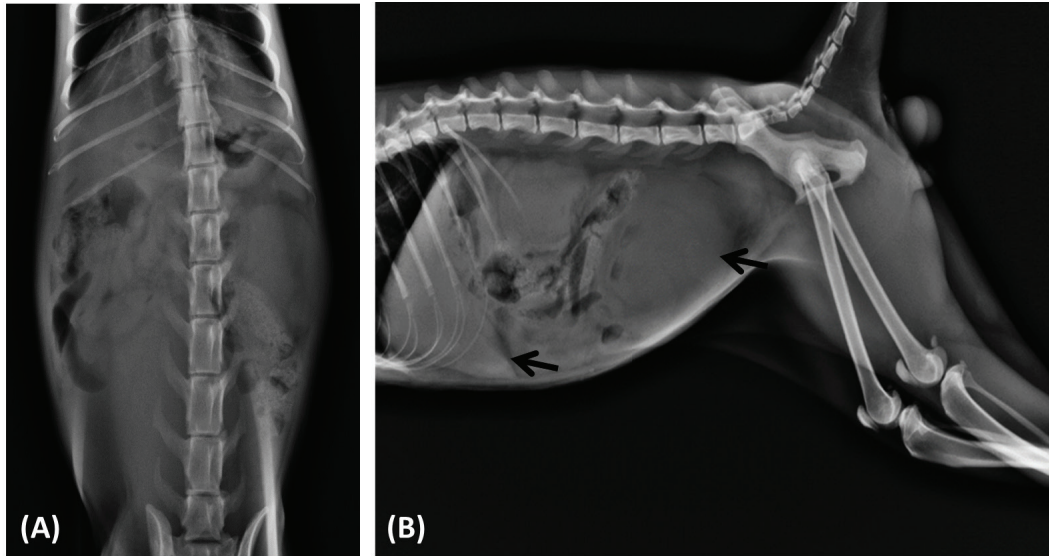
hence can be found in many shapes such as spherical (cocci), ring (signet), or rod. It is wall-less bacteria that attach and grow on the surface of the erythrocytes. It replicates by binary fission and can occur singularly or in chains. Hemotropic mycoplasma can affect all ages of cats [4].

There are three main routes of hemotropic mycoplasma transmission in cats; vertical transmission (dam to offspring), direct transmission from infected cats through saliva, gingiva, or claws by scratch or bite during the fight, and by arthropod vectors such as ear mites, fleas, ticks, and also by mosquitoes [5].

Bacterial cystitis is an inflammation of the urinary bladder as a result of bacterial infection. It is caused by a range of Gram-positive (such as *Staphylococcus aureus*) and Gram-negative bacteria (such as *Escherichia coli*). It is presented clinically with pollakiuria, hematuria, dysuria, and urinating in inappropriate places [6].

**Correspondence** Ibrahim Abdul-Azeez Okene ✉ [ibrahim.az@umk.edu.my](mailto:ibrahim.az@umk.edu.my) 📧 Faculty of Veterinary Medicine, University Malaysia Kelantan, Kota Bharu, Malaysia.

**How to cite:** Hemasri S, Okene IA-A, Goni MD. Feline hemotropic mycoplasmosis concurrent with bacterial cystitis in a domestic shorthair cat. J Adv Vet Anim Res 2018; 5(4):490–5.



**Figure 1.** Abdominal radiography, (A) ventrodorsal view and (B) right lateral view showing hepatomegaly in response to hemolysis (small white arrow) and distended urinary bladder (big white arrow) causing cranial displacement of abdominal content.

**Table 1.** Showing the serum biochemistry profile.

Biochemistry	Result	Reference
BUN	30 mg/dl	16–36
CREA	1.1 mg/dl	0.8–2.4
TP	6.7 gm/dl	5.7–8.9
ALB	3.8 gm/dl	2.2–4.0
GLB	2.9 gm/dl	2.5–4.5

BUN = blood urea nitrogen, CREA = creatinine, TP = total protein, ALB = albumin, GLB = globulin.

Therefore, the objective of this report is to demonstrate a case of feline hemotropic mycoplasmosis concurrent with bacterial cystitis in a domestic short-hair cat. There are currently few reports of the occurrence of both diseases in a single cat in routine veterinary clinical practice.

### Case History

A 3-year-old intact domestic short-hair Tomcat weighing 3.7 kg was referred to the Universiti Malaysia Kelantan Veterinary Clinic from a private veterinary clinic. It was referred due to persistent dysuria and hematuria; hence, the cat came with an indwelling urinary catheter.

### Diagnostic work-ups

#### Clinical examination

Upon the physical examination, the cat was dull, depressed, and pyretic. There was also normopnea, bradycardia, and marked pallor of the mucous membrane. Urogenital

system examination revealed necrotized penile tip, bite wounds, and urine burn at the perineum, as well as turgid and enlarged urinary bladder. Radiographic examination of the abdomen showed a remarkably enlarged urinary bladder spanning five lumbar vertebral bodies; thus, causing cranial displacement of abdominal organs and loss of radiographic detail as shown in Figure 1. Abdominal ultrasonography revealed a distended urinary bladder (5 cm × 5 cm) containing suspended echogenic materials and a thickened bladder wall.

#### Hematology and serum biochemistry

Complete blood count revealed granulocytosis, lymphopenia, monocytopenia, macrocytic hypochromic anemia, thrombocytopenia, and evidence of thrombopoiesis as shown in Table 1-2. Quick stained peripheral blood smear revealed eperythrocytic rod-shaped organisms highly suggestive of *Mycoplasma haemofelis* (Fig. 2). Blood sample was subjected to polymerase chain reaction to detect *M. haemofelis* genetic material and the result was positive.

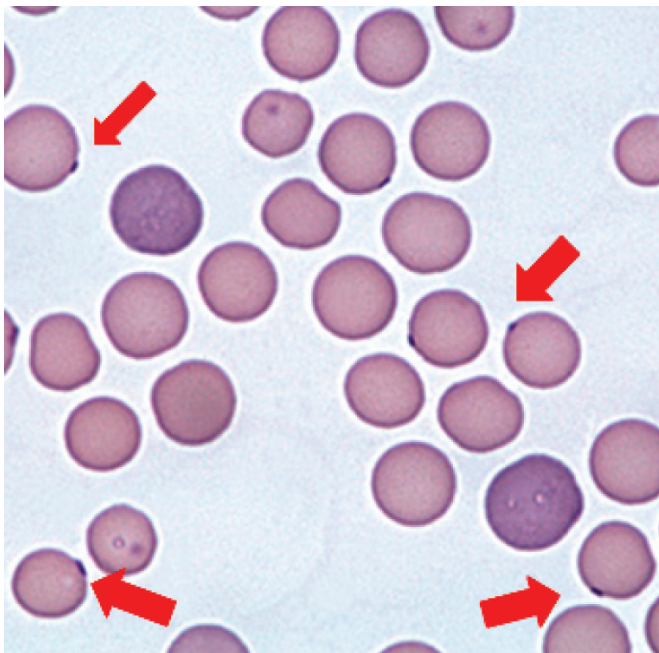
#### Urinalysis

Dark colored urine was observed upon cystocentesis (Fig. 3) with a pH of 7.0. Urine cytology showed the presence of cocci and bacillus shaped bacteria as well as neutrophils, however, there were no urine crystals observed. Proteinuria, bilirubinuria, and hematuria were also observed. Urine culture revealed *E. coli*. Based on the above investigations, the animal was diagnosed with feline

**Table 2.** Showing hematology profile for day1 and 6 of hospitalization.

Haemogram	Result		Reference
	Day 1	Day 6	
White blood cells ( $10^3/\mu\text{l}$ )	26.5	28.3	6.0–15.5
Granulocytes ( $10^3/\mu\text{l}$ )	20.3	17.5	2.0–8.0
Lymphocytes	5.5	8.6	5.7–8.9
Monocytes	0.6	2.2	2.2–4.0
Erythrocytes ( $10^6/\mu\text{l}$ )	4.54	4.38	6.50–10.00
Hemoglobin (gm/dl)	6.6	6.8	10.0–15.0
Hematocrit (%)	26.5	27.3	30.0–45.0
Mean corpuscular volume ( $\mu\text{m}^3$ )	58.4	56.1	39.0–55.0
Mean corpuscular hemoglobin (pg)	14.5	13.8	25.9–34.0
Mean corpuscular hemoglobin concentration (gm/dl)	24.9	26.4	30.0–35.9
Reticulocyte distribution width (%)	16.2	16.5	10–16.00
Thrombocytes ( $10^3/\mu\text{l}$ )	181	198	300–800
Thrombocrit (%)	0.066	0.145	0.200–0.500

Note the improvement in granulocytes, lymphocytes, monocytes, hemoglobin, hematocrit, mean corpuscular hemoglobin concentration, reticulocyte distribution width, and thrombocrit.




**Figure 2.** Peripheral blood smear showing the presence of rod-shaped peroxythryocytes.

hemotropic mycoplasmosis concurrent with bacterial cystitis.

### Diagnosis

Based on the history, physical examination, diagnostic imaging, clinical pathology, bacteriology, and polymerase chain reaction findings, the cat was diagnosed



**Figure 3.** Centrifuged urine showing red tinted supernatant (hemoglobinuria) with sediments.

with hemotropic mycoplasmosis concurrent with bacterial cystitis.

### Treatment

As shown in Table 3, treatment was initiated to achieve the goals of eliminating mycoplasma from the blood (using systemic antibiotics), restoring adequate tissue perfusion, and reversal of bacterial cystitis (with antibiotics). Urinary

**Table 3.** Medication given to the cat during hospitalization.

Drug	Dosage	Route	Frequency	Duration	Indication
Amoxicillin-clavulanic acid	25 mg/kg	PO	BID	5 days	Treat bacterial infection of the bladder
Metronidazole	10 mg/kg	IUT	BID	5 days	Treat bacterial infection of the bladder
Feline cystaid					
• Acetyl D-Glucosamine	1 tab	PO	BID	10 days	Urinary bladder wall protection
Meloxicam	0.3 mg/kg	PO	SID	4 days	To reduce the inflammation of the bladder
Hypermix gel		Topical	BID	5 days	Wound healing at the necrotized penile tip and also the bite wound
Livofeol					
• Ferrous gluconate	2 ml	PO	BID	12 days	As a liver supplement to resolve the anemic condition
• Ferrous chloride					
• Thiamine HCl					
• Riboflavin					
• Nicotinic acid					
• Nicotinamide					
• Calcium lactate					
• Liver fraction 2					
Vetri DMG					
• N,N Dimethylglycine	0.5 ml		PO	14 days	Boost immunity
• Bromelain					
Doxycycline	10 mg/kg	PO	SID	21 days	Treat <i>Mycoplasma haemofelis</i>

\*Doxycycline was given after confirming the cat had hemotropic mycoplasmosis. PO = Per Os (oral administration), BIS = twice daily, IUT = intraurinary tract, SID = once daily.

catheterization was done to relieve the urinary bladder distension and effectively conduct retrograde bladder flushing with metronidazole and cold normal saline for 5 days. Slow intravenous infusion of Hartmann's solution was given to rehydrate the cat and restore per-renal electrolyte loss. Hematology conducted on the 6th day of hospitalization showed a reduction in granulocytosis and reversal of lymphocytopenia and monocytopenia. Bladder wall radiography showed the reduced thickness. The overall prognosis was good.

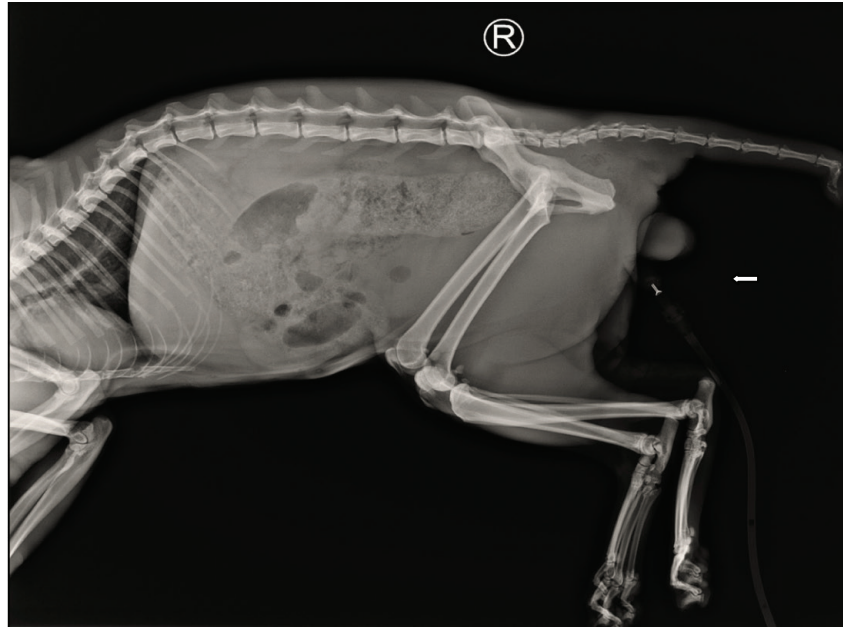## Discussion

Based on history, clinical signs diagnostic workup, and response to the treatment, the confirmatory diagnosis for this case was feline hemotropic mycoplasmosis concurrent with bacterial cystitis. Hemotropic mycoplasmosis was diagnosed from a combination of the history of fight and the presence of flea infestation [7,8] and more importantly clinical signs of anemia, lethargy, pyrexia, and icterus [9,10]. Being a disease characterized by immune-mediated hemolytic anemia, certain cases do present with icterus as well. Hepatomegaly was observed in this case indicating an active hepatic response to hemolysis (Fig. 1). Observation of eperythrocytic mycoplasma on thin blood smear conducted during diagnostic workup (Fig. 2) and the detection of mycoplasma genetic material via polymerase chain reaction was confirmatory for the diagnosis of hemotropic mycoplasmosis in this case [11].

Several antibiotic regimes are in use for clinical management for mycoplasmosis [12]. Doxycycline at a dose rate of 5

mg/kg b.wt twice daily *per os* for 28 days is a regime of choice for both acute and chronic mycoplasmosis. This was initiated immediately after the cat was confirmed to have hemotropic mycoplasmosis. However, cats that are non-responsive to doxycycline are usually placed on marbofloxacin at 2 mg/kg b.wt twice daily for 14 days [13]. Due to the immune-mediated nature of mycoplasmosis pathogenesis, prednisone administration was withheld despite its strategic importance in reducing the humoral immune response vital for the pathogenesis of extravascular hemolysis [7]. Furthermore, due to the lymphocytopenic state of this cat, prednisone was not administered in order not to further induce immunosuppression. The occurrence of bacterial cystitis also informed the decision to not administer the steroid but to rather replace with multiple supplements to aid the liver and bone marrow (Table 3) 6 days later, the parameters began to normalize, and lymphocytes number began to rise as well.

Outdoor managed cats are commonly involved in brawls which may involve cats infected with *Mycoplasma* spp. or infested with possible vectors [7]. This cat had a bite wound at the perineal region and also at the penile region; hence, transmission of both mycoplasmosis and bacterial cystitis is suspected to be through the bite at the inguinal area. Bacterial cystitis resulted from an ascending infection from the contaminated bite wound into the lower urinary tract. Bacterial cystitis was managed by retrograde flushing of the catheterized bladder with metronidazole at 10 mg/kg b.wt and cold normal saline for 5 days as well as *per os* administration of amoxicillin-clavulanic acid at 25 mg/kg b.wt twice daily for 5 days [14]. This regime



**Figure 4.** Post-treatment lateral view abdominal radiography showing normal-sized urinary bladder (arrow) and presence of constipation.

was to tackle the *E. coli* infection as there might be a risk of multi-drug resistant *E. coli* with a chance of recurrence if not managed with synergistic antibiotic therapy [15]. Post-treatment radiography revealed a good response by the reduction in wall thickness of the bladder (Fig. 4).

The immune suppression caused by the mycoplasma-induced immune-mediated hemolysis further enhancing the progression of bacterial cystitis. Pain induced stress from the bite wound and cystitis also result in anorexia and reduced immune response as well. A study has revealed that occurrence of concurrent disease along with feline mycoplasmosis is a negative prognostic indicator for cats [16]. However, in this case report, the prognosis looks good because the hematological parameters began to improve and most importantly, the lymphocytes rose to normal levels within a week.

Septicemia can occur due to ascending infection from this case; hence, the need to assiduously present such with antibiotic and supplemental cover. An unresolved anemia could progress to multiple complications associated with hypoxic tissue injury. Therefore, continuous monitoring of the hematology picture was done to proactively manage the condition and the prognosis was guarded.

## Conclusion

Feline hemotropic mycoplasmosis and bacterial cystitis were diagnosed in domestic short-hair cat based on history, clinical signs, hematology, bacterial culture and isolation, radiography, and molecular detection. Treatment was instituted using doxycycline (for mycoplasmosis), amoxicillin-clavulanic acid

(for bacterial cystitis), and supplements for supportive care, but the prognosis of this cat is guarded as hematology picture was still short of normal as at the time of discharge. Feline hemotropic mycoplasmosis, thus need to be investigated for the possibility of occurring concurrently with other diseases in order to correctly manage cats presented with it. Clinicians should also be on the lookout for multidrug-resistant *E. coli* as a possible complication of feline hemotropic mycoplasmosis associated with bite wounds.

## Conflict of Interest

There is no conflict of interest to declare.

## Authors' contribution

Sukumaran Hemasri and Ibrahim Abdul-Azeez Okene conceived and drafted the manuscript, Mohammed Dauda Goni reviewed the manuscript.

## References

- [1] Waites KB, Xiao L, Liu Y, Balish MF, Atkinson TP. *Mycoplasma pneumoniae* from the respiratory tract and beyond. *Clin Microbiol Rev* 2017; 30(3):747–809; <https://doi.org/10.1128/CMR.00114-16>
- [2] Sykes JE. Feline hemotropic mycoplasmas. *Vet Clin Small Anim Pract* 2010; 40(6):1157–70.
- [3] Roura X, Peters IR, Altet L, Tabar MD, Barker EN, Planellas M, et al. Prevalence of hemotropic mycoplasmas in healthy and unhealthy cats and dogs in Spain. *J Vet Diagn Investig* 2010; 22(2):270–4; <https://doi.org/10.1177/104063871002200219>
- [4] Hooshyar SH, Akhtardanesh B, Fard SRN, Khalili M. Hemotropic mycoplasmas in stray cats in Kerman, Iran. *J Med Bacteriol* 2017; 5(3–4):1–8.

- [5] Soto F, Walker R, Sepulveda M, Bittencourt P, Acosta-Jamett G, Müller A. Occurrence of canine hemotropic mycoplasmas in domestic dogs from urban and rural areas of the Valdivia Province, southern Chile. *Comp Immunol Microbiol Infect Dis* 2017; 50: 70–7; <https://doi.org/10.1016/j.cimid.2016.11.013>
- [6] Lew-Kojrys S, Mikulska-Skupien E, Snarska A, Krystkiewicz W. Evaluation of clinical signs and causes of lower urinary tract disease in Polish cats. *Vet Med* 2017; 62(7):386–93; <https://doi.org/10.17221/170/2016-VETMED>
- [7] Nibblett BMD, Snead EC, Waldner C, Taylor SM, Jackson ML, Knorr LM. Anemia in cats with hemotropic *mycoplasma* infection: Retrospective evaluation of 23 cases (1996–2005). *Canad Vet J* 2009; 50(11):1181.
- [8] Senthil N, Nagarajan K, Padmanath K, Subapriya S, Vairamuthu S, Tilagar MB, et al. A rare case study on feline mycoplasmosis. *Int J Adv Vet Sci Technol* 2014; 3(1):106–8.
- [9] Mazaheri NFR, Vahedi SM, Mohammadkhan F. Haemotropic mycoplasmas (haemoplasmas): a review. *Int J Adv Biol Biomed Res* 2014; 2(5):1484–503.
- [10] Willi B, Novacco M, Meli M, Wolf-Jackel G, Boretti F, Wengi N, et al. Haemotropic mycoplasmas of cats and dogs: transmission, diagnosis, prevalence and importance in Europe. *Schweiz Arch Tierheilkd* 2010; 152(5):237–44; <https://doi.org/10.1024/0036-7281/a000055>
- [11] Duarte A, Marques V, Correia JH, Neto I, Braz BS, Rodrigues C, et al. Molecular detection of haemotropic *Mycoplasma* species in urban and rural cats from Portugal. *J Feline Med Surg* 2015; 17(6): 516–22; <https://doi.org/10.1177/1098612X14550172>
- [12] Tasker S. Haemotropic mycoplasmas: what’s their real significance in cats? *J Feline Med Surg* 2010; 12(5):369–81; <https://doi.org/10.1016/j.jfms.2010.03.011>
- [13] Novacco M, Sugiarto S, Willi B, Baumann J, Spiri AM, Oestmann A, et al. Consecutive antibiotic treatment with doxycycline and marbofloxacin clears bacteremia in *Mycoplasma haemofelis*-infected cats. *Vet Microbiol* 2018; 217:112–20; <https://doi.org/10.1016/j.vetmic.2018.03.006>
- [14] Cray M, Berent AC, Weisse CW, Bagley D. Treatment of pyonephrosis with a subcutaneous ureteral bypass device in four cats. *J Am Vet Med Assoc* 2018; 252(6):744–53; <https://doi.org/10.2460/javma.252.6.744>
- [15] Lai CC, Chen CC, Huang HL, Chuang YC, Tang HJ. The role of doxycycline in the therapy of multidrug-resistant *E. coli* – an in vitro study. *Sci Rep* 2016; 6:31964; <https://doi.org/10.1038/srep31964>
- [16] Reynolds CA, Lappin MR. “*Candidatus Mycoplasma haemominutum*” infections in 21 client-owned cats. *J Am Anim Hosp Assoc* 2007; 43(5):249–57; <https://doi.org/10.5326/0430249>