

# A Case with a Fistula Draining into the Stomach due to Retained Surgical Gauze

R Niknam<sup>1\*</sup>, L Mahmoudi<sup>2</sup>, S Nasiri<sup>3</sup>, S Merat<sup>1</sup>

1. Digestive Diseases Research Center, Tehran University of Medical Sciences, Tehran, Iran
2. Department of Pharmacotherapy, Tehran University of Medical Sciences, Tehran, Iran
3. Department of Surgery, Tehran University of Medical Sciences, Tehran, Iran

## ABSTRACT

Retained surgical gauze is occasionally observed in general practice. Herein, we report a case with surgical gauze retained for over 13 years that created a fistula which drained pus into the stomach.

## KEYWORDS

Retained surgical gauze; Endoscopy; Fistula

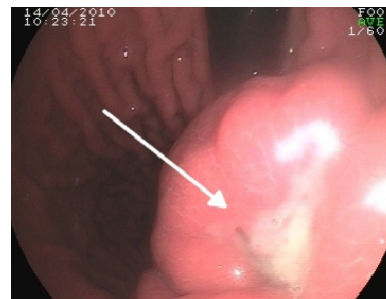## INTRODUCTION

Retained surgical gauze (RSG) is occasionally seen in cases that have a surgical medical history.<sup>1</sup> Here we present the case of a 28 year old man in which RSG presented as a fistula that drained pus into the stomach 13 years after surgery.

## CASE REPORT

A 28 year old male, known case of Wilson disease was referred for endoscopy to evaluate gastroesophageal varices. He had a history of splenectomy for hypersplenism 13 years earlier. His physical examination was unremarkable except for the previous surgical scar located over the abdominal skin. Hemoglobin was 9.5 mg/dL, ESR: 103 mm/hr and CRP: 16.3 mg/dl (normal range <10 mg/dl). Other parameters of blood chemistry were normal. Upper endoscopy was performed. A

fistula was discovered in the lesser curvature which was draining pus into the gastric lumen (Figure 1).



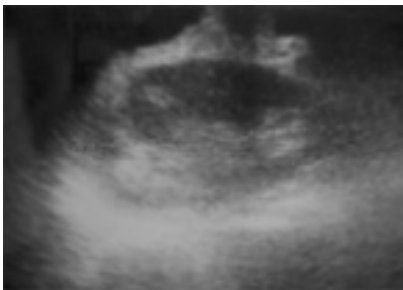
**Figure 1:** Orifice of the fistula with pus drainage into the lesser curvature. (arrow)

During his workup for the etiology of fistula, abdominal ultrasonography was performed which reported a 119×60 mm echogenic lesion at the site of the previous splenectomy (Figure 2).

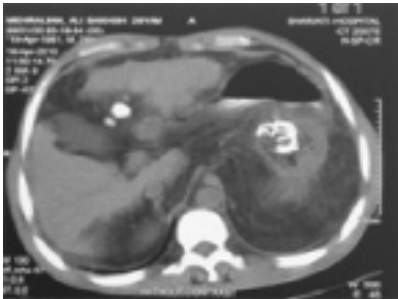The subsequent abdominal CT scan revealed an abnormal soft tissue lesion with opaque lines that indicated a foreign body at the left sub-diaphragmatic area. The collection was attached to the gastric wall and

\*Corresponding Author:  
R Niknam, MD,  
Digestive Diseases Research Center,  
Tehran University of Medical Sciences,  
Tehran, Iran.  
Tel: + 98 21 82415300  
Fax: + 98 21 82415400  
E-mail: niknam@ddrc.ac.ir  
Received: 15 June 2010  
Accepted: 28 July 2010

tail of pancreas, and extended to the lesser sac (Figure 3). Laparotomy was performed. After exploration of the lateral and posterior parts of fundus and lesser sac, an interaperitoneal foreign body (surgical gauze) was removed and the abscess was drained. The patient did well post-operatively and was discharged from the hospital after a course of antibiotic therapy.



**Figure 2:** Echogenic lesion as seen with abdominal ultrasonography.



**Figure 3:** Opaque foreign body at the area of a previous splenectomy as seen with abdominal CT.

## DISCUSSION

RSG is a relatively rare, but known phenomenon which occurs in cases that have undergone surgery.<sup>1</sup> In one study, retained surgical sponges have been found in 69% of patients with retained foreign bodies of which 37% required additional surgery.<sup>2</sup> The diagnosis of RSG, also known as gossypiboma, can be very difficult.<sup>1</sup> In one multivariate analysis it has been seen that surgery in emergency conditions, an unplanned change in the operation during surgery and high body mass index of the patient are the major risk factors for retained surgical foreign body.<sup>2</sup> Accurate diagnosis needs a consideration of the patient's previous sur-

gical history, close observation and physical examination. Pertinent medical imaging techniques such as ultrasonography and computed tomography are essential ancillary studies for accurate diagnosis.<sup>1</sup> Although RSG can remain asymptomatic for a long period of time,<sup>1</sup> however it eventually presents with a constellation of problems that include pain,<sup>1,3</sup> fistula formation,<sup>4</sup> mass effect<sup>3</sup> and intra-abdominal abscess formation.<sup>5</sup> Transmural migration of the foreign body has also been reported.<sup>6</sup>

In conclusion, any abdominal or constitutional symptoms along with a past history of abdominal surgery should trigger the suspicion for presence of retained surgical foreign body. Imaging and other ancillary studies are needed for establishment of the diagnosis. Fistulization of the abscess formed around the foreign body is a rare, but well known complication in this condition. We report an interesting case of RSG diagnosed after detection of a fistula that drained pus into the gastric lumen. Meticulous sponge and instrument count protocols in operation theaters should be followed to reduce the possibility of retained surgical foreign body.

## CONFLICT OF INTEREST

The author declare no conflict of interest related to this work.

## REFERENCES

1. Cevik I, Dillioglugil O, Ozveri H, Akdas A. Asymptomatic retained surgical gauze towel diagnosed 32 years after nephrectomy. *Int Urol Nephrol* 2008;**40**:885-8.
2. Pisal N, Sindos M, Henson G. Risk factors for retained instruments and sponges after surgery. *N Engl J Med* 2003;**348**:1724-5.
3. Saidi H, Mohammed U, Machoki M. An unusual abdominal mass: case report. *East Afr Med J* 2007;**84**:88-92.
4. Yaycioglu O, Ulasan S, Ezer A, Guvel S. Ureteroappendiceal fistula due to gossypiboma. *Urol Int* 2007;**79**:187-8.
5. Wang YY, Chang CC. Intraabdominal abscess with gauze. *J Minim Invasive Gynecol* 2006;**13**:1.
6. Zantvoord Y, van der Weiden RM, van Hooff MH. Transmural migration of retained surgical sponges: a systematic review. *Obstet Gynecol Surv* 2008;**63**:465-71.