

Pseudo-conduction block at the mitral isthmus in a patient with epicardial impulse propagation through the vein of Marshall



Rintaro Hojo, MD,^{*} Seiji Fukamizu, MD,^{*} Takeshi Kitamura, MD,^{*} Kenichi Maeno, MD,^{*} Masayasu Hiraoka, MD, PhD, FAHA, FHRS, FESC,[†] Harumizu Sakurada, MD, PhD[‡]

From the ^{*}Department of Cardiology, Tokyo Metropolitan Hiroo Hospital, Tokyo, Japan, [†]Department of Health Examination, Toride Kitasohma Medical Center Hospital, Ibaraki, Japan, and [‡]Ohkubo Hospital, Tokyo Metropolitan Health and Medical Treatment Corporation, Tokyo, Japan.

Introduction

The vein of Marshall (VOM) has multiple connections with the left atrium (LA) and the coronary sinus (CS), making it a potential substrate for a reentry circuit.¹ Recent studies using direct recording of the electrogram have confirmed that the VOM can play a real role in the reentry circuit.^{2,3} We present a case in which the VOM spanned a conduction gap at the mitral isthmus (MI) scar, making it difficult to confirm a bidirectional block at the MI using electrodes in the CS.

Case report

A 78-year-old woman had undergone catheter ablation twice for the treatment of persistent atrial fibrillation. The first procedure involved only pulmonary vein isolation (PVI), while the second included right superior and inferior pulmonary vein re-isolation, ablation of complex fractionated electrograms in the left and right atria, and linear ablation in the roof of the LA and the MI. Although the conduction time across the MI was prolonged to 165 ms, bidirectional conduction block across the MI was not achieved.

Six months after the second procedure, the patient felt palpitations caused by atrial tachycardia (AT). A 12-lead surface electrocardiogram (ECG) during AT with a cycle length of 280 ms showed positive P waves in leads II, III, aVF, and V₁ (Figure 1A). An electrophysiologic study was

performed after the patient had provided informed consent.

The activation map constructed during AT, using an electro-anatomic mapping system (Ensite NavX; St. Jude Medical, Minneapolis, MN), revealed counterclockwise impulse propagation around the mitral annulus and left atrial appendage (LAA) and the scar band at the MI, which corresponded to the trajectory of the initial MI line (Figure 1B). Entrainment mapping indicated that the post-pacing interval (PPI) in the inferior and lateral mitral annulus and the LAA–left pulmonary vein (LPV) ridge was <20 ms longer than the tachycardia cycle length (TCL). However, the PPI around the scar in the MI was >20 ms longer than the TCL (Figure 1B). These results suggested the presence of epicardial conduction through the CS or the VOM, bypassing the scar tissue of the MI. Because the impulse of the AT propagated from the LAA-LPV ridge, which was the connection site between the LA and the VOM, to the endocardium adjacent to the distal CS, we suspected the epicardial conduction through the VOM (Figure 1B). We cannulated the VOM with a 2F octapolar electrode catheter (EP star Fix 2Fr; Japan Lifeline, Tokyo, Japan) through an 8.5F deflectable sheath (Agilis; St. Jude Medical). The records of electrical activity demonstrated that the VOM did play a role in the impulse propagation of the AT (Figure 1C), and the PPIs at multiple sites along the VOM were found to be equal to the TCL (Figure 1D). Fractionated potentials with a duration of 115 ms were recorded by the electrode at the LAA-LPV ridge, in which the initial component extended from the time of the main spike at the distal electrode of the VOM (Figure 2A). Radiofrequency application at the LAA-LPV ridge (Figure 2C and D, Figure 3A, site A) with a 7F irrigated tip ablation catheter (Coolflex; St. Jude Medical) terminated the AT 40 s after the beginning of the ablation (Figure 2B).

After the termination of the AT, the activation sequences in the CS and VOM were found to be propagating in the distal–proximal direction during LAA pacing (Figure 3C).

KEYWORDS Vein of Marshall; Atrial tachycardia; Ridge-related reentry; Differential pacing

ABBREVIATIONS AT = atrial tachycardia; CS = coronary sinus; ECG = electrocardiogram; LA = left atrium; LAA = left atrial appendage; LPV = left pulmonary vein; MI = mitral isthmus; PPI = post-pacing interval; PVI = pulmonary vein isolation; TCL = tachycardia cycle length; VOM = vein of Marshall (Heart Rhythm Case Reports 2015;1:232–237)

Dr Hiraoka has received a consultation fee from DVX, Inc. **Address reprint requests and correspondence:** Dr Rintaro Hojo, Department of Cardiology, Tokyo Metropolitan Hiroo Hospital, 2-34-10, Ebisu, Shibuya-ku, Tokyo 150-0013, Japan. E-mail address: rintaroh1979@hotmail.co.jp.

KEY TEACHING POINTS

- The atrial tachycardia (AT) propagates around the mitral annulus and left atrial appendage (LAA) with slow conduction along the LAA–left pulmonary vein (LPV) ridge and wide-split double potentials in the ventricular aspect of the mitral isthmus (MI), which was reported as a ridge-related reentry.
- The records of electrical activity and post-pacing interval mapping in the vein of Marshall (VOM) indicated that the AT bypassed the scar of the MI using the VOM.
- Catheter ablation at the connection between the VOM and the LAA-LPV ridge was effective to achieve the bidirectional block across the MI.
- The electrode data in the coronary sinus clarified the pseudo-conduction block during catheter ablation at the connection between the VOM and the LAA-LPV ridge.

In contrast, pacing at CS 3–4 and CS 5–6 showed counter-clockwise MI conduction block (Figure 3A), indicating unidirectional conduction block at the MI. Catheter ablation at several sites in the MI area, aiming to achieve bidirectional conduction block (Figure 3B, red spheres), failed to change the propagation sequences along the CS and VOM. The ablation site was then shifted to the LAA-LPV ridge (Figure 3B, site B). During the energy application, the activation sequence in the proximal CS first changed from proximal to distal, but without a change in the sequence in the VOM (Figure 3D). Further ablation also changed the propagation direction from proximal to distal in the VOM (Figure 3E). These results implied that a pseudo-conduction block at the MI had been masked by the presence of epicardial bypass conduction via the VOM. Pacing at the CS confirmed complete block at the MI. We then performed differential pacing at the VOM and demonstrated the conduction block between the VOM and the LAA-LPV ridge.

The patient was free from atrial tachyarrhythmias 11 months after the completion of this procedure.

Discussion

Takatsuki and colleagues⁴ described AT developing after PVI and ablation at the lateral MI as a ridge-related reentry. The diagnosis was based on (1) macro-reentrant AT involving the septum and the inferior and anterior walls of the LA, indicated by local PPI measurements; (2) slow conduction along the LAA-LPV ridge; and (3) wide-split double

potentials in the ventricular aspect of the lateral mitral isthmus, identified by the CS electrode across the previous linear lesion.⁴ The AT in our case resembled the AT in that report, in which atrial activation propagated clockwise around the mitral annulus and LAA, except for the conduction via the VOM across the previous linear lesion at the MI.

After termination of AT by ablation at the LAA-LPV ridge (Figure 3B, site A), unidirectional conduction across the MI was still present (Figure 3C). Several applications of catheter ablation in the wider area around the MI region were not effective in achieving bidirectional block (Figure 3B, red spheres), but conduction block at the MI and LA-VOM connection was achieved by applying ablation in several steps at the LAA-LPV ridge (Figure 3B, site B). To elucidate why transmitral block was achieved after radiofrequency energy application at a site distant from the MI, we carefully assessed the intracardiac electrogram. In the early phase of the LAA-LPV ridge ablation, the conduction time between the LAA and VOM increased from 90 ms to 105 ms, with a simultaneous change in the activation sequence in the proximal CS. The polarity of local potentials at CS 5–6 and CS 7–8 was inverted, but the polarity at CS 3–4, distal to the connection between the CS and the VOM, was not reversed (Figure 3C and D), indicating that the activation at CS 3–4 was not influenced by the early phase of ablation. It is possible that the conduction block at the endocardial side of the MI had already been completed by the ablation in the MI region, and that the conduction delay at the LA-VOM connection resulting from the ablation at the LAA-LPV ridge caused the direction of propagation in the proximal CS, while the conduction to the VOM and CS 3–4 was unaffected. Therefore, bidirectional conduction block across the MI ablation line was achieved because of the epicardial conduction via the VOM. The CS electrode data clarified the presence of a pseudo-block at the MI (Figure 3D). If the activation sequence of the VOM had not been available, we might have overestimated the conduction block at the MI. Further application of catheter ablation at the LAA-LPV ridge changed the activation sequence at the VOM from proximal to distal, while causing an inversion of the polarity of local potentials at VOM 3–4 and VOM 5–6 (Figure 3E).

Shah and colleagues⁵ described 6 types of pitfall in the assessment of transmitral conduction block, using a differential CS and LAA pacing technique in 236 patients undergoing left MI linear ablation. In particular, they mentioned a type with an epicardial conduction gap and endocardial conduction block; that is similar to our case, with the exception of the epicardial conduction through the CS. Therefore, we suggest that our case represents another type of pitfall and that the possibility of epicardial bypass through the VOM should be considered in the assessment of transmitral conduction.

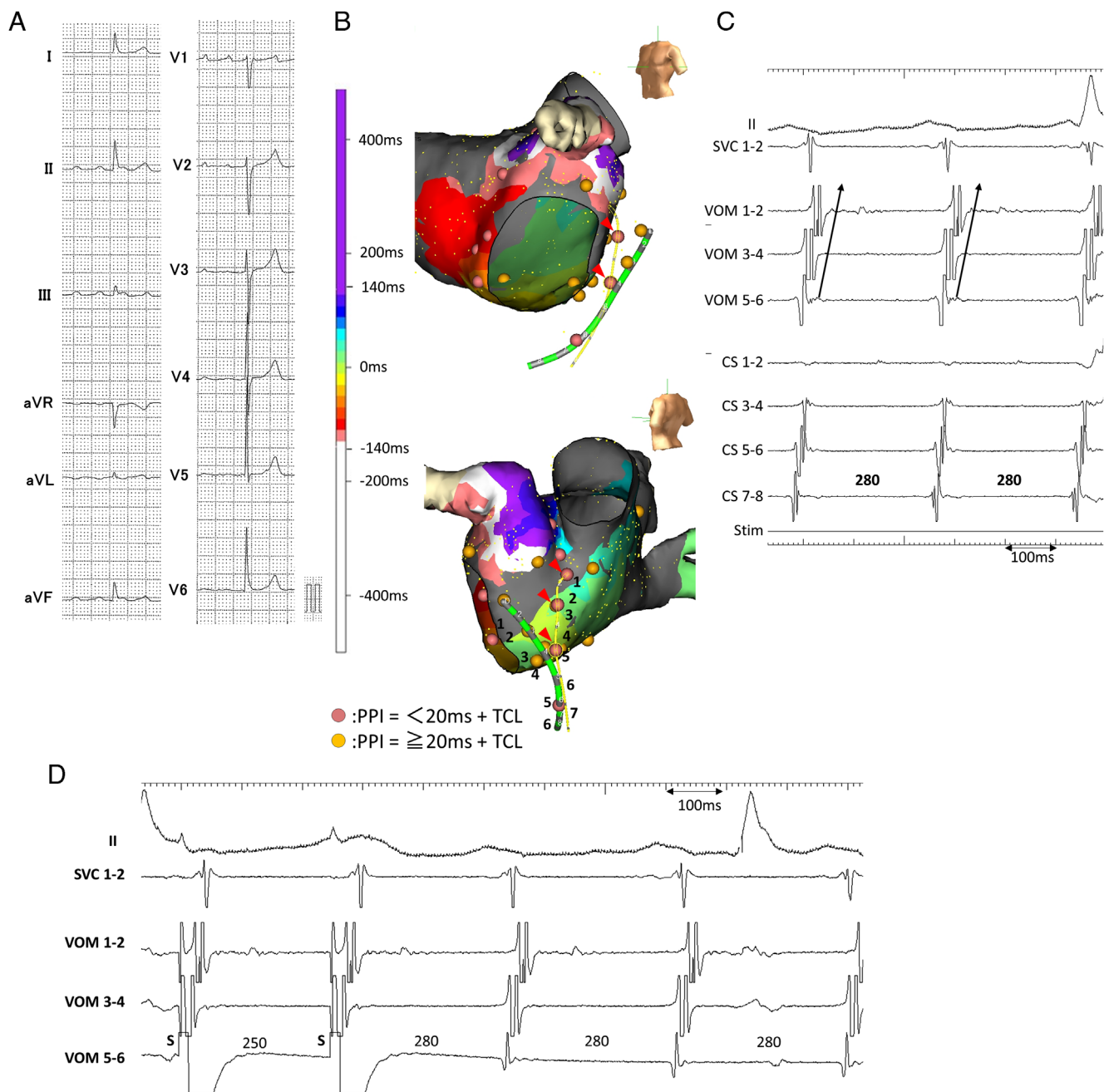


Figure 1 **A:** The 12-lead surface electrocardiogram during atrial tachycardia (AT). Note that P waves are positive in leads II, III, aVF, and V₁. **B:** The activation sequence of the left atrium during AT. Values of post-pacing interval (PPI) + tachycardia cycle length (TCL) measured at different sites are shown by circles (yellow: PPI ≥ 20 ms + TCL, orange: PPI < 20 ms + TCL). We performed entrainment pacing at multiple sites along the vein of Marshall (VOM) (red arrowhead). **C:** Intracardiac electrogram during AT. **D:** Intracardiac electrogram during entrainment pacing at VOM 5–6. PPI was identical to TCL (280 ms). SVC = superior vena cava; CS = coronary sinus.

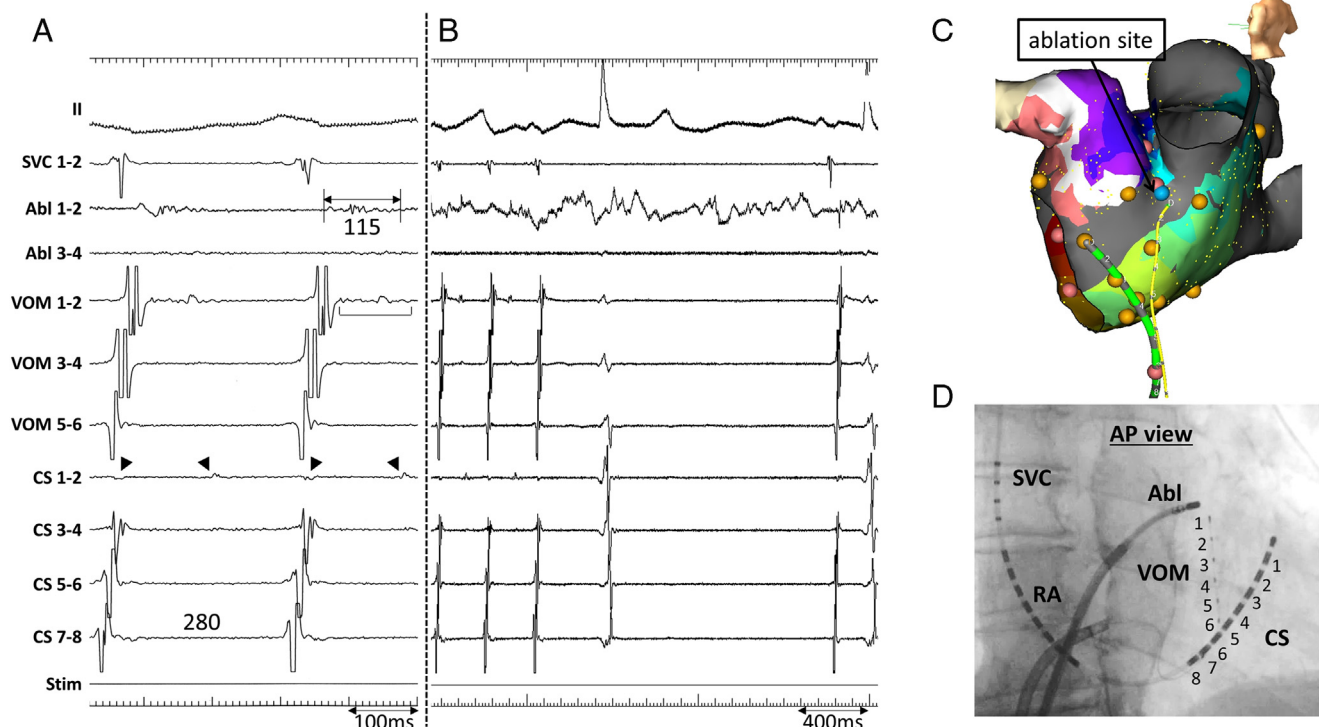


Figure 2 **A:** Intracardiac electrogram during atrial tachycardia. Fractionated potentials with a duration of 115 ms were recorded at ablation catheter (Abl) 1–2, located at the left atrial appendage–left pulmonary vein ridge. At coronary sinus (CS) sites 1–2 split potentials were present (*black arrowheads*). **B:** After 40 s radiofrequency (RF) application, the atrial tachycardia was terminated. **C:** The geometry of the left atrium with the location of the ablation site (RF site). The RF site was close to the distal electrode in the vein of Marshall (VOM). **D:** Fluoroscopic view of the catheter position. SVC = superior vena cava; RA = right atrium.

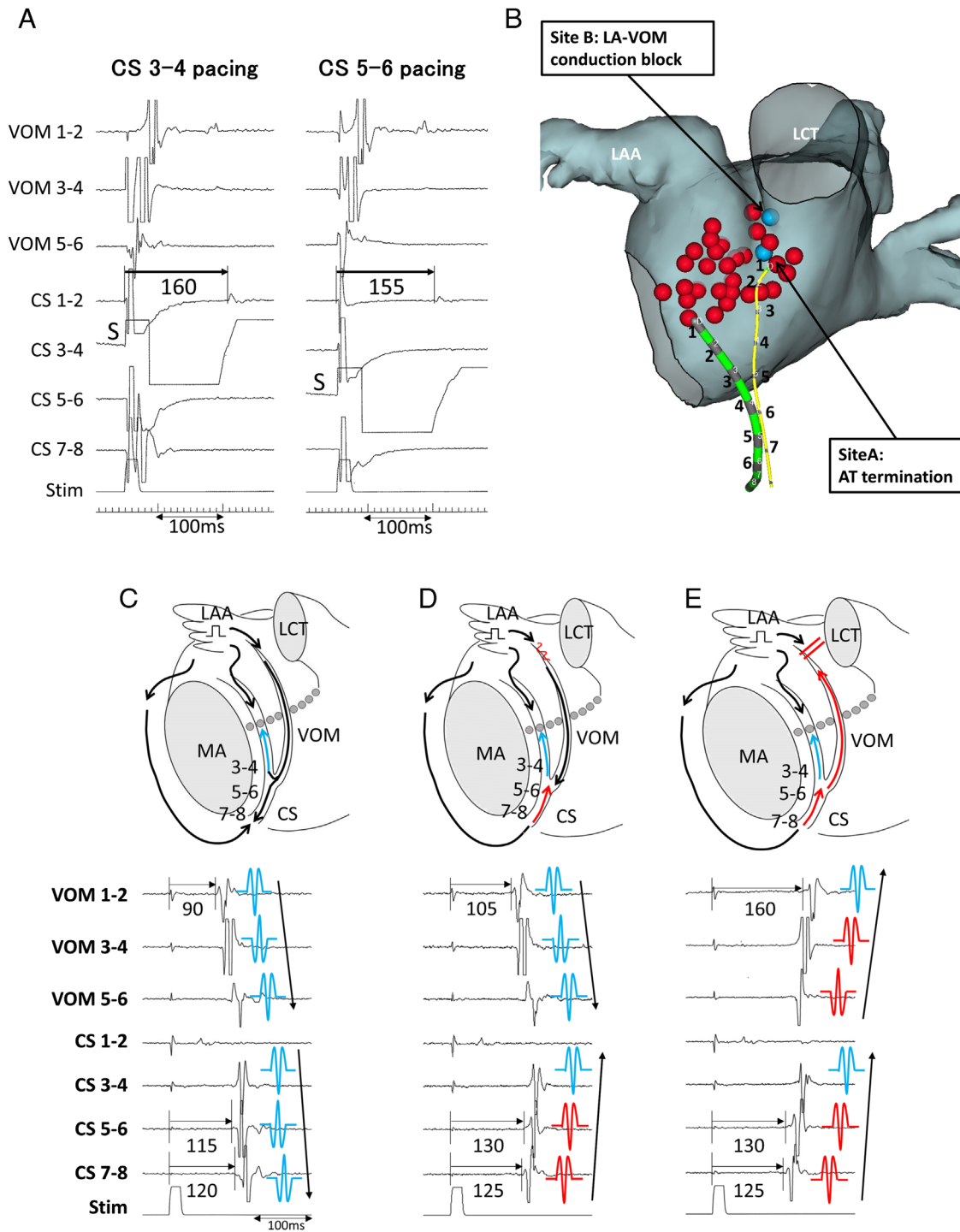


Figure 3 **A:** The intracardiac electrogram during differential site pacing in the coronary sinus (CS) 3-4 (left panel) and CS 5-6 (right panel). The conduction time from CS 3-4 to CS 1-2 was longer than that from CS 5-6 to CS 1-2, which indicated the counterclockwise mitral isthmus (MI) conduction block. **B:** The geometry and ablation sites of the MI. Red and blue spheres indicate unsuccessful and successful ablation sites, respectively. Atrial tachycardia (AT) was terminated by ablation at site A, and conduction block between the left atrium (LA) and the vein of Marshall (VOM) was achieved at site B. **C:** Diagram of the activation sequence and the intracardiac electrogram during the left atrial appendage (LAA) pacing before radiofrequency (RF) application. **D:** Diagram of the activation sequence and the intracardiac electrogram during the LAA pacing at 37 s of the RF application. The conduction time between the LAA and VOM increased from 90 ms to 105 ms, with a simultaneous change in the activation sequence in the proximal CS. The polarity of local potentials at CS 5-6 and CS 7-8 was inverted, but the polarity at CS 3-4, distal to the connection between the CS and the VOM, was not reversed. If the activation sequence of the VOM had not been available, we might have overestimated the conduction block at the MI. **E:** A scheme of the activation sequence and the intracardiac electrogram during the LAA pacing at 77 s of the RF application. The propagation direction in the VOM changed from proximal to distal in the VOM. LCT = left common tract; MA = mitral annulus.

References

1. Han S, Joung B, Scanavacca M, Sosa E, Chen PS, Hwang C. Electrophysiological characteristics of the Marshall bundle in humans. *Heart Rhythm* 2010;7:786–793.
2. Báez-Escudero JL, Morales PF, Dave AS, Sasaridis CM, Kim YH, Okishige K, Valderrábano M. Ethanol infusion in the vein of Marshall facilitates mitral isthmus ablation. *Heart Rhythm* 2012;9:1207–1215.
3. Yamamoto T, Maruyama M, Seino Y, Shimizu W. Marshall bundle reentry: a novel type of macroreentrant atrial tachycardia. *Heart Rhythm* 2014;11:1229–1232.
4. Takatsuki S, Fukumoto K, Igawa O, Kimura T, Nishiyama N, Aizawa Y, Tanimoto Y, Tanimoto K, Miyoshi S, Fukuda K. Ridge-related reentry: a variant of perimitral atrial tachycardia. *J Cardiovasc Electrophysiol* 2013;24:781–787.
5. Shah AJ, Pascale P, Miyazaki S, et al. Prevalence and types of pitfall in the assessment of mitral isthmus linear conduction block. *Circ Arrhythm Electrophysiol* 2012;5:957–967.