



Case Report

Limited Utility of Serology and Heterophile Test in the Early Diagnosis of Epstein–Barr Virus Mononucleosis in a Child after Renal Transplantation

Alexandra Byrne ¹, Rachel Bush ², Felicia Johns ² and Kiran Upadhyay ^{2,*} 

¹ Department of Pediatrics, University of Florida, Gainesville, FL 32610, USA

² Division of Pediatric Nephrology, Department of Pediatrics, University of Florida, Gainesville, FL 32610, USA

* Correspondence: kupadhyay@ufl.edu; Tel.: +352-273-9180

Received: 2 April 2020; Accepted: 20 April 2020; Published: 22 April 2020



Abstract: Background: Epstein–Barr virus (EBV) infection is associated with significant morbidity and mortality in renal transplant (RT) recipients. The spectrum of illness ranges from infectious mononucleosis (IM) to post-transplant lymphoproliferative disorder (PTLD). In association with clinical signs and symptoms, virus-specific serology and heterophile antibody tests are widely used in confirming the diagnosis of IM in the general population. However, these tests may have a limited role in immunosuppressed RT recipients from seropositive donor, especially in children who were EBV-seronegative prior to the transplant. The aim of this study is to evaluate the utility of these tests in the early diagnosis of IM in this subset of patients. **Methods:** This is a case study with a review of literature. **Results:** Here, we present a 14-year-old male with hemophilia B who presented with fever, fatigue, sore throat, palatal petechial rash, exudative tonsillitis and cervical lymphadenopathy 3 months post-RT. He was EBV seronegative prior to RT and received a deceased donor kidney transplant from a seropositive donor. Induction was done with Thymoglobulin and maintenance immunosuppression consisted of tacrolimus and mycophenolate. Initial heterophile antibody test (monospot) was negative, but became positive at 5 months and remained positive at 9 months follow-up post-RT. EBV viral capsid antigens (VCA) IgM and IgG, early antigen (EA) and nuclear antigen (EBNA) were all negative at the time of presentation. VCA IgM and IgG both became positive at 5 months and peaked at 9 months follow-up, however the EA and EBNA remained negative. EBV viral load as measured by polymerase chain reaction (PCR) was negative for the first 3 months post-RT but became positive at presentation, peaked at 6 months and started declining thereafter. Peripheral blood smear examination showed no absolute and atypical lymphocytosis. Cytomegalovirus PCR in the blood and throat culture for streptococcus were negative. There was no splenomegaly. He was managed conservatively with intravenous fluids, bed rest, antipyretics and reduction of immunosuppression. **Conclusions:** EBV serological markers have a limited role in the early diagnosis of EBV-IM following RT in prior seronegative children. Initial heterophile antibody test may also be negative, and hence a repeat test may be necessary. Once becoming positive, the VCA IgM may remain persistently elevated for prolonged duration. In addition to the suppressed cellular immunity secondary to immunosuppression, humoral response to viral infections is also delayed in transplant recipients, especially in the early transplant period. Hence, routine monitoring with PCR is superior to serology in diagnosing IM early and monitoring the EBV infection post-RT for timely evaluation and management.

Keywords: Epstein–Barr virus; serology; mononucleosis; renal transplant; pediatric

1. Introduction

Epstein–Barr virus (EBV), a double-stranded, enveloped DNA virus, belonging to the gamma herpes virus family, is the most common cause of infectious mononucleosis (IM). EBV infects over 90% of the human population worldwide and the rates of infection are higher among ages 15–24 years with 6–8 cases/1000 persons per year [1]. By four years of age, EBV seroprevalence is close to 100% in developing countries and 25–50% in lower socioeconomic groups in the United States [2]. IM is characterized by a triad of fever, tonsillar pharyngitis, and cervical lymphadenopathy [3]. The primary modes of exposure are saliva, organ transplantation or blood transfusion [4,5]. EBV-associated IM is a benign lymphoproliferative disorder in most immunocompetent patients, but may cause significant morbidity and mortality in those who are immunosuppressed, including renal transplant (RT) recipients [6,7]. EBV predominantly infects the epithelial and B cells. In RT recipients, the decreased anti-EBV T-cell immune surveillance, due to usage of immunosuppressive agents, may allow aberrant outgrowth of EBV-transformed B-cells leading to malignant post-transplant lymphoproliferative disorders (PTLD) [8–10]. The risk for developing PTLD is especially higher in pre-transplant EBV seronegative recipients, which is true for most young children. The incidence rate of PTLD is 4–22% for the various categories of pediatric organ transplant recipients as opposed to an average of 1–2% in adults [11].

Similar to the non-immunosuppressed patients, the presumptive diagnosis of EBV-associated IM in immunosuppressed RT recipients can be made clinically. However, a definite diagnosis does require demonstration of positive EBV serology and/or heterophile test since IM-like clinical picture can be seen with cytomegalovirus (CMV), human immunodeficiency virus (HIV) and Group A streptococcal infections [12,13], among others. The virus-specific serology poses a challenge, especially in prior seronegative children, due to delayed or absent humoral response [14]. In addition, heterophile tests (monospot) tests are less sensitive early in the course of illness and in young children [15,16]. Hence, relying on these tests only may cause a delay in diagnosis. Quantitative polymerase chain reaction (PCR) to detect EBV DNA in whole blood or serum is used to monitor EBV infection in the RT recipients [17]. Since PCR is independent of the body's ability to mount cellular or humoral immunity, it can be a more reliable test to confirm EBV mononucleosis in the presence of clinical signs and symptoms. Here, we present a 14-year-old EBV-seronegative adolescent who presented with typical clinical features of IM, negative serology and monospot test, but with positive PCR, three months after RT from a seropositive donor.

2. Methodology

Heterophile antibody test was performed by both solid phase immunoassay and by latex agglutination assay. Antibodies to viral capsid antigen (VCA) IgM and IgG, early and nuclear antigens, were performed by semi-quantitative chemiluminescent immunoassay. EBV viral load was measured by quantitative PCR.

3. Case Presentation

A 14-year-old Caucasian male with hemophilia B underwent a deceased donor RT for end stage renal disease secondary to ischemic renal injury from intra-abdominal bleeding at birth. Chronic nightly peritoneal dialysis was initiated five months prior to the transplant. Treatment for hemophilia B included factor IX replacement therapy. He did not require blood transfusions due to the neonatal period. He had received all routine immunizations prior to the transplant. Induction was done with a total of 4.5 mg/kg of Thymoglobulin and maintenance immunosuppression consisted of tacrolimus and mycophenolate. He was on a steroid withdrawal protocol. There was an EBV mismatch between the donor and recipient (donor positive and recipient negative for EBV immunoglobulin (Ig) G). His serum EBV VCA IgG was 10.5 IU/mL (not detected: 17.9 U/mL or less) at the time of transplant. Both donor and recipient were CMV IgG positive. He had an immediate recovery of renal function post-RT with

baseline serum creatinine of 0.9–1 mg/dL. Monthly viral surveillances for EBV, CMV and BK virus post-RT showed absence of viremia by PCR. Three months post-RT, he presented with fever, sore throat, and fatigue. His immunosuppression regimen at that time included tacrolimus 1.5 mg twice daily and mycophenolate 500 mg twice daily. Serum trough tacrolimus levels were at therapeutic level, as per our institution's protocol. Anti-infective prophylaxis consisted of sulfamethoxazole-trimethoprim 800–160 mg three times weekly, and valganciclovir 450 mg daily. He had completed a 6-week course of prophylactic nystatin post-RT. Treatment of hemophilia B continued with once weekly factor IX infusions. There were no household sick contacts and he denied oral contact with another person. He had no other post-operative complications or acute rejection and reported adherence to the medications.

Ten days prior to this presentation, the patient had developed a sore throat and fatigue for a week. Both the rapid streptococcal and heterophile antibody test by latex agglutination were negative at that time. Supportive measures for viral pharyngitis were done; however, over the next 10 days, his symptoms progressed with the development of fever, prompting this presentation.

On examination, his vital signs were as follows: temperature 101.1 °F, pulse 100 beats per minute, respiratory rate 18 per minute, oxygen saturation 99% on room air, and blood pressure 130/80 mm Hg. Height and weight were both at 50th centile. He was ill-appearing and was sitting in a tripod position. Throat and neck examination showed significant bilateral tonsillar enlargement, erythema, and exudate (Figure 1) and tender anterior cervical lymphadenopathy. Abdominal examination showed no tenderness to palpation over his transplanted kidney in his right lower quadrant and an absence of splenomegaly. Investigations revealed elevated serum C-reactive protein of 40 mg/L (0–5 mg/L), white blood cell count of $3.4 \times 10^3/\text{mm}^3$, absolute neutrophil and lymphocyte count of 2800 cells/ μL and 240 cells/ μL , respectively, and atypical lymphocytes of 1%. Hemoglobin, platelet count and liver function test were all in normal range. Renal function test showed serum creatinine of 1.2 mg/dL (baseline 0.9–1 mg/dL) with stable electrolytes. Given EBV discordance (donor EBV + and recipient EBV –) along with fever, exudative tonsillitis, cervical lymphadenopathy and fever, there was a high index of suspicion for IM secondary to EBV. However, the heterophile antibody test by both solid phase immunoassay and latex agglutination assays was negative again. Furthermore, the serologic tests were all negative (EBV VCA IgM < 10 U/mL (not detected: 0–43.9 IU/mL), VCA IgG 15 IU/mL (not detected: 0–17.9 IU/mL), early antigen (EA) IgG < 5 IU/mL (not detected: 0–8.9 IU/mL), nuclear antigen (EBNA) IgG < 3 IU/mL (not detected: 0–17.9 IU/mL)). Serum CMV PCR and BK virus PCRs were negative. Whole blood EBV quantitative PCR showed EBV viral load of 1970 copies/mL (undetectable: <390 copies/mL; ARUP laboratories, Salt lake City, UT, USA). Prior EBV PCR loads were undetectable at one and two month post-RT follow-up appointments. *Bartonella henselae*, *Bartonella quintana*, *Toxoplasma gondii* IgG and IgM antibodies along with serum adenovirus PCR were all negative. Serum tacrolimus trough level was at goal (6–7 ng/mL, as per our institution's protocol). Hepatitis screen, HIV, antinuclear antibody, and rheumatoid factor were negative. Peripheral blood smear did not show evidence of blast cells. Abdominal sonogram showed normal appearing renal transplant with no splenomegaly. Throat culture was negative for beta-hemolytic streptococcus, *corynebacterium diphtheriae*, fungus, chlamydia and gonorrhea. Nasopharyngeal swab test for influenza and other respiratory viruses were negative. Due to tripod position on examination, X-ray along with computed tomography scan of the neck without contrast were done which showed narrowing of the airway due to soft tissue swelling but without any peritonsillar or retropharyngeal abscess. However, his respiratory status remained stable on room air throughout without the need for supplemental oxygen therapy. Steroid therapy was not required. He also developed acute hemoptysis, most likely secondary to tonsillar friability in the setting of low factor IX levels, prompting administration of an additional dose of factor IX with resolution of hemoptysis. He was treated with acetaminophen, intravenous fluid therapy and 3rd generation cephalosporin, the latter was discontinued after the throat and blood bacterial cultures resulted negative. Mycophenolate dose was decreased to 250 mg twice daily. He was discharged to home on sixth day of admission once he became afebrile and adequate oral intake was

ensured. Discharge medications consisted of tacrolimus, mycophenolate, valganciclovir, TMP-SMX and factor IX replacement therapy.

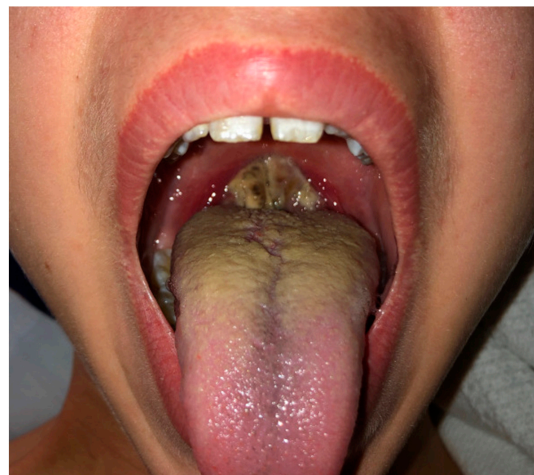

Figure 1. Oropharyngeal examination showing bilateral tonsillar enlargement with exudates.

At subsequent outpatient clinic follow-up visits, whole blood EBV PCR showed a persistent rise to a peak level of 10,200 copies/mL at 6 months, and then gradual decline to 2460 copies/mL at 9 months post-RT (Figure 2). VCA IgM and IgG both became positive at 5 months and subsequently peaked at his most recent 9-month follow-up (Figure 2). Monospot test (latex agglutination) also became positive at 5 months and remained positive at the 9 month post-RT follow-up. Clinical examination showed persistent mild sore throat, tonsillar enlargement and cervical lymphadenopathy until about 5 months when the symptoms started resolving. At his most recent 9-month follow-up visit, he was asymptomatic with resolution of tonsillar enlargement and cervical lymphadenopathy. Renal allograft function remained stable. Serum CMV and BK virus PCRs remained negative.

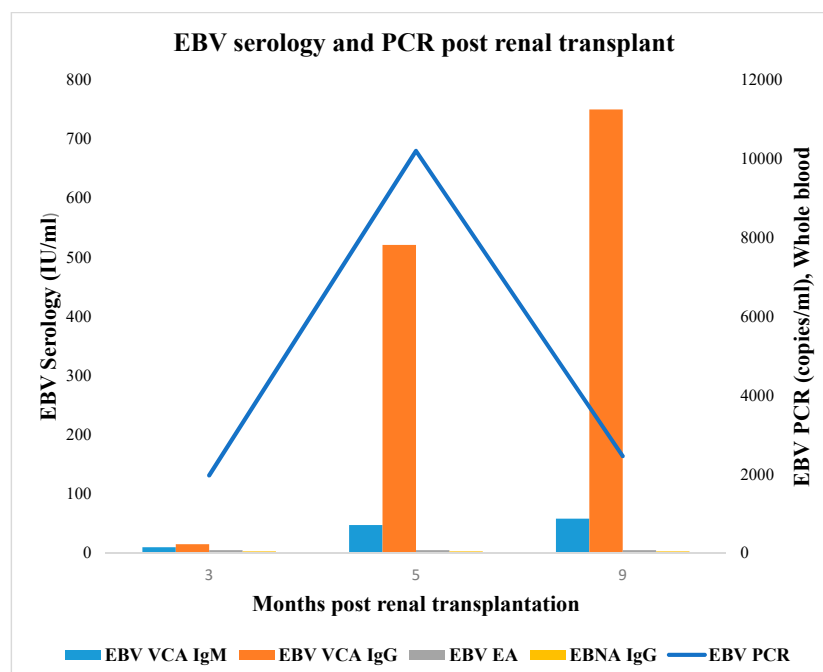


Figure 2. Timeline of Epstein–Barr virus (EBV) serology and polymerase chain reaction (PCR) post-renal transplantation. EBV serologies (viral capsid antigen (VCA) IgM, VCA IgG, early antigen (EA) and nuclear antigen (EBNA) IgG expressed in IU/mL) and EBV DNA PCR expressed in copies/mL.

4. Discussion

EBV infection in transplant recipients may be a primary infection or a reactivation of a prior latent infection [8,18]. Primary infection occurs mainly via exchange of saliva or sharing household items from close-contacts, transplantation of kidney from a seropositive donor in a seronegative recipient or through blood transfusions [19,20]. Reactivation occurs in those with latent EBV and then undergo active viral multiplication in the setting of immunosuppression post-RT. The serologic diagnosis of reactivation/reinfection requires a 10-fold increase in anti-VCA IgG or the presence of anti-VCA IgM in previously IgG seropositive patients [21]. Our patient did not have a history of saliva exchange, sick contacts, and blood transfusions; hence he most likely had a primary infection through the transplantation from the seropositive donor. A single center study of pediatric solid organ transplant (SOT) recipients showed that the seroconversion rate in prior seronegative pediatric liver transplant patients was >75% while reactivation occurred in 50% of prior seropositive recipients [22]. Patients with primary infection had more viral shedding than those who were seropositive at the time of transplant, and heart transplant recipients had higher levels of peak shedding than renal allograft recipients [23]. In terms of risk factor for development of PTLD, primary EBV infection has been shown to be much more of a risk than reactivated infection [24]. Ho et al. described 11 children with EBV-associated lymphoproliferative syndrome post-SOT and 10 had a primary infection. These children were at greater risk due to them being seronegative for EBV prior to the transplant who then acquired primary infection with the transplant from seropositive donor [22]. Other studies have similarly shown that recipients who are seronegative at the time of transplant are more likely to be symptomatic and have EBV related complications, such as PTLD [6,7,25].

The most commonly used tests to diagnose EBV-associated IM include heterophile test, serology and PCR. Paul-Bunnell test, the original heterophile antibody test, utilized sheep red blood cells (RBC) while most of the currently used heterophile antibody or the Monospot tests use horse RBCs with improvement in the test if these RBCs were first absorbed to guinea pig kidney or bovine RBCs before sera were added [26]. In immunocompetent patients, initially, the B cells produce polyclonal antibodies in response to EBV infection which are directed against viral and unrelated antigens found on sheep and horse RBCs. The antibodies against the latter antigens, termed heterophile antibodies, comprise only about 5% of total polyclonal antibodies [27]. They are mostly IgM antibodies that do not cross-react with EBV antigens and are the basis of heterophile antibody test [28,29]. Later in the course of EBV infection, these B cells are kept in check by the recruitment of cytotoxic CD8+ T cells which provide a polyclonal regulatory response, and are an important part of host defense mechanism against EBV [30]. Since the peak levels of virus-specific IgM and IgG response usually occurs only around 6–17 days after the onset of clinical symptoms, the serology may not be helpful in the early stage of presentation [31]. The incubation period of IM is usually 2–7 weeks and since the heterophile antibodies are seen 2–9 weeks after the person is infected, heterophile antibody tests may be preferable for early diagnosis at the time of presentation. Commercial test kits for these antibodies (by solid phase immunoassay or latex agglutination assay) are available and have sensitivities of 70–92% and a specificity of 96–100%, with a lower sensitivity in the first two weeks of illness [32]. The false negativity rate of these tests could be as high as 25% in the first week, 5–10% in the second week, and 5% in the third week [15]. Latex-based heterophile antibody assays may be a little more sensitive than the solid phase assays but the specificity is similar between the two [33]. Our patient was tested with both solid phase and latex agglutination assays. In addition, in younger patients less than 12 years of age, the test sensitivity is only 25–50%, as compared to 71–91% in older patients [15]. Horwitz et al. showed that children 1–2 years of age were significantly less likely to have positive heterophile antibody tests compared with children 2–4 years of age (27.3% vs. 76.2%) [16]. Therefore, heterophile tests may only be appropriate for use in older children. Once formed, these antibodies disappear in few weeks but in some, they may persist for up to a year after infection [28]. Hence, heterophile antibody tests may help diagnose IM retrospectively in some patients, if the initial test was negative, as in our case. Moreover, the antibodies detected by the test can be caused by conditions other than IM (for example,

CMV, hepatitis, rubella, HIV, autoimmune conditions, adenovirus) due to cross reactivity with these conditions [32]. Our patient had negative CMV and adenovirus PCRs along with negative hepatitis and HIV tests. Due to these limitations, Center for Disease Control and Prevention in United States does not recommend the heterophile test for general use in the diagnosis of IM, instead suggesting viral serology as a method of choice [34].

The initial serologic response to EBV infection occurs with the production of IgM antibody to the VCA in about 75% of patients [35], which usually disappears within 4–6 weeks. In immunosuppressed patients, however, the viral shedding may be prolonged, symptoms may last longer and be more severe [36]. Hence, once the intense immunosuppression period of T lymphocyte depletion is over (usually few months post-transplant), in the setting of persistent viral shedding, the newly produced host T cells will continue to stimulate B cells to produce virus-specific IgM and IgG. This could have led to the delayed onset but more prolonged presence of IgM antibody in our patient. Anti-VCA IgG also appears in the acute phase of EBV infection, peaks at 2–4 weeks after onset in most patients, declines slightly and then persists for the rest of a person's life. Hence, the presence of VCA IgG indicates that the infection has occurred in the past. Antibody to early antigen (EA) is present in 60–80% only, and may indicate active viral replication and is especially helpful if the heterophile antibody is negative and VCA IgG or IgM yields inconclusive results. Of note, 20% of healthy individuals can have EBV EA antigen [35]. Anti-EA IgG generally falls to undetectable levels after 3–6 months. Antibody to nuclear antigen (EBNA) is not seen in the acute phase but slowly appears 2–4 months after the onset of symptoms and persists for the rest of a person's life [37]. The infection then remains latent. Hence, the comparison of paired sera from acute and convalescent period showing presence of EBNA IgG in the absence of VCA IgM rules out the acute infection. With regards to the efficacy of serology, Bruu et al. analyzed six commercial tests for EBV-specific antibodies, with sensitivities ranging from 95–100% and specificities ranging from 86–100% [38]. Hence, EBV-specific serology appears to be more sensitive but less specific than heterophile antibody testing. The reduced specificity is due to significant cross-reactivity of VCA-IgM to other infections such as CMV [38]. On the other hand, increased sensitivity of serology, including IgM, can produce false positive results [39].

Similar to the delayed serological response after immunization in SOT recipients [40], serology unfortunately is unreliable as a diagnostic test for either PTLD or primary EBV infection in transplant recipients [8]. These patients show a marked delay in their humoral response to EBV antigens, and many fail to develop IgM antibodies altogether [8,14,41]. Both T and B cells are required to induce an antibody response. T follicular helper cells provide seven main forms of T cell help to B cells: signals that promote survival, proliferation, plasma cell differentiation, hypermutation, class-switch recombination, adhesion and chemo-attraction (cell migration) [42]. Hence, in the absence of cytotoxic T cells secondary to usage of lymphocyte-depleting immunosuppressive agents, the humoral response is also inhibited along with cellular immunity [42]. This state of T cell anergy allows EBV to escape the immune elimination by utilizing a distinct latency expression programs to establish a persistent infection and potentially leading to PTLD [30,43]. It is important to remember that T cell anergy can also occur due to T cell receptor-specific impairment in the induction of genes involved in T cell proliferation, allowing uninhibited proliferation of infected B cells, in some immunocompetent patients with acute IM [44]. Regardless of the mechanism of anergy, the antibody response is reduced and in some cases may be selective. Diminished or absent antibody response to EBNA may be observed despite persistence of anti VCA IgG. Cen et al. described a markedly reduced antibody response to the latent cycle antigens, EBNA 1, EBNA 2 and EBNA-LP in immunosuppressed SOT recipients with PTLD, but not to the lytic cycle VCA when compared to the normal immunocompetent controls [45]. At 9-month follow-up, our patient had not been able to produce anti-EBNA IgG although the VCA IgG had reached its peak level. Hence, the typical pattern of appearance of serological markers may not be evident in these patients.

EBV PCR measures the quantitative viral load in the blood and is the most sensitive test for detecting EBV infection in the post-transplant period [17]. A variety of blood specimens have been used

for EBV load quantification, including unfractionated whole blood, peripheral blood mononuclear cells, and plasma. However, the whole blood EBV DNA is believed to be superior to plasma EBV DNA as the cell-associated EBV can be detected well before the plasma DNA is detected. Additionally, the cell DNA may be present at high levels without even being present in the plasma [21,46]. The whole blood sample is also simple to process and provides quantification of both cell-associated and cell-free virus, yielding an absolute viral load, irrespective of concerns about fluctuations in cell number, lysis and loss during separation [17]. Hence, transplant clinical guidelines suggest monitoring of high-risk patients for EBV-related PTLD by nucleic acid testing post-RT instead of serology [47]. In a large, retrospective study of the incidence of PTLD in RT recipients in the United States, the risk of PTLD was more than six times higher for donor+/recipient- deceased donor transplants compared with R+ transplants [48]. However, there are no clinical guidelines that exist for diagnosis of EBV-IM without PTLD in the post-RT period. Since the EBV serology and heterophile tests may be negative in the early post-RT period, this report emphasizes the value of repeat testing of serology and heterophile tests to establish a diagnosis of IM. It is important to know that since low level detection of EBV by PCR is common in transplant recipients [49], the mere presence of a positive viral load does not always indicate mononucleosis in the absence of the classic presentation such as lymphadenopathy, pharyngitis and fever. Hence, the serial testing of serology and heterophile tests may have a role in retrospectively establishing a diagnosis of IM in these patients.

Other tests that may be useful in diagnosis of IM are lymphocyte to white cell count ratio, real-time PCR targeting various EBV genes, an absolute increase in the number of peripheral lymphocytes, and atypical lymphocytes [50–52]. Studies on lymphocyte to white cell count ratio as a diagnostic marker of IM has shown conflicting results [50]. Usage of raised absolute lymphocyte count has been suggested as providing a quick clue to the diagnosis of IM while awaiting for serology or heterophile antibody test result [52]. The atypical lymphocytes are primary T cells, produced in response to the EBV-infected B cells [29]. Commonly, absolute lymphocytosis (>50% lymphocytes) in the presence of >10% atypical lymphocytes are considered diagnostic of IM. The case presented in this report did not have absolute lymphocytosis with only 1% atypical lymphocytes, most likely secondary to lymphopenia from immunosuppression. Hence, lymphocyte-based assays are unlikely to be useful in transplant recipients, especially in the early post-transplant period.

5. Conclusions

The EBV serology may underestimate the active presence of EBV in seronegative SOT recipients. Furthermore, in the absence of positive heterophile antibodies, the confirmatory diagnosis of mononucleosis becomes much more difficult. Not only has the EBV DNA load in the blood allowed risk assessment of development of EBV-associated disease in immunosuppressed patients, it also is helpful in making a definite diagnosis of IM in the presence of clinical signs and symptoms.

Author Contributions: A.B.: Collected data and prepared the original draft; R.B., F.J.: Collected data and prepared the original draft, and critically reviewed and revised the manuscript. K.U.: Conceptualized the study, collected data and prepared the original draft, and critically reviewed and revised the manuscript. All authors have read and agreed to the published version of the manuscript.

Funding: This study received no funding.

Conflicts of Interest: The authors declare no conflict of interest.

References

1. Fleisher, G.; Henle, W.; Henle, G.; Lennette, E.T.; Biggar, R.J. Primary infection with Epstein-Barr virus in infants in the United States. *J. Infect. Dis.* **1979**, *139*, 553–558. [[CrossRef](#)] [[PubMed](#)]
2. Gares, V.; Panico, L.; Castagne, R.; Delpierre, C.; Kelly-Irving, M. The role of the early social environment on Epstein Barr virus infection: A prospective observational design using the millennium cohort study. *Epidemiol. Infect.* **2017**, *145*, 3405–3412. [[CrossRef](#)] [[PubMed](#)]

3. Vetsika, E.K.; Callan, M. Infectious mononucleosis and epstein-barr virus. *Expert Rev. Mol. Med.* **2004**, *6*, 1–16. [[CrossRef](#)]
4. Cen, H.; Breinig, M.C.; Atchison, R.W.; Ho, M.; McKnight, J.L.C. Epstein-Barr virus transmission via the donor organs in solid organ transplantation: Polymerase chain reaction and restriction fragment length polymorphism analysis of IR2, IR3, and IR4. *J. Virol.* **1991**, *65*, 976–980. [[CrossRef](#)]
5. White, S.L.; Rawlinson, W.; Boan, P.; Sheppard, V.; Wong, G.; Waller, K.; Opdam, H.; Kaldor, J.; Fink, M.; Verran, D.; et al. Infectious disease transmission in solid organ transplantation: Donor evaluation, recipient risk, and outcomes of transmission. *Transplant. Direct* **2018**, *5*, e416. [[CrossRef](#)]
6. Saeed, B. Pediatric renal transplantation. *Int. J. Organ. Transplant. Med.* **2012**, *3*, 62–73.
7. Fishman, J.A. Infection in solid-organ transplant recipients. *N. Engl. J. Med.* **2007**, *357*, 2601–2614. [[CrossRef](#)]
8. Allen, U.; Alfieri, C.; Preiksaitis, J.; Humar, A.; Moore, D.; Tapiero, B.; Tellier, R.; Green, M.; Davies, D.; Hébert, D.; et al. Canadian PTLTD Workshop Group—1999. Epstein-Barr virus infection in transplant recipients: Summary of a workshop on surveillance, prevention and treatment. *Can. J. Infect. Dis.* **2002**, *13*, 89–99. [[CrossRef](#)]
9. Paya, C.V.; Fung, J.J.; Nalesnik, M.A.; Kieff, E.; Green, M.; Gores, G. Epstein-Barr virus-induced posttransplant lymphoproliferative disorders, ASTS/ASTP EBV-PTLD Task Force and The Mayo Clinic Organized International Consensus Development Meeting. *Transplantation* **1999**, *68*, 1517–1525. [[CrossRef](#)]
10. Küppers, R. B cells under influence: Transformation of B cells by epstein-barr virus. *Nat. Rev. Immunol.* **2003**, *3*, 801–812. [[CrossRef](#)]
11. Savoie, A.; Perpète, C.; Carpentier, L.; Joncas, J.; Alfieri, C. Direct correlation between the load of epstein-barr virus-infected lymphocytes in the peripheral blood of pediatric transplant patients and risk of lymphoproliferative disease. *Blood* **1994**, *83*, 2715–2722. [[CrossRef](#)] [[PubMed](#)]
12. Klemola, E.; Von Essen, R.; Henle, G.; Henle, W. Infectious-mononucleosis-like disease with negative heterophil agglutination test. Clinical features in relation to epstein-barr virus and cytomegalovirus antibodies. *J. Infect. Dis.* **1970**, *121*, 608–614. [[CrossRef](#)] [[PubMed](#)]
13. Gaines, H.; von Sydow, M.; Pehrson, P.O.; Lundbegh, P. Clinical picture of primary HIV infection presenting as a glandular-fever-like illness. *BMJ* **1988**, *297*, 1363–1368. [[CrossRef](#)] [[PubMed](#)]
14. Preiksaitis, J.K.; Diaz-Mitoma, F.; Mirzayans, F.; Roberts, S.; Tyrrell, D.L. Quantitative oropharyngeal epstein-barr virus shedding in renal and cardiac transplant recipients: Relationship to immunosuppressive therapy, serologic responses, and the risk of posttransplant lymphoproliferative disorder. *J. Infect. Dis.* **1992**, *166*, 986–994. [[CrossRef](#)] [[PubMed](#)]
15. Ebell, M.H. Epstein-Barr virus infectious mononucleosis. *Am. Fam. Physician* **2004**, *70*, 1279–1287.
16. Horwitz, C.A.; Henle, W.; Henle, G.; Goldfarb, M.; Kubic, P.; Gehrz, R.C.; Balfour, H.H., Jr.; Fleisher, G.R.; Krivit, W. Clinical and laboratory evaluation of infants and children with epstein-barr virus-induced infectious mononucleosis: Report of 32 patients (aged 10–48 months). *Blood* **1981**, *57*, 933–938. [[CrossRef](#)]
17. Stevens, S.J.; Verschuuren, E.A.; Verkuujlen, S.A.; Van Den Brule, A.J.; Meijer, C.J.; Middeldorp, J.M. Role of epstein-barr virus DNA load monitoring in prevention and early detection of post-transplant lymphoproliferative disease. *Leuk. Lymphoma* **2002**, *43*, 831–840. [[CrossRef](#)]
18. Höcker, B.; Fickenscher, H.; Delecluse, H.J.; Böhm, S.; Küsters, U.; Schnitzler, P.; Pohl, M.; John, U.; Kemper, M.J.; Fehrenbach, H.; et al. Epidemiology and morbidity of epstein-barr virus infection in pediatric renal transplant recipients: A multicenter, prospective study. *Clin. Infect. Dis.* **2013**, *56*, 84–92. [[CrossRef](#)]
19. Hosseini-Moghaddam, S.M.; Alhomayeed, B.; Soliman, N.; Weir, M.A.; House, A.A. Primary epsteinbarr virus infection, seroconversion, and post-transplant lymphoproliferative disorder in seronegative renal allograft recipients: A prospective cohort study. *Transpl. Infect. Dis.* **2016**, *18*, 423–430. [[CrossRef](#)]
20. Alfieri, C.; Tanner, J.; Carpentier, L.; Perpète, C.; Savoie, A.; Paradis, K.; Delage, G.; Joncas, J. Epstein-Barr virus transmission from a blood donor to an organ transplant recipient with recovery of the same virus strain from the recipient’s blood and oropharynx. *Blood* **1996**, *87*, 812–817. [[CrossRef](#)]
21. Rose, C.; Green, M.; Webber, S.; Ellis, D.; Reyes, J.; Rowe, D. Pediatric solid-organ transplant recipients carry chronic loads of epstein-barr virus exclusively in the immunoglobulin D-negative B-cell compartment. *J. Clin. Microbiol.* **2001**, *39*, 1407–1415. [[CrossRef](#)] [[PubMed](#)]
22. Ho, M.; Jaffe, R.; Miller, G.; Breinig, M.K.; Dummer, J.S. The frequency of epstein-barr virus infection and associated lymphoproliferative syndrome after transplantation and its manifestations in children. *Transplantation* **1988**, *45*, 719–727. [[CrossRef](#)] [[PubMed](#)]

23. Preiksaitis, J.K. Lymphoproliferative disorders in renal transplant recipients: Virologic aspects. *Clin. Transplant.* **1992**, *6*, 235–239.
24. Ho, M.; Miller, G.; Atchison, R.W.; Breinig, M.K.; Dummer, J.S.; Andiman, W.; Starzl, T.E.; Eastman, R.; Griffith, B.P.; Hardesty, R.L.; et al. Epstein-Barr virus infections and DNA hybridization studies in posttransplantation lymphoma and lymphoproliferative lesions: The role of primary infection. *J. Infect. Dis.* **1985**, *152*, 876–878. [[CrossRef](#)]
25. Nijland, M.L.; Kersten, M.J.; Pals, S.T.; Bemelman, F.J.; Ten Berge, I.J. Epstein-Barr Virus-positive posttransplant lymphoproliferative disease after solid organ transplantation: Pathogenesis, clinical manifestations, diagnosis, and management. *Transplant. Direct* **2015**, *2*, e48. [[CrossRef](#)]
26. Lee, C.L.; Zandrew, F.; Davidsohn, I. Horse agglutinins in infectious mononucleosis: III criterion for differential diagnosis. *J. Clin. Pathol.* **1968**, *21*, 631–634. [[CrossRef](#)]
27. Wollheim, F.A.; Williams, R.C., Jr. Studies on the macroglobulins of human serum- polyclonal immunoglobulin class M (IgM) increase in infectious mononucleosis. *N. Engl. J. Med.* **1966**, *274*, 61–67. [[CrossRef](#)]
28. Marshall-Andon, T.; Heinz, P. How to use ... the monospot and other heterophile antibody tests. *Arch. Dis. Child. Educ. Pract. Ed.* **2017**, *102*, 188–193. [[CrossRef](#)]
29. Cohen, J.I. Epstein-Barr virus infection. *N. Engl. J. Med.* **2000**, *343*, 481–492. [[CrossRef](#)]
30. Tosato, G.; Magrath, I.; Koski, I.; Dooley, N.; Blaese, M. Activation of suppressor T cells during epstein-barr-virus-induced infectious mononucleosis. *N. Engl. J. Med.* **1979**, *301*, 1133–1137. [[CrossRef](#)]
31. Svedmyr, E.; Ernberg, I.; Seeley, J.; Weiland, O.; Masucci, G.; Tsukuda, K.; Szigeti, R.; Masucci, M.G.; Blomgren, H.; Berthold, W.; et al. Virologic, immunologic, and clinical observations on a patient during the incubation, acute, and convalescent phases of infectious mononucleosis. *Clin. Immunol. Immunopathol.* **1984**, *30*, 437–450. [[CrossRef](#)]
32. Elgh, F.; Linderholm, M. Evaluation of six commercially available kits using purified heterophile antigen for the rapid diagnosis of infectious mononucleosis compared with epstein-barr virus-specific serology. *Clin. Diagn. Virol.* **1996**, *7*, 17–21. [[CrossRef](#)]
33. Cook, L.; Midgett, J.; Willis, D.; Clinton, B.; Folds, J.D. Evaluation of latex-based heterophile antibody assay for diagnosis of acute infectious mononucleosis. *J. Clin. Microbiol.* **1987**, *25*, 2391–2394. [[CrossRef](#)] [[PubMed](#)]
34. Centre for Disease Control. Epstein-Barr Virus and Infectious Mononucleosis: Laboratory Testing. Available online: <http://www.cdc.gov/epstein-barr/laboratory-testing.html> (accessed on 20 March 2020).
35. Balfour, H.H., Jr.; Dunmire, S.K.; Hogquist, K.A. Infectious mononucleosis. *Clin. Transl. Immunol.* **2015**, *4*, e33. [[CrossRef](#)] [[PubMed](#)]
36. Van der Vries, E.; Stittelaar, K.J.; van Amerongen, G.; Veldhuis Kroeze, E.J.; de Waal, L.; Fraaij, P.L.; Meesters, R.J.; Luider, T.M.; van der Nagel, B.; Koch, B.; et al. Prolonged influenza virus shedding and emergence of antiviral resistance in immunocompromised patients and ferrets. *PLoS Pathog.* **2013**, *9*, e1003343. [[CrossRef](#)] [[PubMed](#)]
37. Nalesnik, M.A.; Starzl, T.E. Epstein-Barr virus, infectious mononucleosis, and posttransplant lymphoproliferative disorders. *Transplant. Sci.* **1994**, *4*, 61–79.
38. Bruu, A.L.; Hjetland, R.; Holter, E.; Mortensen, L.; Natås, O.; Petterson, W.; Skar, A.G.; Skarpaas, T.; Tjade, T.; Asjøl, B. Evaluation of 12 commercial tests for detection of epstein-barr virus-specific and heterophile antibodies. *Clin. Diagn. Lab. Immunol.* **2000**, *7*, 451–456. [[CrossRef](#)]
39. Landry, M.L. Immunoglobulin M for Acute Infection: True or False? *Clin. Vaccine Immunol.* **2016**, *23*, 540–545. [[CrossRef](#)]
40. Eckerle, I.; Rosenberger, K.D.; Zwahlen, M.; Junghans, T. Serologic vaccination response after solid organ transplantation: A systematic review. *PLoS ONE* **2013**, *8*, e56974. [[CrossRef](#)]
41. Purtilo, D.T.; Strobach, R.S.; Okano, M.; Davis, J.R. Epstein-Barr virus-associated lymphoproliferative disorders. *Lab. Invest.* **1992**, *67*, 5–23.
42. Crotty, S. A brief history of T cell help to B cells. *Nat. Rev. Immunol.* **2015**, *15*, 185–189. [[CrossRef](#)] [[PubMed](#)]
43. Middeldorp, J.M.; Pegtel, D.M. Multiple roles of LMP1 in epstein-barr virus induced immune escape. *Semin. Cancer Biol.* **2008**, *18*, 388–396. [[CrossRef](#)] [[PubMed](#)]
44. Pérez-Blas, M.; Regueiro, J.R.; Ruiz-Contreras, J.R.; Arnaiz-Villena, A. T lymphocyte anergy during acute infectious mononucleosis is restricted to the clonotypic receptor activation pathway. *Clin. Exp. Immunol.* **1992**, *89*, 83–88. [[CrossRef](#)]

45. Cen, H.; Williams, P.A.; McWilliams, H.P.; Breinig, M.C.; Ho, M.; McKnight, J.L. Evidence for restricted epstein-barr virus latent gene expression and anti-EBNA antibody response in solid organ transplant recipients with post-transplant lymphoproliferative disorders. *Blood* **1993**, *81*, 1393–1403. [[CrossRef](#)]
46. Stevens, S.J.C.; Pronk, I.; Middeldorp, J.M. Toward standardization of epstein–barr virus DNA load monitoring: Unfractionated whole blood as preferred clinical specimen. *J. Clin. Microbiol.* **2001**, *39*, 1211–1216. [[CrossRef](#)]
47. Kidney Disease: Improving Global Outcomes (KDIGO) Transplant Work Group. KDIGO clinical practice guideline for the care of kidney transplant recipients. *Am. J. Transplant.* **2009**, *9* (Suppl. S3), S1–S155. [[CrossRef](#)]
48. Sampaio, M.S.; Cho, Y.W.; Shah, T.; Bunnapradist, S.; Hutchinson, I.V. Impact of epstein-barr virus donor and recipient serostatus on the incidence of post-transplant lymphoproliferative disorder in kidney transplant recipients. *Nephrol. Dial. Transplant.* **2012**, *27*, 2971–2979. [[CrossRef](#)]
49. Baldanti, F.; Grossi, P.; Furione, M.; Simoncini, L.; Sarasini, A.; Comoli, P.; Maccario, R.; Fiocchi, R.; Gerna, G. High levels of epstein-barr virus DNA in blood of solid-organ transplant recipients and their value in predicting posttransplant lymphoproliferative disorders. *J. Clin. Microbiol.* **2000**, *38*, 613–619. [[CrossRef](#)]
50. Lennon, P.; O’Neill, J.P.; Fenton, J.E.; O’Dwyer, T. Challenging the use of the lymphocyte to white cell count ratio in the diagnosis of infectious mononucleosis by analysis of a large cohort of monospot test results. *Clin. Otolaryngol.* **2010**, *35*, 397–401. [[CrossRef](#)]
51. Lay, M.L.; Lucas, R.M.; Ratnamohan, M.; Taylor, J.; Ponsonby, A.-L.; Dwyer, D.E.; The Ausimmune Investigator Group (AIG). Measurement of epstein-barr virus DNA load using a novel quantification standard containing two EBV DNA targets and SYBR Green I dye. *Viol. J.* **2010**, *7*, 252. [[CrossRef](#)]
52. Biggs, T.C. Use of the absolute lymphocyte count in the diagnosis of infectious mononucleosis. *Clin. Otolaryngol.* **2011**, *36*, 515–516. [[CrossRef](#)] [[PubMed](#)]



© 2020 by the authors. Licensee MDPI, Basel, Switzerland. This article is an open access article distributed under the terms and conditions of the Creative Commons Attribution (CC BY) license (<http://creativecommons.org/licenses/by/4.0/>).