

# A review of techniques of iris replication and a novel method of fabrication of ocular prosthesis using two different iris location methods

## ABSTRACT

Anophthalmic patients suffer from social, functional, and emotional agony. The role of a maxillofacial prosthodontist is to restore this loss and to restore the self-esteem of such patients. Fabrication of a prosthesis for the anophthalmic cavity can be successful with the judicious use of the materials, the vision, and the skill of the prosthodontist. This article describes various techniques used for iris replication and a novel method to locate the iris, which is the most crucial step to fabricate a natural gaze.

**Keywords:** Artificial eye, enucleation, iris positioning, ocular prosthesis and orbital defect

## INTRODUCTION

Maxillofacial prosthetics is the art and science of anatomic, functional, or cosmetic reconstructions carried out by means of nonliving substitutes of those regions in the maxilla, mandible, face, and even other body parts that are missing or defective due to surgical interventions, trauma and pathology, developmental or congenital malformations.<sup>[1]</sup> Facial feature is the most important nonverbal means of communication. Loss of any part of the face can cause mental trauma, which affects the patient’s social and professional life.<sup>[2]</sup> Aims of the treatment modality used for the rehabilitation of a missing eye should take into consideration the deformity, esthetic correction, protecting the orbital cavity, and preventing the flow of lacrimal fluid in the eye cavity. Although the presence of movable tissue layers may affect the quality of prosthesis retention and may cause the irritation of the underlying tissue bed.<sup>[3]</sup>

There are various materials and techniques available to rehabilitate the missing eye esthetically and to restore the orbital volume. Considering the difficulty faced to locate the iris and other factors to rehabilitate the orbital cavity naturally, the present literature review discusses

the techniques which are used for iris location and to aid maxillofacial prosthodontist in selecting appropriate technique and to rehabilitate them naturally.

## METHODS


An electronic search was conducted for articles related to iris positioning techniques and the fabrication of orbital prosthesis. The database was searched using the keywords “iris,” “ocular prosthesis,” “orbital prosthesis,” “artificial

**ANSHUL TRIVEDI, ROMA GOSWAMI, NIVEDITA BAWA, SHAMA WAHEED, JITENDRA RAO<sup>1</sup>**

Department of Prosthodontics, Crown and Bridge, Subharti Dental College and Hospital, Swami Vivekanand Subharti University, Meerut, <sup>1</sup>Department of Prosthodontics, King George’s Medical University, Lucknow, Uttar Pradesh, India

**Address for correspondence:** Dr. Anshul Trivedi, Department of Prosthodontics, Crown and Bridge, Subharti Dental College and Hospital, Swami Vivekanand Subharti University, Meerut, Uttar Pradesh, India.  
E-mail: dranshulmsaxena@gmail.com

**Received:** 09 July 2019, **Revised:** 12 December 2019, **Accepted:** 07 March 2020, **Published:** 16 March 2021

Access this article online	
<b>Website:</b> www.njms.in	<b>Quick Response Code</b> 
<b>DOI:</b> 10.4103/njms.NJMS_43_19	

This is an open access journal, and articles are distributed under the terms of the Creative Commons Attribution-NonCommercial-ShareAlike 4.0 License, which allows others to remix, tweak, and build upon the work non-commercially, as long as appropriate credit is given and the new creations are licensed under the identical terms.

**For reprints contact:** WKHLRPMedknow\_reprints@wolterskluwer.com

**How to cite this article:** Trivedi A, Goswami R, Bawa N, Waheed S, Rao J. A review of techniques of iris replication and a novel method of fabrication of ocular prosthesis using two different iris location methods. Natl J Maxillofac Surg 2021;12:3-7.

eye,” and “orbital defect.” The articles which were reviewed were the case reports and the literature review, which were published from 2005 to 2018.

### Iris replication techniques

1. Iris painting technique – This technique is based on visual assessment of the contralateral eye for the color, diameter, and the morphology of the patient under indirect sunlight, and individual’s expertise is used for replicating the same on the defect.<sup>[4]</sup>

Materials used for iris painting - Choice of the material which is used to paint iris depends on which surface the iris is made. Materials which are employed are varnishes, gouache, automotive paints, and acrylic oils. Furthermore, these materials should be carefully selected depending on their reaction to polymerization and changes during ultraviolet exposure.<sup>[5]</sup> Although gouache and acrylic present color alterations, oil paints have better color stability when exposed to the external environment.<sup>[4]</sup>

Surfaces on which painting is done the surfaces on which iris painting can be performed are black and white card boards<sup>[6]</sup> and Carmem papers<sup>[5]</sup> and celluloid acetate disc, direct painting on acrylic resin sclera, ethyl cellulose discs, and colorless acrylic ocular bottom. Of the above-mentioned surfaces for iris painting, to obtain the natural effect, the acrylic disk is painted directly to have a better visualization of the color. According to Fernandes *et al.* observed better esthetic results with painted iris on glass in comparison to other techniques.<sup>[4]</sup>

Digital imaging – With the advent of digitization and its widespread usage, it was successfully used in replicating the iris. This technique makes use of color coordinates to provide acceptable esthetic results with minimal color modifications. An advantage of this technique is, it requires minimal artistic skills, is less tedious, and uncomplicated than the manual painting technique. Although it requires special equipment and software for image replication.<sup>[5]</sup> Kale *et al.* suggested a technique with digital photography and vacuum pressing of a clear copolyester sheet on to photo paper. Although it takes considerable time and is intricate to be practiced, it replicates the patient’s iris naturally.<sup>[6]</sup>

2. Prefabricated iris button – Similar physical properties were observed when prefabricated caps were used when compared with the colorless acrylic resin in the monomer–polymer mixture.<sup>[3,7,8]</sup> However, a study conducted by Goiato *et al.* stated that the prefabricated cap technique exhibited the highest change of color values before and after the polymerization technique.<sup>[5]</sup>

3. Using graph grid on spectacles – Guttal *et al.* described a method of positioning the iris disk using the transparent graph grid.<sup>[9,10]</sup> Prosthodontists, who used this technique, experienced less chairside time as compared to the visual assessment. Furthermore, the need of armamentarium was reduced. In addition, Guttal *et al.* stated that the graph grid mounted on spectacle was more stable than that mounted on the nose.
4. The use of optical vernier interpupillary distance ruler – Chihargo and Syafrinani described the use of optical vernier interpupillary distance ruler with millimeter scale and movable frame to adjust the distance between the eyes. Subjective assessment by visual may bias the clinician to obtain precise iris position on the custom ocular prosthesis; therefore, the objective measurement for determining the iris position is essential. This method is unconstrained, reasonable, and is endorsed by the authors.<sup>[11]</sup>
5. Hanau wide view spring bow – Various methods and techniques which were used to locate iris were Mc Arthur ocular locator and fixed caliper, Robert pupilometer, Benson visual judgment, and graph grid described by Guttal *et al.* were difficult to stabilize and could not be used in patients who had facial asymmetry. To overcome these flaws Hanau wide view spring bow technique was used by Shetty *et al.*, which uses a graduated scale and is mathematically correct. The limitation of this technique was that it could not be used in a patient with a loss of ear as spring bow had to be stabilized on it.<sup>[12]</sup>
6. Placing iris disc on a custom made ocular prosthesis – The technique mentioned by the authors makes use of stock eye matching with the contralateral eye of the patient is selected, of which the iris portion is removed, and the stock eye (without iris) is duplicated as stock tray for impression making which is then poured, the wax pattern is made. After the dewaxing procedure, the removed iris is then placed in the dewaxed flask and then it is cured. As in this technique, the prefabricated prosthesis is modified to a custom made fit and esthetics. This could overcome the shortcomings of the previous techniques of poor fit, inadequate movement, and complex painting procedures and techniques.<sup>[13]</sup>
7. Using a grid attached to a spring bow – Bilateral symmetry is crucial in iris positioning as it is for any other prosthodontic procedures. In this technique, facebow is aligned parallel to horizontal reference plane, and customized scale along with graph grid helps inaccurate transfer of iris position by obtaining interpupillary line. This technique uses the customized scale and the graph grid. It is less time consuming, requires minimal skills,

no assistance is required, and can be used multiple times in different patients. Although this technique has a limitation of the selection of color and size of the iris.<sup>[14]</sup>

8. Dynamic pupil using liquid crystal display (LCD) – This technique uses the principal of LCD technology as a color spatial light modulator to control the pupil size. In this, a small LCD is positioned over an iris image, in which ring-shaped pixels will appear black or transparent depending on the ambient light to stimulate the dynamic pupil. The LCD could be mass produced, and only the final steps for the integration of the iris would be necessary before assembly using standard processing steps. This technique will have a very positive effect on the quality of life of the patient.<sup>[15]</sup>

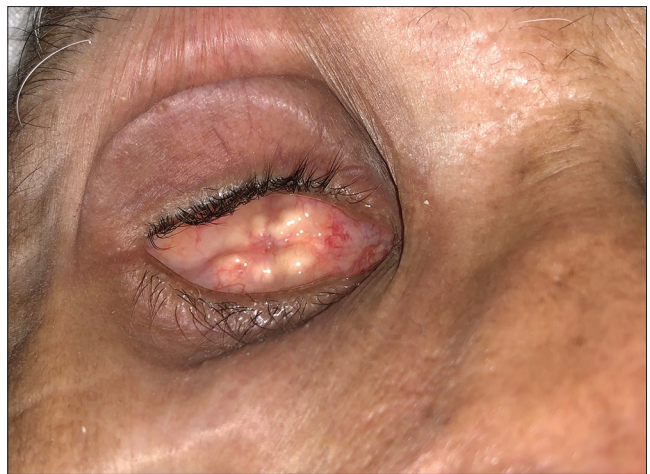

Figure 1: Preoperative

### CASE REPORT

A 60-year-old male patient reported to the Department of Prosthodontics and Crown and Bridge, Subharti Dental College and Hospital, Swami Vivekanand Subharti University, Meerut (Uttar Pradesh) with the chief complaint of ill-fitting artificial right eye. The patient was a prosthetic eye wearer for 20 years. Examination revealed enucleated socket with no signs of inflammation [Figure 1]. Custom-made ocular prosthesis has many advantages when compared to stock eye prosthesis such as better adaptation and characterization of the eye. There are various methods to locate iris. In the present case, two methods were chosen to locate iris for customized ocular prosthesis to find out which was more accurate, simple, and expectable method.

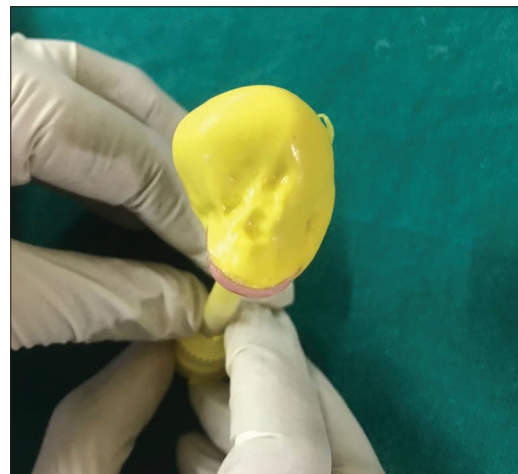

Figure 2: Impression using light bodied impression material

### PROCEDURE

The patient was seated in an upright position to allow the tissues involved in the defect to be recorded in their natural shape. An impression of the orbital socket was made with light body addition silicone impression material (Aquasil and Dentsply) using patients stock eye prosthesis as tray [Figure 2]. The patient was instructed to close his eye so that the excess material escapes through perforations in the tray. The patient was asked to do various eye movements in the following order – Laterally, up and down and circular motion till the material sets. Impression was poured using two-pour techniques. The cast was retrieved from the impression and the wax pattern was fabricated. The wax pattern was smoothed to remove any sharp ridges and undesirable irregularities and then polished. Wax try in was done to check the fullness [Figure 3]. Iris from stock eye was color matched with natural eye and used for iris disc placement. Two different methods were used for locating and positioning of iris disc.

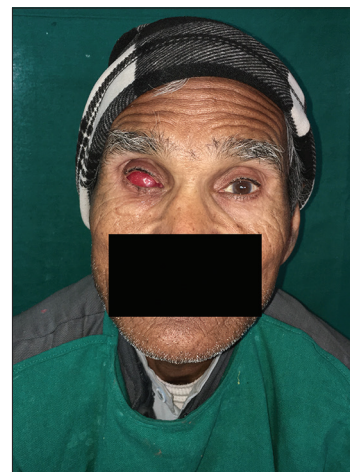

Figure 3: Wax try-in

### METHOD 1 – USING TRUBYTE TOOTH INDICATOR

Graph paper was attached to trubyte tooth indicator. Markings were made on template on X-axis from A to H

from midline and on the left side from A to H. similarly from 1 to 7 on Y-axis and 1–7 on the left side. The distance between each marking was 1 cm on both X and Y axis. A vertical midline was marked passing through the forehead crease, glabella, tip of the nose, and chin. The distance from the right eye medial canthus to the midline and left eye medial canthus to the midline was measured. The patient was asked to gaze straight at an object kept 4 feet away. Vertical lines were marked coinciding with the medial and distal extremities of the iris of the natural eye. Similarly, the horizontal lines referring to the center, inferior and superior limits of the iris were marked. The facial markings were coinciding with the trubyte marking by placing it on the patient's face. These markings were transported to the side of the defect [Figure 4]. These markings were transferred to the sculptured wax pattern and the iris disc was attached to it. The advantage of using trubyte tooth indicator over graphic grid was that it was rigid which provided support to the graph paper and centralization was much easier. Wax conformer with the stock iris was tried in. After the final adjustments and ascertaining, patient satisfaction, the wax conformer was processed in a conventional manner. The final prosthesis finishing and polishing was done.

#### METHOD 2 – USING HANAU VIDE VIEW SPRING BOW<sup>[12]</sup>

U-shaped frame of Hanau spring bow (Hanau spring bow, whip Mix Corporation) was reversed such that the orbital pointer was stabilized on the lower border of the left ala of the nose. This standardized and stabilized the facebow and acted as the third point of reference. Transfer clamp assembly of the facebow was attached to the reversed facebow frame. Edentulous facebow fork of the Hanau facebow was selected, and the recorded measurements were attached on to the clamp assembly. Metal, graduated scale was cut to the exact width of the facebow fork frame and was attached horizontally to the edentulous facebow fork with double-sided tape. Position of the iris was marked based on the markings on the scale [Figure 5]. Wax conformer with the stock iris was tried in. After the final adjustments and ascertaining, the patient's satisfaction, the wax conformer was processed in a conventional manner. Final prosthesis finishing and polishing was done.

Both the prostheses were tried by the patient; however, the prosthesis with trubyte tooth indicator method showed a better orientation of the iris with respect to the contralateral eye [Figures 6 and 7]. The method was easier and did not require elaborate equipment which needed to be adjusted. In addition, the time taken was much less



Figure 4: Iris location using trubyte tooth indicator



Figure 5: Iris location using Hanau wide view spring bow

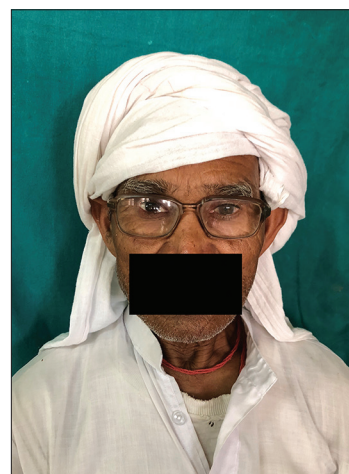

Figure 6: Final prosthesis using trubyte tooth indicator

compared to the other methods. The matching of the color of iris with respect to the contralateral eye was excellent and the patient was satisfied with the outcome. The method of the prosthesis insertion and removal was taught to the patient. The follow-up evaluation was carried out once a week for 1<sup>st</sup> month.

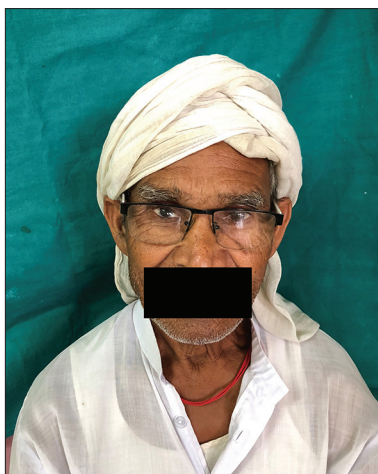

Figure 7: Final prosthesis using Hanau wide view spring bow

## DISCUSSION

For natural color, contour and orientation, custom-made ocular prosthesis is the best treatment option. Different methods are available for iris replication. Different methods have been suggested to determine the size and position of the iris by visual judgment, using pupilometer, or other calipers, graphic grid method. In this case report, two different iris location methods are used and evaluated. The method described in this article involves trubyte tooth indicator and face bow. Trubyte tooth indicator is used for the selection of teeth in patients who are completely edentulous. It is a rigid frame which had markings both horizontally and vertically which help us to transfer the orientation of natural eye to prosthetic eye. Rigid, less mobility than graphic grid, straight forward, and cost-effective method which results in a more esthetically pleasing and accurate prosthetic outcome.

## CONCLUSION

The literature provides several techniques to duplicate the iris and to get better results esthetically. Incorporation of LCD in the prosthetic eye will provide a dynamic pupil and will certainly prove to give a better quality of life to the patient. However, to duplicate the exact iris, requires skilled clinician and an eye for precision to have esthetic and predictable outcome.

### Declaration of patient consent

The authors certify that they have obtained all appropriate

patient consent forms. In the form the patient(s) has/have given his/her/their consent for his/her/their images and other clinical information to be reported in the journal. The patients understand that their names and initials will not be published and due efforts will be made to conceal their identity, but anonymity cannot be guaranteed.

### Financial support and sponsorship

Nil.

### Conflicts of interest

There are no conflicts of interest.

## REFERENCES

1. The glossary of prosthodontic terms. *J Prosthet Dent* 2005;94:10-92.
2. Naveen HC, Porwal A, Nelogi S. Prosthetic rehabilitation of phthisis bulbi by digital imaging technique – A case report. *Cont Lens Anterior Eye* 2010;33:231-4.
3. Goiato MC, Bannwart LC, Haddad MF, dos Santos DM, Pesqueira AA, Miyahara GI. Fabrication techniques for ocular prostheses – An overview. *Orbit* 2014;33:229-33.
4. Fernandes AU, Goiato MC, Batista MA, Santos DM. Color alteration of the paint used for iris painting in ocular prostheses. *Braz Oral Res* 2009;23:386-92.
5. Goiato MC, Moreno A, dos Santos DM, de Carvalho Dekon SF, Pellizzer EP, Pesqueira AA. Effect of polymerization and accelerated aging on iris color stability of ocular prosthesis. *Cont Lens Anterior Eye* 2010;33:215-8.
6. Kale E, Meşe A, Izgi AD. A technique for fabrication of an interim ocular prosthesis. *J Prosthodont* 2008;17:654-61.
7. Reis RC, Brito e Dias R, Mesquita Carvalho JC. Evaluation of iris color stability in ocular prosthesis. *Braz Dent J* 2008;19:370-4.
8. Chung AK. Artificial iris rings. *Eye (Lond)* 2008;22:1203-4.
9. Saxena AM, Singh SP, Goswami R. Prosthetic rehabilitation by a custom made scleral shell prosthesis. *MP State Dent J* 2015;4:16-8.
10. Guttal SS, Patil NP, Vernekar N, Porwal A. A simple method of positioning the iris disk on a custom-made ocular prosthesis. A clinical report. *J Prosthodont* 2008;17:223-7.
11. Chihargo and Syafrinani. CRC1: Iris positioning technique by using optical vernier interpupillary distance ruler on the custom ocular prosthesis. *J Indian Prosthodont Soc* 2018;18:S35.
12. Shetty PP, Chowdhary R, Yadav RK, Gangaiah M. An iris positioning device and centering approach: A technique. *J Prosthet Dent* 2018;119:175-7.
13. Kumar P, Aggrawal H, Singh RD, Chand P, Jurel SK, Alvi HA, *et al.* A simplified approach for placing the iris disc on a custom made ocular prosthesis: Report of four cases. *J Indian Prosthodont Soc* 2014;14:124-7.
14. Chamaria A, Aras MA, Chitre V, Costa GCD. Iris positioning using a grid attached to a spring bow for a custom ocular prosthesis. *J Clin Diagn Res* 2017;11:ZD12-3.
15. Lapointe J, Durette JF, Harhira A, Shaat A, Boulos PR, Kashyap R. A 'living' prosthetic iris. *Eye (Lond)* 2010;24:1716-23.