

Contents lists available at [ScienceDirect](http://www.sciencedirect.com)

## International Journal of Surgery Case Reports

journal homepage: [www.casereports.com](http://www.casereports.com)

# Management of giant inferior triangle lumbar hernia (Petit's triangle hernia): A rare complication following delayed breast reconstruction with extended latissimus dorsi myocutaneous flap



Alexandre Mendonça Munhoz<sup>a,\*</sup>, Eduardo Montag<sup>b</sup>, Eduardo Gustavo Arruda<sup>b</sup>, Gustavo Sturtz<sup>c</sup>, Rolf Gemperli<sup>d</sup>

<sup>a</sup> Hospital Sírio Libanês, São Paulo, Brazil

<sup>b</sup> Cancer Institute of São Paulo, São Paulo, Brazil

<sup>c</sup> Hospital das Clínicas University of São Paulo, Brazil

<sup>d</sup> University of São Paulo, São Paulo, Brazil

## ARTICLE INFO

## Article history:

Received 24 September 2013

Received in revised form 29 January 2014

Accepted 26 March 2014

Available online 2 April 2014

## Keywords:

Breast reconstruction

Hernia

Lumbar triangle

Myocutaneous flap

Complication

## ABSTRACT

**INTRODUCTION:** Lumbar triangle hernia after breast reconstruction with latissimus dorsi flap (LDMF) is a very rare complication and few cases were previously described. Muscle mobilization and iatrogenic fascia defect are related etiologic factors.

**PRESENTATION OF CASE:** The authors describe a rare case of lumbar hernia in a 58-year-old woman who underwent delayed left breast reconstruction with LDMF. Two months after surgery, a progressive symptomatic lower left lumbar bulge was observed. The CT scan confirmed the diagnosis and delineated an 18 cm lumbar defect filled with lower and large bowel. At operation, the defect was exposed and the hernia sac reduced. In order to obtain stability, the remained local muscle and fascia flaps were mobilized into the defect. Additional strength was achieved with a two-layer closure of prosthetic mesh (intra/extra peritoneal). The patient is currently in the 10th postoperative year of hernia repair and satisfactory lumbar wall contour was achieved. Neither the recurrence of lumbar hernia nor symptoms compliance was noted.

**DISCUSSION:** Lumbar hernia is an uncommon complication of LDMF harvest. Although it is a rare disease, general and plastic surgeons must be on alert to avoid complications and misdiagnosis. Seroma differential diagnosis is important in order to avoid bowel perforation due to aspiration. Defect reconstruction is necessary with a muscular and fascia flaps mobilization and synthetic mesh in order to obtain a stable repair.

**CONCLUSION:** The knowledge of this rare post-operative complication following delayed breast reconstruction is crucial to its surgical management. Early surgical intervention is warranted in order to avoid severe complications.

© 2014 The Authors. Published by Elsevier Ltd. on behalf of Surgical Associates Ltd. This is an open access article under the CC BY-NC-ND license (<http://creativecommons.org/licenses/by-nc-nd/3.0/>).

## 1. Introduction

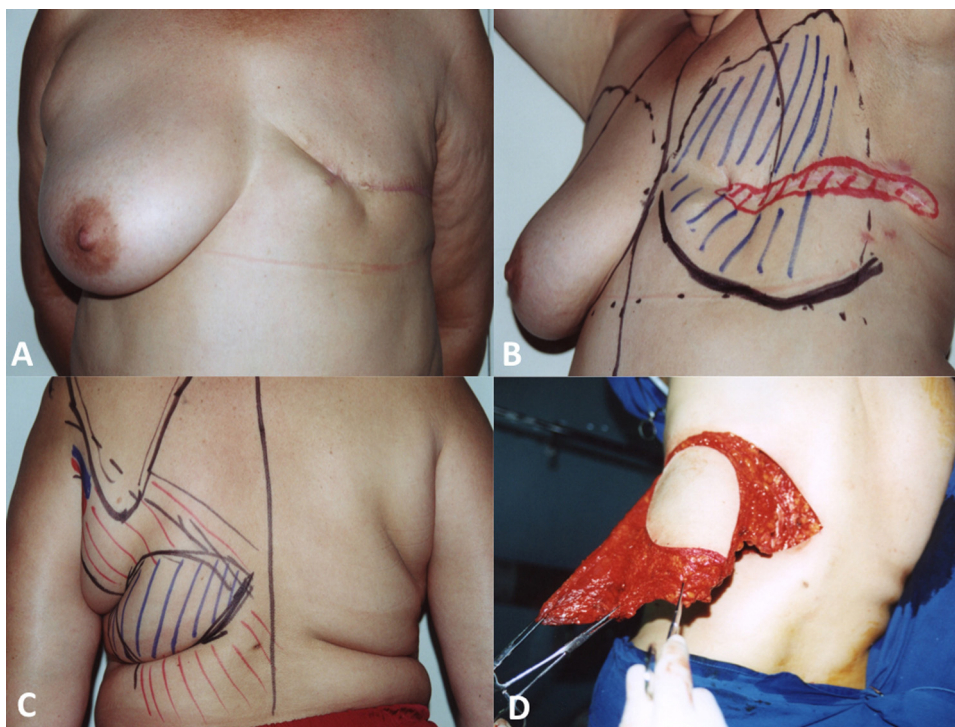
Breast reconstruction with latissimus dorsi musculocutaneous flap (LDMF) remains a useful option for patients seeking autogenous breast reconstruction.<sup>1–3</sup> Although the technique is a reliable procedure, some donor site complications have been mentioned. Resultant scar problems, seroma collection and muscular functional impairment are usually observed.<sup>2,3</sup>

Lumbar hernias are rare posterolateral abdominal wall hernias and usually can protrude through the superior or inferior triangle.<sup>4–6</sup> Lumbar hernia after breast reconstruction with LDMF is a very rarely complication and there are few previous case reports described.<sup>9–12</sup> In addition, the great part of the cases are related to the superior lumbar triangle and cases concerning the inferior triangle hernia are related to orthopedic surgery when a piece of iliac crest is taken for a graft. Up to now there are few previous report regarding the surgical management of a giant inferior triangle lumbar hernia following delayed LDMF breast reconstruction.<sup>11</sup>

Thus, the authors described a giant inferior triangle lumbar hernia following a LDMF harvest. The lumbar region anatomy, the hernia diagnosis, the importance of differential diagnosis with seroma and the surgical management are discussed. The case illustrates several points that may be useful for general and plastic surgeons who may encounter this condition.

\* Corresponding author at: Division of Plastic Surgery – Hospital Sírio-Libanês, Rua Mato Grosso, 306 cj.1705-1706 ZIP: 01239-040 Sao Paulo, SP – Brazil. Tel.: +55 11 32551769x1760; fax: +55 11 32551769x1760.

E-mail addresses: [munhozalex@uol.com.br](mailto:munhozalex@uol.com.br), [alexandremunhoz@hotmail.com](mailto:alexandremunhoz@hotmail.com) (A.M. Munhoz).



**Fig. 1.** (A–D) Preoperative view/surgical planning of a delayed left breast reconstruction with left LDMF and silicone implant in a 58-year-old patient (A–C). Intraoperative view the left LDMF before transposition to the left anterior thorax (D).

## 2. Clinical case

A 58-year-old obese white woman underwent delayed left breast reconstruction with left LDMF flap and silicone implant. The patient was a non-smoker and had no previous surgeries besides the left radical mastectomy and abdominal dermolipectomy, two and ten years before respectively (Fig. 1a–d). Two months after surgery, a progressive symptomatic lower left lumbar bulge was observed. The patient described as “suddenly swelling” after physical exercising. She also complained of local pain and gradual increase in size with cough. Lumbar mass reducibility as well as expansion after *Valsalva* maneuver were observed during the physical exam.

At this time, a late lumbar seroma was suspected. In spite of this, needle puncture was avoided and a lumbar computerized tomography (CT scan) was performed. The CT scan confirmed the diagnosis of lumbar hernia and delineated an 18 cm triangle lumbar defect with lower and large bowel filled hernia sac. A severe attenuation of the surrounding lumbodorsal fascia and musculature was also observed (Fig. 2a–c).

### 2.1. Surgical technique

The patient was placed in the right lateral decubitus position and general anesthesia was used. The previous LDMF scar was incised down to the thoracic wall and external abdominal oblique fascia. Dissection continued down to the lumbar region. The hernia sac containing the remaining lumbar fascia, peritoneum and small and large bowel, was dissected free from the adjacent thoracic wall structures (Fig. 2d).

The defect was exposed and the hernia sac reduced. In order to obtain stability at the lumbar region, the remained local muscle and fascia flaps were mobilized into the defect. Additional strength was achieved with a two-layer closure of prosthetic mesh. In the deep layer (intra-peritoneal), the sheet of polypropylene

mesh (15 cm × 15 cm) is sutured with heavy running monofilament suture to the defect borders. The second layer is a running reinforcing suture of the sheet of mesh (25 cm × 25 cm) to the remaining transverses abdominis and internal oblique muscles, costal cartilages and iliac crest (Fig. 3a–b).

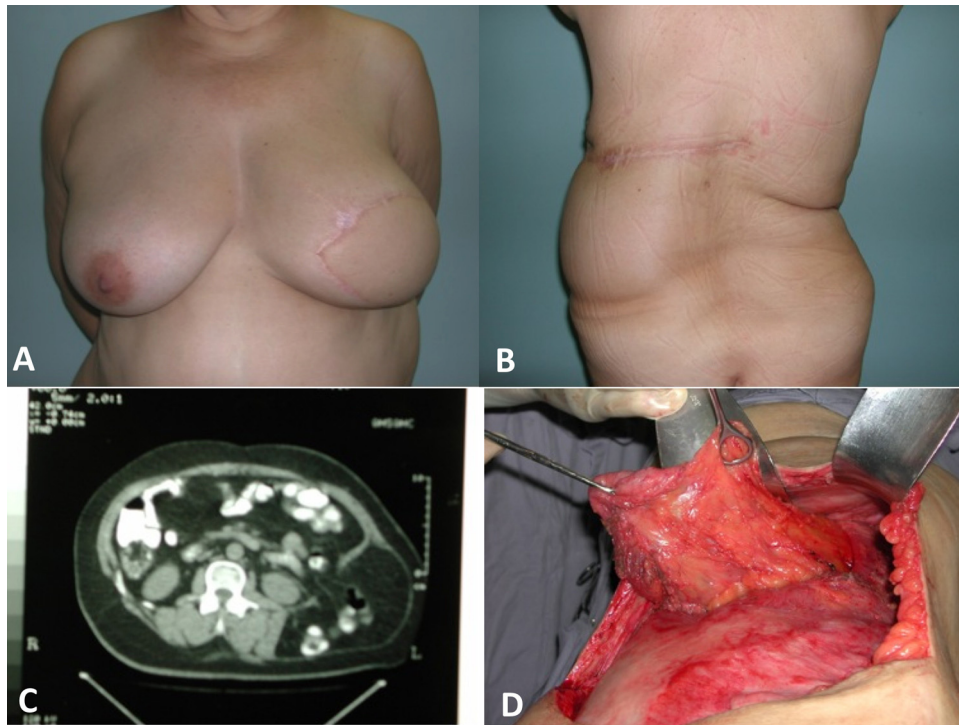
### 2.2. Postoperative period/outcome

Satisfactory lumbar and abdominal wall contour were achieved (Fig. 3c–d). The patient is currently in the 10th postoperative year of lumbar hernia correction and the breast reconstruction was finished with nipple-areola complex reconstruction. Neither the recurrence of lumbar hernia nor symptoms compliance was noted. CT 12th month after hernia repair showed resolution of the hernia (Fig. 4).

## 3. Discussion

The latissimus dorsi is an extensive triangular muscle and arises from spinous process of the lower six thoracic and lumbar vertebrae, sacrum and iliac crest. This region is subdivided into a superior triangle which is an inverted triangle bounded at the base by the 12th rib and lower edge of the serratus muscle; the anterior by the internal oblique muscle; the posterior side by the sacrospinal muscle; the floor is transversalis fascia and the roof by external oblique and latissimus dorsi. The inferior lumbar triangle is bordered by the crest of the iliac bone at the base, the latissimus dorsi muscle medially, the external oblique muscle laterally, and the floor is formed by the internal oblique muscle.<sup>13</sup>

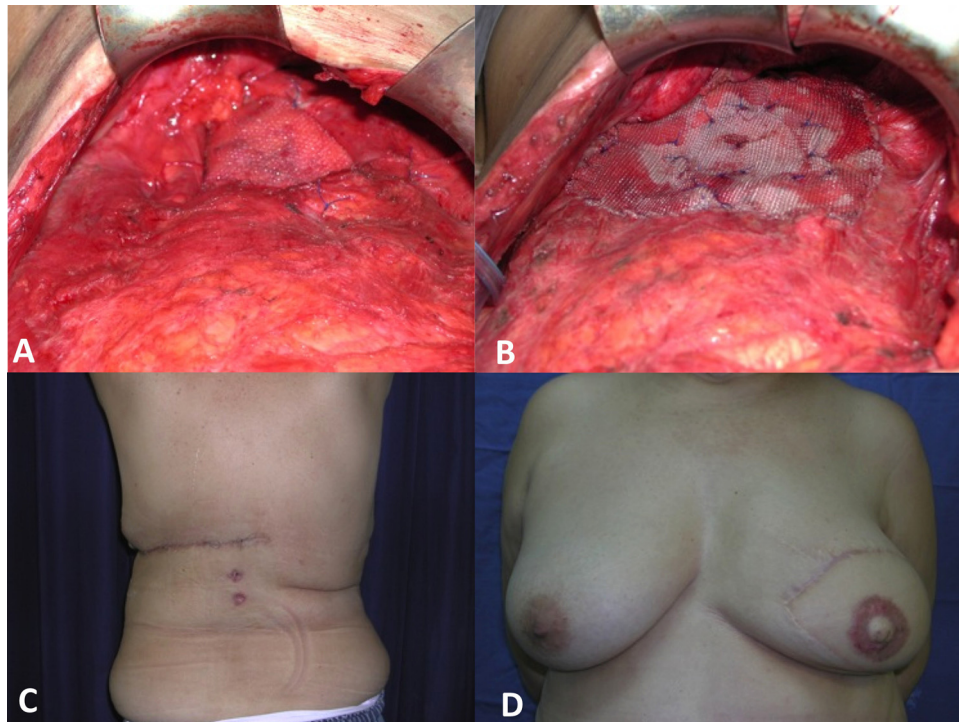
Lumbar hernia is a well-recognized clinical condition.<sup>4–6</sup> Mobilization or weakening of the muscular and fascia components of the superior and inferior lumbar triangles may allow the intra-abdominal components to herniated through the defect. Usually, lumbar hernias occur in two weak areas of the posterolateral



**Fig. 2.** (A–D) Postoperative appearance 2 months following reconstruction (A) showing lower left lumbar bulge (B). Abdominal CT transverse section showing a lumbar hernia and delineated an 18 cm triangle lumbar defect with lower and large bowel filled hernia sac (C). Intraoperative view of the hernia sac containing the remaining lumbar fascia, peritoneum and small and large bowel dissected free from the adjacent thoracic wall structures (D).

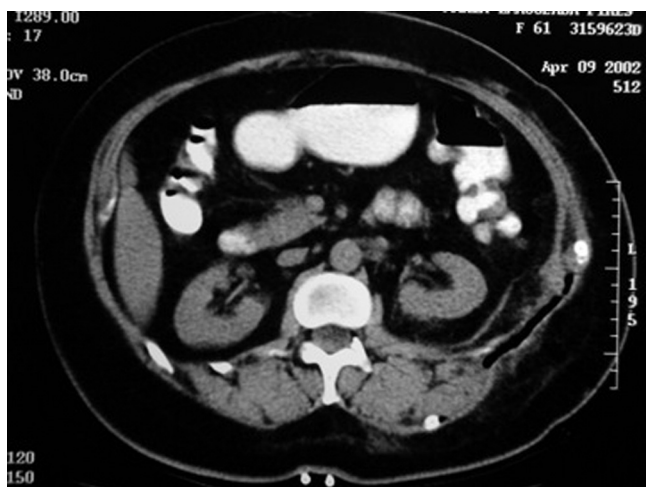
abdominal wall: the superior lumbar triangle of *Grynfeltt*, which is a more frequent site, and the inferior lumbar triangle of *Petit*.<sup>4–6</sup> Etiologic factors for lumbar hernia include congenital defects, lumbar trauma and idiopathic spontaneous herniation.<sup>4–8</sup>

Additionally, incisional hernias following flank surgery such as iliac crest bone harvest and kidney surgery are previous reported. Besides the muscular and fascia anatomical defect, the subcostal nerve (T12) division may results denervation atrophy



**Fig. 3.** (A–D) Intraoperative view of the lumbar region. Strength was achieved with a two-layer closure of prosthetic mesh. In the deep layer (intra-peritoneal), the sheet of polypropylene mesh (15 cm × 15 cm) is sutured to the defect borders (A). The second layer is a running reinforcing suture of the sheet of mesh (25 cm × 25 cm) to the remaining transverses abdominis and internal oblique muscles, costal cartilages and iliac crest (B). Postoperative appearance 2 months following hernia repair showing satisfactory contour (C). The patient is currently in the 10th postoperative year of lumbar hernia correction and the breast reconstruction (D).





**Fig. 4.** Abdominal CT transverse section after hernia repair showed resolution of the left lumbar hernia through inferior triangle (Petit's).

of abdominal wall musculature and occasional development of hernia.<sup>8</sup>

Lumbar hernia following LDMF harvest is rarely described and is a very unusual complication after breast reconstruction.<sup>9–12</sup> In addition, there are no previous report describing a giant inferior triangle lumbar hernia with a 10 cm lumbar defect with lower and large bowel filled hernia sac following delayed LDMF breast reconstruction.

First described in 1985 by Moon and Dowden, the authors reported a small left lumbar hernia in 53-year-old patient who undergone a left LDMF breast reconstruction.<sup>9</sup> They pointed out some risk factors including chronic bronchitis and heavy lifting. Mickel et al. described a right lumbar hernia followed a delayed bilateral breast reconstruction.<sup>11</sup> The authors emphasized the differential diagnosis with lumbar seroma and the importance of imaging scan of the lumbar region before lumbar aspiration. Similarly, Salimbeni described a case and suggest the use of a stethoscope in order to diagnosis the colon herniation before lumbar needle aspiration.<sup>12</sup>

The clinical signs frequently presents as fullness in the lumbar region after 1–8 months after LDMF harvest. Early symptoms are probably related to muscular or fascia defect. In the subcostal nerve division the symptoms may occur later due muscular atrophy period. Swelling and pain over the mass are also described as the main symptoms. The hernia may contain retro-peritoneal fat, kidney, and colon. In this situation, lumbar seroma may present similar signs and differential diagnosis is advisable in order to avoid bowel rupture due needle aspiration. In fact, the expansion of the lumbar mass with valsalva maneuver and the presence of bowel sounds are important physical signs and must be investigated. Imaging exams such as lumbar ultra-sound or CT scan are effective tools in terms of diagnosis and surgical planning.

An adequate harvesting of LDMF is important in order to avoid this complication. The floor of the lumbar region is not a stable structure and is constituted of transversalis and thoracolumbar fascia and transversus muscle.<sup>13</sup> Mickel et al. suggest to dissect along the deep surface of LDMF first and to transect the aponeurosis from this deeper plane to prevent compromising the floor.<sup>11</sup>

Surgical repair is advised by some authors in order to prevent some serious complications.<sup>4,5,11</sup> Sometimes lumbar hernias can progress to incarceration, posterior strangulation and consequently exposure of the peritoneal cavity and the remained subcutaneous tissue to enteric bacteria.<sup>11</sup> Care should be taken in entering the

abdomen through the thin hernia sac in order to avoid injury to the underlying bowel.

Concerning the type of surgical repair, there is no consensus procedure in the previous reports. In small defects with enough remaining muscular and fascia adjacent tissues, a mobilization of local tissue is sufficient in order to obtain an adequate closure. Bolquier et al. in 1991, described 15 cases of lumbar hernia after urologic surgery that were repaired by plicature the outer borders of muscle and fascia together.<sup>14</sup>

For moderate and severe defects, additional reinforcement is achieved with the use of prosthetic mesh. In these cases, the use of two-layer mesh with non-absorbable sutures is advocate in order to prevent further weakening and recurrence.

Recently, endoscopic techniques have been indicated in various abdominal and dorsal wall hernias including lumbar hernia.<sup>15</sup> In fact, some technical reports including laparoscopic or retroperitoneoscopic tension-free repair are observed in the literature with promising results.<sup>15,16</sup> The positive aspects of an endoscopic approach, like less pain, small wound and shorter hospital stay, it gives us excellent operative view. Obregón et al. presented the first description of laparoscopic surgery to treat a non-complicated superior lumbar hernia resulting from the creation of an enlarged LDMF for breast reconstruction following radical mastectomy.<sup>16</sup> According to the authors, the laparoscopic approach substantially reduced the risks associated with open surgery, shortened length of hospital stay and time to recovery and obtained better esthetic outcome. Thus, the authors pointed out that laparoscopic surgery may be considered as a feasible therapeutic option for non-complicated superior lumbar hernias secondary to a LDMF.

In our case, the defect was exposed and the hernia sac reduced. In order to obtain stability at the lumbar region, the remained local muscle and fascia flaps were mobilized into the defect and a two-layer closure of prosthetic mesh was performed. The patient is currently in the 10th postoperative year of lumbar hernia correction with a satisfactory lumbar wall contour. Neither the recurrence of lumbar hernia nor symptoms compliance was noted.

Lumbar hernia is a very rare complication following LDMF harvest and seroma differential diagnosis is crucial in order to avoid bowel perforation. Although it is a rare disease, general and plastic surgeons must be on alert to avoid complications and misdiagnosis. Defect reconstruction should be individualized and sometimes a muscular and fascia flaps mobilization and synthetic mesh is necessary in order to obtain a stable repair.

#### Conflict of interest

We have no conflict of interest, financial and personal relationships with other people or organisations that could inappropriately influence (bias) our present work.

#### Funding

We have no sources of funding and sponsor for the present research.

#### Ethical approval

The present case report was approved by Plastic Surgery Department of the Hospital das Clínicas of the University of São Paulo.

#### Author contribution

Alexandre Mendonça Munhoz: study concept or design, data collection, data analysis or interpretation, writing the paper. Eduardo Montag: data collection, data analysis. Eduardo Gustavo

Arruda: data collection. Gustavo Sturtz: writing the paper, data collection. Rolf Gemperli: data analysis, interpretation.

### Consent

Written informed consent was obtained from the patient for publication of this case report and accompanying images.

### References

1. Bostwick III J, Nahai F, Wallace JG, Vasconez LO. Sixty latissimus dorsi flaps. *Plast Reconstr Surg* 1979;**63**:31–7.
2. Munhoz AM, Montag E, Arruda E, Okada A, Brasil JA, Gemperli R, Filassi JR, Ferreira MC. Immediate locally advanced breast cancer and chest wall reconstruction: surgical planning and reconstruction strategies with extended V-Y latissimus dorsi myocutaneous flap. *Plast Reconstr Surg* 2011;**127**(6):2186–97.
3. Chang DW, Youssef A, Cha S, Reece GP. Autologous breast reconstruction with the extended latissimus dorsi flap. *Plast Reconstr Surg* 2002;**110**(3):751–9.
4. Lillie GR, Deppert E. Inferior lumbar triangle hernia as a rarely reported cause of low back pain: a report of 4 cases. *J Chiropr Med* 2010;**9**(2):73–6.
5. Ponka JL. Lumbar hernia. In: Ponka JL, editor. *Hernias of the abdominal wall*. Philadelphia: Saunders; 1980. p. 465–78.
6. Swartz WT. Lumbar hernias. *J Ky State Med Assoc* 1954;**52**:673–8.
7. Hasaniya NW, Lee YM, Crandall DB. Spontaneous inferior lumbar hernia of Petit: a CT assisted diagnosis. *Contemp Surg* 1993;**43**:363–7.
8. Sutherland RS, Gerow RR. Hernia after dorsal incision into lumbar region: a case report and review of pathogenesis and treatment. *J Urol* 1995;**153**:382–7.
9. Moon HK, Dowden RV. Lumbar hernia after latissimus dorsi flap. *Plast Reconstr Surg* 1985;**75**:417–21.
10. Babayan R, Mittelhauser G. Lumbalhernie nach transposition des musculus latissimus dorsi. *Chirurg* 1986;**57**:411–5.
11. Mickel TJ, Barton FE, Rohrich RJ, Daniel LB, Conner WC. Management and prevention of lumbar herniation following a latissimus dorsi flap. *Plast Reconstr Surg* 1999;**103**:1473–8.
12. Salimbeni G. Lumbar hernia after latissimus dorsi flap dissection. *Plast Reconstr Surg* 2000;**105**:1572–8.
13. Moreno-Egea A, Baena EG, Calle MC, Martínez JA, Albasini JL. Controversies in the current management of lumbar hernias. *Arch Surg* 2007;**142**:82–8.
14. Bolkier M, Moskovitz B, Ginesin Y, Levin DR. An operation for incisional lumbar hernia. *Eur Urol* 1991;**20**(1):52–5.
15. Nam SY, Kee SK, Kim JO. Laparoscopic transabdominal extraperitoneal mesh repair of lumbar hernia. *J Korean Surg Soc* 2011;**81**:74–7.
16. Obregón L, Ruiz-Castilla M, Binimelis MM, Guinot A, García V, Puig O, Barret JP. Laparoscopic repair of non-complicated lumbar hernia secondary to a latissimus dorsi flap. *J Plast Reconstr Aesthet Surg* 2013;**31**:1748–9.

### Open Access

This article is published Open Access at [scimedirect.com](http://scimedirect.com). It is distributed under the [IJSCR Supplemental terms and conditions](#), which permits unrestricted non commercial use, distribution, and reproduction in any medium, provided the original authors and source are credited.