



# Silicone stent placement for tracheal stenosis induced by a giant goiter due to Graves' disease: a case report

Mariko Misaki<sup>1,2</sup>, Naoya Kawakita<sup>1,2</sup>, Tomoyo Hara<sup>3</sup>, Hiroki Yamagami<sup>3</sup>, Taihei Takeuchi<sup>1,2</sup>, Naoki Miyamoto<sup>1,2</sup>, Shinichi Sakamoto<sup>1,2</sup>, Seiya Inoue<sup>1,2</sup>, Masakazu Goto<sup>1,2</sup>, Hiroaki Toba<sup>1,2</sup>, Hiromitsu Takizawa<sup>1,2</sup>

<sup>1</sup>Department of Thoracic, Endocrine Surgery and Oncology, Institute of Health, Biosciences, The University of Tokushima, Tokushima, Japan;

<sup>2</sup>Department of Esophagus, Breast and Thyroid Surgery, Tokushima University Hospital, Tokushima, Japan; <sup>3</sup>Department of Hematology, Endocrinology and Metabolism, Tokushima University Graduate School of Biomedical Sciences, Tokushima, Japan

*Contributions:* (I) Conception and design: M Misaki; (II) Administrative support: H Takizawa; (III) Provision of study materials or patients: M Misaki, N Kawakita; (IV) Collection and assembly of data: M Misaki; (V) Data analysis and interpretation: M Misaki; (VI) Manuscript writing: All authors; (VII) Final approval of manuscript: All authors.

*Correspondence to:* Mariko Misaki, MD, PhD. Department of Thoracic, Endocrine Surgery and Oncology, Institute of Health, Biosciences, The University of Tokushima, 3-18-15, Kuramoto-cho, Tokushima, 770-8509, Japan; Department of Esophagus, Breast and Thyroid Surgery, Tokushima University Hospital, Kuramoto-cho, Tokushima, Japan. Email: aoyama.mariko@tokushima-u.ac.jp.

**Background:** Although thyroid tumors with tracheal stenosis are occasionally encountered, severe tracheal stenosis caused by benign thyroid tumors is rare. We herein describe a case in which a silicone tracheal stent was placed for severe tracheal stenosis induced by a giant goiter due to Graves' disease.

**Case Description:** A 93-year-old woman had been receiving thiamazole treatment for Graves' disease with a thyroid goiter for 32 years. She emergently presented to the hospital with sudden difficulty breathing and the temporary loss of consciousness. Although marked stridor was heard, the patient's respiratory status was stable in the first visit. Computed tomography revealed a giant thyroid goiter that extended to the mediastinum. The trachea was compressed by the sternal notch and thyroid gland, resulting in severe stenosis, and the tracheal lumen was only 1 mm. Surgical thyroidectomy was expected to be difficult due to the high risk of complications associated with the large size of the goiter and advanced age of the patient. Therefore, we decided to place a tracheal stent. A silicone stent (Dumon tube<sup>®</sup>) was inserted into the site of tracheal stenosis under general anesthesia. After stent placement, respiratory distress symptoms improved, and no complications were observed. Three months after stent placement, the stent opening side was narrowed due to defective granulation and, thus, was cauterized with argon plasma coagulation.

**Conclusions:** We encountered a patient who was treated by tracheal silicone stent placement for severe tracheal stenosis induced by a giant goiter due to Graves' disease. A silicone stent effectively secures the airway for benign thyroid tumors that cause severe airway stenosis.

**Keywords:** Silicone tracheal stent; tracheal stenosis; Graves' disease; goiter; case report

Submitted Dec 05, 2023. Accepted for publication Feb 29, 2024. Published online Apr 17, 2024.

doi: 10.21037/gs-23-499

View this article at: <https://dx.doi.org/10.21037/gs-23-499>

## Introduction

Significant tracheal stenosis in thyroid disease is rare (1). Most cases of severe airway stenosis are caused by malignant thyroid tumors (2); however, benign thyroid tumors may be responsible in rare cases (3,4). Severe airway stenosis is a life-

threatening condition causing respiratory distress and requires immediate action for airway management (5-8). Thyroidectomy is necessary for definitive treatment (5-8). Tracheostomy may also effectively secure the airway (2,9). However, if the thyroid tumor is large, this treatment is difficult (5,6,8,9),

and, thus, alternative strategies to surgical treatment are required (5-7). We herein describe a case in which a giant goiter due to Graves' disease caused severe tracheal stenosis and breathing difficulties. A silicone tracheal stent was placed and the airway was secured. A silicone tracheal stent may seem an effective treatment method for severe airway stenosis caused by benign thyroid tumors. We present this case in accordance with the CARE reporting checklist (available at <https://gs.amegroups.com/article/view/10.21037/gS-23-499/rc>).

## Case presentation

A 93-year-old woman with no medical or family history was diagnosed with Graves' disease and thyroid goiter approximately 32 years ago and had been receiving treatment with thiamazole. Thyroid function was generally controlled by the thiamazole treatment, and no side effects were observed due to methimazole. Although the thyroid goiter gradually increased in size, she had no subjective symptoms, such as difficulty breathing. The patient consulted a surgeon regarding indications for total thyroidectomy five years ago, but did not want to undergo surgery.

At the time of a periodical consultation, a very strong upper respiratory tract stenosis sound was heard. The medical attendant allowed the patient to return home because she was not negatively affected by breathing symptoms. However, after returning home, the patient had difficulty breathing, lost consciousness, and was emergently transported to the hospital. At the time of the transfer, the patient was alert. Blood pressure was

161/85 mmHg, heart rate was 85 beats per minutes with an irregular rhythm, respiratory rate was 20 breaths per minute, body temperature was 36.0 °C, and oxygen saturation was 95% on oxygen at room air. On examination, the entire anterior neck was distended and marked stridor was heard. Laboratory data showed thyroid-stimulating hormone (TSH) 0.02  $\mu$ U/mL (normal 0.65–5.55  $\mu$ U/mL), free triiodothyronine (T3) 4.3 pg/mL (normal 2.30–3.70 pg/mL), and free thyroxine (T4) 0.53 ng/dL (normal 0.95–1.75 ng/dL). The TSH receptor antibody was 76.3 IU/mL (normal <2.0 IU/mL). Computed tomography (CT) revealed an enlarged thyroid gland containing many nodules. The enlarged thyroid goiter extended caudally to the caudal aortic arch. At the level of the upper sternum, the trachea was compressed by the sternum and thyroid goiter and was severely narrowed with a tracheal lumen of only 1 mm. The total length of the tracheal stenosis was 1.3 cm, and the oral side of the tracheal stenosis site was 5.5 cm from the vocal cords (*Figure 1A,1B*). Due to the advanced age of the patient, thyroidectomy was considered to be too invasive. Emergency tracheostomy was also difficult due to the high risk of complications associated with the large size of the goiter. Therefore, we decided to place a tracheal stent at the site of tracheal stenosis. Since only a silicone stent is covered by the national health insurance system for airway stenosis caused by benign tumors in Japan, Dumon tube® (HARADA, Japan) made by silicone was selected. Although the trachea was narrowed, the patient could maintain her respiratory status. Therefore, stent placement was performed on a semi-emergency basis. Under general anesthesia, tracheal intubation was performed under a flexible bronchoscope. At the site of tracheal stenosis, the trachea was pressed by the thyroid goiter from the membranous region (*Figure 1C*). However, the bronchoscope was easily passed through. The intubation tube was then removed and a rigid bronchoscope was inserted. The length of tracheal stenosis was measured using CT and transparent images, and the Dumon tube® with an outer diameter of 15 mm and a length of 11 cm was cut to a length of 4 cm and placed under fluoroscopy avoiding the vocal codes. Immediately after tracheal stent insertion, the stent lumen was narrow. However, the stent gradually expanded and a sufficient lumen was confirmed within a few minutes (*Figure 2*). A skin incision was made on the anterior neck at the level of the sternal notch to expose the trachea. To prevent stent migration, the trachea and the stent were directly sutured with 3-0 nylon suture. After tracheal stent placement, stridor disappeared, dyspnea improved, and

### Highlight box

#### Key findings

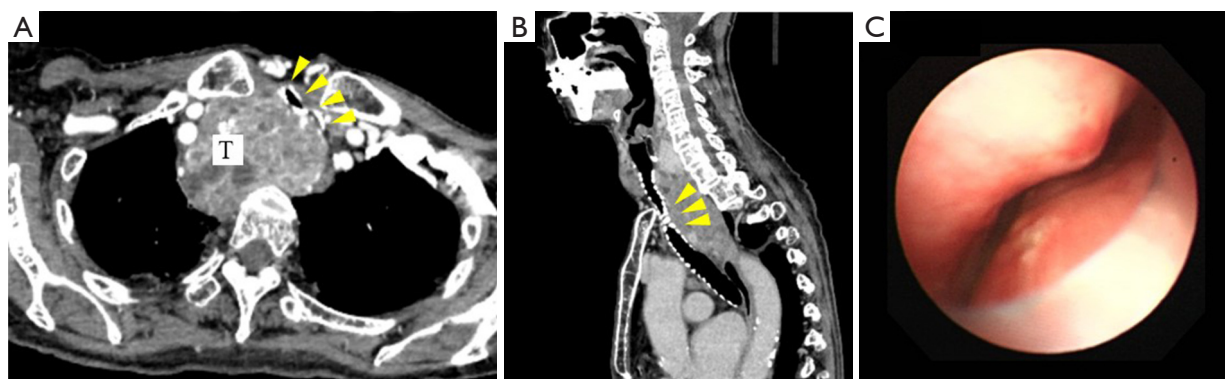
- A silicone tracheal stent effectively secures the airway for benign thyroid tumors that cause severe airway stenosis.

#### What is known and what is new?

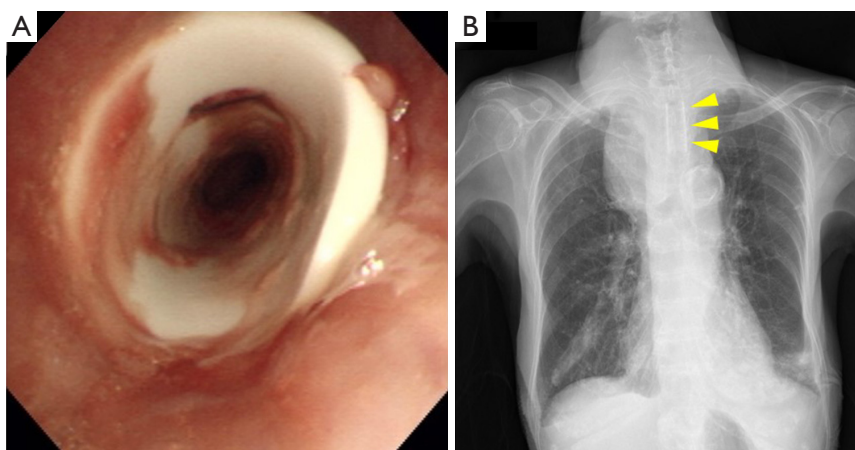
- Thyroid tumors with severe airway stenosis caused by benign thyroid tumors are rare. Silicone tracheal stent placement is considered to effectively secure the airway.
- Silicone stents may be easily repositioned under a bronchoscope and removed after thyroidectomy.

#### What is the implication, and what should change now?

- A silicone tracheal stent may seem an effective treatment method for severe tracheal stenosis caused by benign thyroid tumors.



**Figure 1** Tracheal findings before stent placement. (A) Horizontal section and (B) sagittal section CT shows an enlarged thyroid gland (T). At the level of the upper sternum, the trachea was compressed by the sternum and thyroid goiter, resulting in severe stenosis (yellow triangles). (C) Observation under a bronchoscope. The trachea was compressed by the thyroid goiter. CT, computed tomography.



**Figure 2** Tracheal findings after stent placement. (A) Observation under a bronchoscope. The tracheal lumen was fully opened. (B) Chest X-P. Chest X-P showed that the silicone airway stent expanded sufficiently (yellow triangles).

there were no complications.

At the medical examination one month after stent placement, the patient's respiratory status was stable. Three months after tracheal stent placement, stridor was heard again and the patient had dyspnea. Observations through a flexible bronchoscope revealed that the stent opening side had become narrowed due to defective granulation (*Figure 3A*). Granulation was cauterized with argon plasma coagulation, which resolved narrowing of the stent lumen (*Figure 3B*).

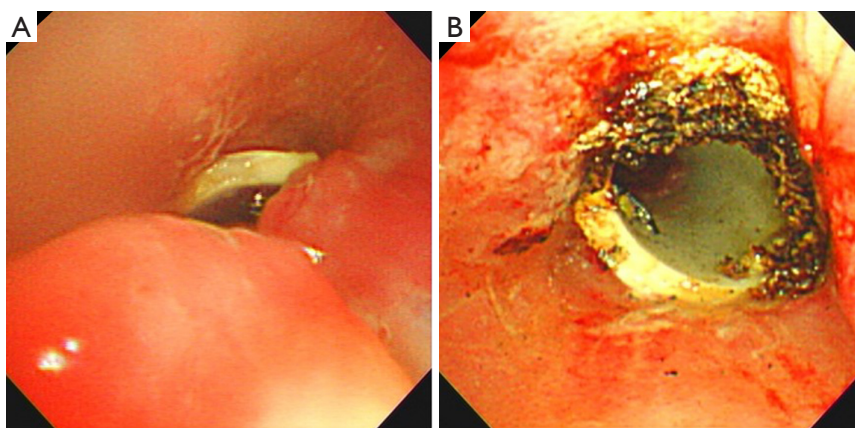
Thereafter, the patient's respiratory condition was stable and she was able to return home. Five months after tracheal stent placement, the patient died of heart failure.

All procedures performed in this study were in

accordance with the ethical standards of the institutional and/or national research committee(s) and with the Helsinki Declaration (as revised in 2013). The publication of this case report and accompanying images was waived from patient consent by the Tokushima University Hospital Institutional Review Board.

## Discussion

Thyroid tumors with severe tracheal stenosis are rare (1). Most cases of tracheal stenosis are caused by malignant thyroid tumors, with an incidence of approximately 6–14% (2). Significant airway stenosis due to benign thyroid tumors is even rarer, with an incidence of



**Figure 3** Observation under a bronchoscope. The stent opening side had become narrowed due to defective granulation, and, thus, it was cauterized with argon plasma coagulation. (A) Before cauterization; (B) after cauterization.

approximately 1–2% (3). Abraham reported that the incidence of upper airway stenosis requiring emergent airway intervention was 0.6% (4).

Patients with a goiter are generally asymptomatic even when it compresses the airway tract and acute respiratory failure secondary to tracheal compression by a goiter is rare (7,8). When the diameter of the trachea is less than 8 mm, exertional dyspnea is observed as the most common symptom (9). It is important to note the risk of breathing difficulty caused by severe airway stenosis, particularly if the goiter extends below the sternum (7-9). The retrosternal space is relatively small, which prevents thyroid expansion and contributes to airway stenosis in patients with a retrosternal or substernal goiter, which is associated with compression and displacement of the trachea, causing respiratory distress (7,8). A number of conditions, such as upper respiratory tract infection, chronic obstructive pulmonary disease, and bleeding into the cystic component of an enlarged thyroid gland, may lead to complete airway obstruction (7). In these cases, immediate action is required for airway management (5,6).

In the present case, since the goiter was substernal and extended into the mediastinum, the trachea became severely narrowed. Furthermore, the airway may have been completely obstructed due to saliva or sputum and the patient lost consciousness.

The most effective method for relieving suffocation is to surgically remove the enlarged goiter, thereby eliminating the airway obstruction (5,6,8,9). However, emergency thyroidectomy in patients with dyspnea may increase the risk of surgical complications, such

as hemorrhage, recurrent laryngeal nerve injury, and hypoparathyroidism (5). Emergency tracheostomy is also an effective alternative strategy to resolve an airway obstruction (2,9). However, when the goiter is very large, it is difficult to reach the trachea and safely perform tracheostomy (9). Furthermore, if tracheal stenosis is located on the caudal side of the neck, it may not be possible to effectively secure the airway. A tracheal stent is a minimally invasive and effective method for securing the airway for severe airway stenosis (2,6,9). In the present case, emergency thyroidectomy was considered to be dangerous due to the high risk of complications associated with the large size of the goiter and advanced age of the patient. Tracheotomy was also difficult due to the size of the goiter and location of tracheal stenosis. Therefore, tracheal airway stent placement was considered the most appropriate treatment to secure the airway in this patient.

There are two types of tracheal stents made of different materials, metal and silicone, and both have advantages and disadvantages (2,6,9). Since silicone stents need to be inserted under a rigid bronchoscope, the procedure is more complicated and difficult than that with metal stents (9). However, silicone stents may be more easily repositioned and removed under a bronchoscope than metallic stents (9). Metallic stents have a stronger expansion ability than silicone stents, and the malposition or migration of stents is unlikely to occur. However, they are difficult to remove (6,9). Granuloma formation is the most common complication that occurs more frequently with metal stents (6,9), and one of the causes of granuloma formation is friction between trachea and stent due to movement of the

stent (9). Extensive migration of airway stent near the vocal cord could cause immediate asphyxia (10). Stent migration is more frequent with silicone stents, with a reported incidence of 25% (10), and measures against migration are necessary. Suture fixation of stents is an effective measure to prevent stents from migrating (11). In the present case, stent migration was prevented by suture fixation.

Moreover, a silicone stent was placed in this case because only a silicone stent is covered by the national health insurance system for airway stenosis caused by benign tumors in Japan. Since CT findings showed severe tracheal stenosis, tracheal intubation and the insertion of a bronchoscope were predicted to be difficult. However, the bronchoscope smoothly passed through the airway stenosis site and was easily replaced with a rigid bronchoscope. Immediately after stent placement, the stent insufficiently expanded and appeared to be narrowed. However, the stent expanded sufficiently over time and the airway lumen was secured. In tracheal stenosis caused by benign thyroid tumors, the tracheal lumen may be able to be widened because these tumors are softer than malignant tumors. Because the patient was extremely old, the radical treatment such as thyroidectomy or radioiodine was not performed. If thyroidectomy is performed, the silicone stent may be removed. A silicone tracheal stent is considered an effective treatment method for tracheal stenosis due to benign thyroid disease to secure the airway in patients unable to undergo emergency surgical thyroidectomy from the perspective of their general condition or complications.

## Conclusions

A case of tracheal stent placement for severe tracheal stenosis induced by a giant goiter due to Graves' disease was presented herein. A silicone tracheal stent may seem an effective treatment method for severe tracheal stenosis caused by benign thyroid tumors.

## Acknowledgments

*Funding:* None.

## Footnote

*Reporting Checklist:* The authors have completed the CARE reporting checklist. Available at <https://gs.amegroups.com/article/view/10.21037/gS-23-499/rc>

*Peer Review File:* Available at <https://gs.amegroups.com/article/view/10.21037/gS-23-499/prf>

*Conflicts of Interest:* All authors have completed the ICMJE uniform disclosure form (available at <https://gs.amegroups.com/article/view/10.21037/gS-23-499/coif>). The authors have no conflicts of interest to declare.

*Ethical Statement:* The authors are accountable for all aspects of the work in ensuring that questions related to the accuracy or integrity of any part of the work are appropriately investigated and resolved. All procedures performed in this study were in accordance with the ethical standards of the institutional and/or national research committee(s) and with the Helsinki Declaration (as revised in 2013). The publication of this case report and accompanying images was waived from patient consent by the Tokushima University Hospital Institutional Review Board.

*Open Access Statement:* This is an Open Access article distributed in accordance with the Creative Commons Attribution-NonCommercial-NoDerivs 4.0 International License (CC BY-NC-ND 4.0), which permits the non-commercial replication and distribution of the article with the strict proviso that no changes or edits are made and the original work is properly cited (including links to both the formal publication through the relevant DOI and the license). See: <https://creativecommons.org/licenses/by-nc-nd/4.0/>.

## References

1. Cady B. Management of tracheal obstruction from thyroid diseases. *World J Surg* 1982;6:696-701.
2. Elhidsi M, Soehardiman D, Wibawanto A, et al. Bronchoscopy Laser and Silicone Y-Stent as Emergency Airway Management in Central Airway Stenosis Due to Secondary Thyroid Carcinoma: A Case Report. *Case Rep Pulmonol* 2022;2022:6338073.
3. Kadhim AL, Sheahan P, Timon C. Management of life-threatening airway obstruction caused by benign thyroid disease. *J Laryngol Otol* 2006;120:1038-41.
4. Abraham D, Singh N, Lang B, et al. Benign nodular goiter presenting as acute airway obstruction. *ANZ J Surg* 2007;77:364-7.
5. Testini M, Logoluso F, Lissidini G, et al. Emergency total thyroidectomy due to non traumatic disease. Experience of

- a surgical unit and literature review. *World J Emerg Surg* 2012;7:9.
6. Zhu Q, Zhou H, Ren G, et al. A new treatment strategy for airway obstruction induced by a giant benign goiter: A case report. *Exp Ther Med* 2023;26:376.
  7. Basoglu M, Ozturk G, Aydinli B, et al. Benign nodular goiter causing airway obstruction. *Eurasian J Med* 2009;41:75-9.
  8. Kakimoto S, Harada Y, Shimizu T. Acute upper airway obstruction by a goiter due to Hashimoto's thyroiditis. *BMJ Case Rep* 2021;14:e245198.
  9. Bhandari A, Wang YH, Lv SX, et al. Novel strategy of stents in thyroid mass: a case series report of managing severely dyspneic patients. *Onco Targets Ther* 2017;10:4997-5004.
  10. Chen DF, Chen Y, Zhong CH, et al. Long-term efficacy and safety of the Dumon stent for benign tracheal stenosis: a meta-analysis. *J Thorac Dis* 2021;13:82-91.
  11. Huang J, Zhang Z, Zhang T. Suture fixation of tracheal stents for the treatment of upper trachea stenosis: a retrospective study. *J Cardiothorac Surg* 2018;13:111.

**Cite this article as:** Misaki M, Kawakita N, Hara T, Yamagami H, Takeuchi T, Miyamoto N, Sakamoto S, Inoue S, Goto M, Toba H, Takizawa H. Silicone stent placement for tracheal stenosis induced by a giant goiter due to Graves' disease: a case report. *Gland Surg* 2024;13(4):578-583. doi: 10.21037/gs-23-499