



Repair of the Posterior Lateral Meniscal Root Tear: Suture Anchor Fixation Through the Outside-In Anterior Cruciate Ligament Reconstruction Femoral Tunnel

Manuel Leyes, M.D., Ph.D., Cesar Flores-Lozano, M.D., Ignacio de Rus, M.D.,
María González Salvador, M.D., Eulogio Martín Buenadicha, M.D., and
Gregorio Villarreal-Villarreal, M.D.

Abstract: Posterior lateral meniscus root tears are defined as tears that occur within 9 mm of the posterior lateral meniscus insertion or as avulsions of the insertion. If root tears are left unrepaired, functional alterations and early degenerative changes occur in the affected compartment. Several surgical techniques have been described to reattach the posterior horn of the lateral meniscus, including transtibial pull-out technique and side-to-side repair technique. This surgical technique reports an alternative way to repair posterior lateral meniscus root tears that are associated with or without an anterior cruciate ligament graft tear. The technique involves the placement of a suture anchor on the lateral meniscus root footprint through the outside-in anterior cruciate ligament femoral tunnel, which minimizes the possibility of iatrogenic lesions and facilitates repair.

A lateral meniscal posterior root (LMPR) tear is defined as a radial rupture in the first 9 mm of the meniscal insertion or the bone and/or soft-tissue avulsion of its insertion.¹ Biomechanically, a root tear behaves as the absence of meniscus, leading to an inability to transform axial loads into tension forces, an increase in morbidity, and the development of early osteoarthritis.² In addition, the LMPR plays an important role in the anterior stability of the tibia and in activities that involve pivoting.^{1,2} In patients who suffer an anterior

cruciate ligament (ACL) tear, it is 10 times more likely one will find a lesion of the posterior root of the lateral meniscus than the medial meniscus,³ with an estimated prevalence of 5.1% of all ACL tears.⁴

Participation in contact sports,⁵ the presence of a concomitant medial meniscal tear,⁵ a steep lateral tibial slope,⁶ and lateral-to-medial slope asymmetry⁶ are risk factors for concomitant posterolateral root tear in ACL-injured subjects.

LMPR tears should be ruled out in patients with an ACL tear and marked instability on the Lachman and/or pivot shift tests, because if left untreated, not only may it lead to degenerative changes, but also it causes increased tension of the ACL graft and eventual failure.⁷

Various repair techniques of the LMPR have been described, including root fixation performed through transosseous tunnels and side-to-side repair.⁸ In the past, we have also tried suture anchor fixation through a high accessory anteromedial portal and also through a posterolateral portal. It was quite difficult to reach the footprint of the lateral meniscus root with an anchor through anterior portals and too risky through the posterolateral one. In this article, we propose a surgical technique to repair LMPR lesions by inserting the anchors through the outside-in ACL femoral tunnel and avoiding a second tibial tunnel.

From Clínica CEMTRO, Madrid, Spain (M.L., C.F.-L., I.R., M.G.S., E.M.B.); and Department of Orthopaedics and Traumatology, Universidad Autónoma de Nuevo León, Monterrey, Nuevo León, México (G.V.-V.).

The authors report that they have no conflicts of interest in the authorship and publication of this article. Full ICMJE author disclosure forms are available for this article online, as [supplementary material](#).

Received June 17, 2020; accepted September 20, 2020.

Address correspondence to Gregorio Villarreal-Villarreal, M.D., Department of Orthopaedics and Traumatology, Universidad Autónoma de Nuevo León, Francisco I, Madero y Av. Gonzalitos S/N, Col. Mitras Centro, Postal code: 64460, Monterrey, Nuevo León, México. E-mail: villarrealga@gmail.com

© 2020 by the Arthroscopy Association of North America. Published by Elsevier. This is an open access article under the CC BY-NC-ND license (<http://creativecommons.org/licenses/by-nc-nd/4.0/>).

2212-6287/201163

<https://doi.org/10.1016/j.eats.2020.09.020>

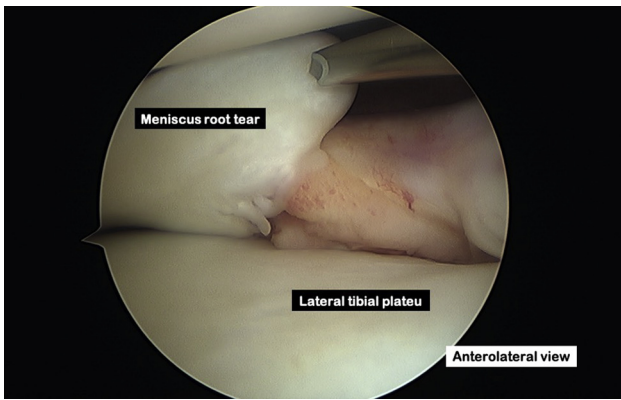


Fig 1. Lateral meniscus root tear. On a right knee, viewing from the anterolateral portal and probing through the anterior portal a complete avulsion and radial tear of the posterior lateral meniscus root is identified.

Surgical Technique (With Video Illustration)

This surgical technique was devised by the senior author (M.L.) and is demonstrated in [Video 1](#).

Patient Positioning

The surgery is performed with the patient under epidural anesthesia on the right knee (in this case). The patient lies in the supine position with the knee flexed and the foot hanging over the edge of the bed. A tourniquet should be placed as proximally as possible around the thigh. Adequate space must be available behind the foot to allow hyperflexion when necessary for femoral tunnel drilling and for anchor insertion. The leg is then prepared and draped in the standard sterile manner.

If we know for sure that we will be doing an ACL reconstruction and a meniscal root repair, we begin the procedure with the distal lateral femur approach. If this is not the case, we start with an arthroscopic examination of the involved knee.

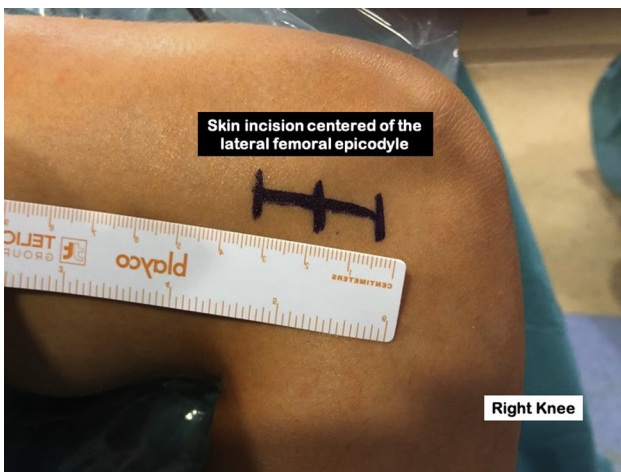


Fig 2. Skin incision. On a right knee at 90° of flexion, a 2-cm skin incision is performed, centered on the lateral femoral epicondyle to access the lateral distal femur.

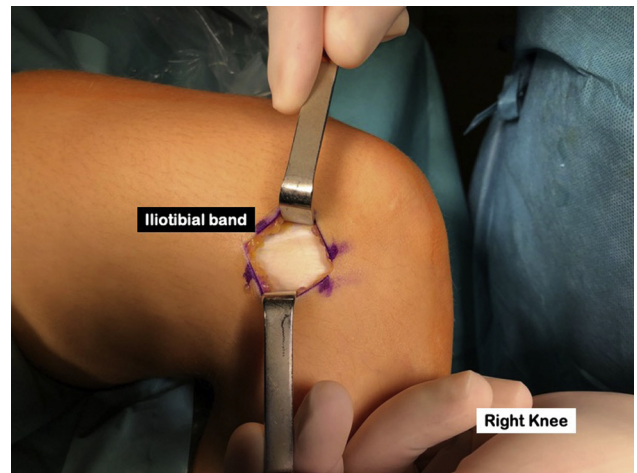


Fig 3. Iliotibial band exposition. On a right knee at 90° of flexion, dissection is performed until the iliotibial band is exposed.

Portals and Arthroscopic Examination

We begin by performing a high anterolateral portal adjacent to the lateral border of the patella. The standard anteromedial portal is made under arthroscopic visualization with a spinal needle, just medial to the patellar tendon and directly superior to the anterior horn of the medial meniscus. This portal is the viewing portal for femoral tunnel placement and reaming. After portal placement, we perform arthroscopic examination of the knee, looking for associated meniscal and chondral lesions and paying special attention to the native femoral and tibial ACL footprints.

Lateral Meniscus Root Tear Assessment

Once we have identified the LMPT (Fig 1), it is probed to assess tear pattern and severity. Afterwards, an

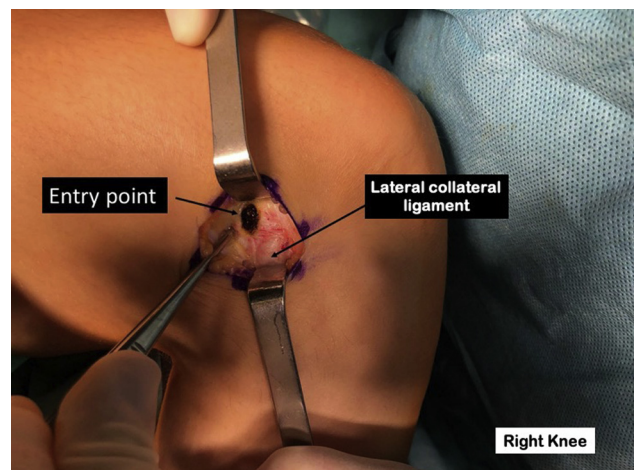


Fig 4. Femoral guide entry point. On a right knee at 90° of flexion, with sharp incision the iliotibial band is dissected and the femoral guide pin entry point is marked just proximal and posterior to the lateral epicondyle and lateral collateral ligament.

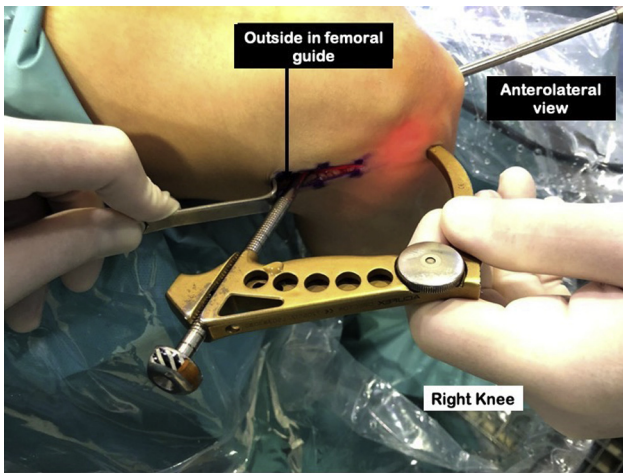


Fig 5. Outside-in femoral ACL guide placement. On a right knee at 90° of flexion the Acuflex Pinpoint femoral guide (Smith & Nephew, London, UK) is placed through the anterolateral portal and the arthroscope through the anteromedial portal. When performing an outside-in femoral tunnel, there is no need for 120° of knee flexion for a proper anatomic ACL reconstruction. (ACL, anterior cruciate ligament.)

arthroscopic curette or a burr is used to debride the normal posterior root attachment on the posterolateral tibia. Graft selection and harvest for ACL reconstruction is performed according to the surgeon's preferred method.

Outside-in Femoral Tunnel

With the knee flexed at 90°, we perform a lateral approach to the distal femur. A 2-cm skin incision is made centered on the lateral femoral epicondyle (Fig 2); we then expose the iliotibial band tract (Fig 3) and divide it in line with the skin incision. We identify the

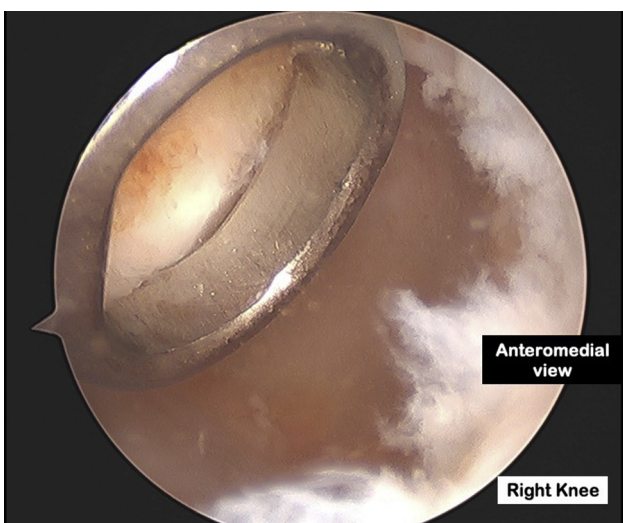


Fig 6. ACL footprint. On a right knee at 90° of flexion, viewing from the anteromedial portal, the aiming ring placed through the anterolateral portal over the femoral ACL insertion site. (ACL, anterior cruciate ligament.)

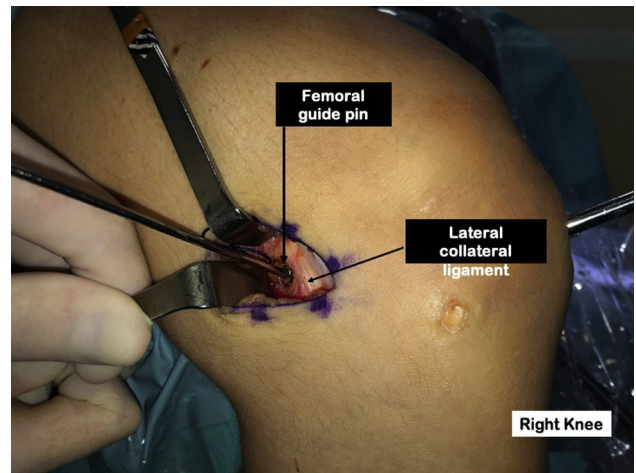


Fig 7. Femoral pin outside-in entrance. On a right knee at 90° of flexion, the final position of the femoral tunnel guide pin is proximal and posterior to the proximal insertion of the lateral collateral ligament.

proximal insertion of the lateral collateral ligament. To drill an outside-in femoral tunnel, we locate the femoral guide pin entry point just proximal and posterior to the lateral epicondyle (Fig 4). We ensure that we will not damage the lateral collateral ligament while drilling the tunnel and that there is enough space to avoid breaking the posterior cortex of the femur. For outside-in femoral tunnel drilling, the Acuflex Pinpoint femoral guide (Smith & Nephew, London, United Kingdom) with aiming attachment is inserted through the anterolateral portal (Fig 5), and the aiming ring is placed over the femoral ACL insertion site (Fig 6). The aiming hand is adjusted so that it is angled anteriorly approximately 40° to 50° to ensure that the femoral tunnel is away from the femoral insertion of the lateral collateral ligament. The bullet is then advanced until it

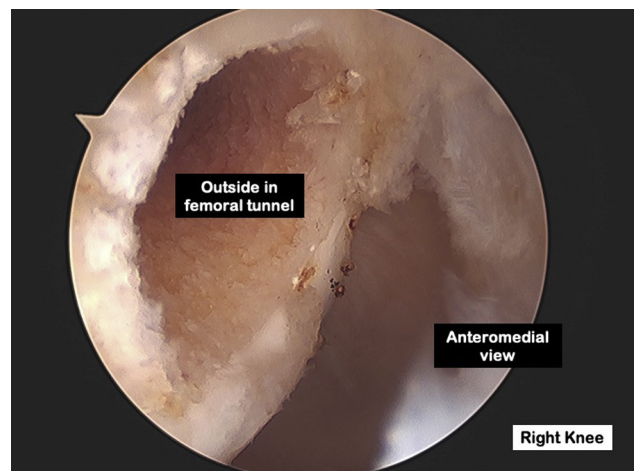


Fig 8. Femoral outside-in tunnel. On a right knee at 90° of flexion, viewing from the anteromedial portal, the femoral outside-in tunnel is created with a 2-mm bony bridge between the tunnel wall and the articular margins.

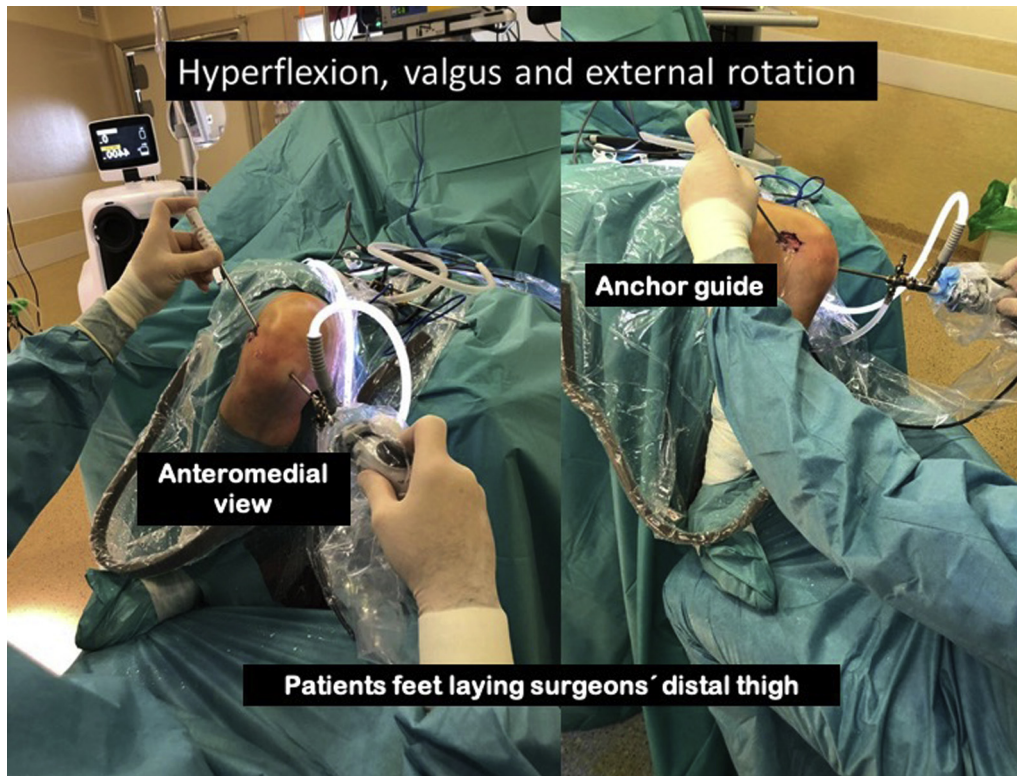


Fig 9. Maneuver. On a right knee at 90° of flexion. To achieve the correct anchor shot to lateral meniscus posterior root, a knee maneuver consisting of hyperflexion, valgus, and external rotation while the patient's foot lies on the surgeon's distal thigh.

is flush with the lateral cortex of the femur. A guide pin is then advanced in a lateral-to-medial direction (Fig 7) through the aiming arm and bullet until it protrudes into the lateral wall of the notch (ACL footprint). Once satisfactory pin placement is confirmed through

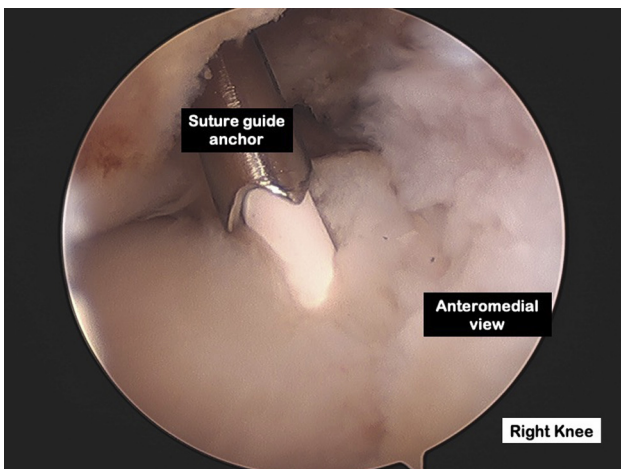


Fig 10. Evaluation of the outside-in femoral tunnel on a normal meniscus. On a right knee, viewing from the anteromedial portal. Evaluating an intact lateral meniscus posterior root on a patient undergoing an anterior cruciate ligament revision surgery. We can see that we are able to achieve a good access to the lateral meniscal posterior root through the outside-in femoral tunnel.

arthroscopic visualization from the anteromedial portal, the aiming guide and bullet are removed. The femoral tunnel is then drilled according to the corresponding ACL graft diameter (Fig 8).

Intra-articularly, the preferred tunnel center is at approximately 40% of the proximal-to-distal distance of the lateral notch and is centered between the lateral intercondylar ridge and the posterior articular margin. This point should coincide with a distance of approximately 2.5 mm plus the planned tunnel radius from the posterior articular cartilage and should be centered over the lateral bifurcate ridge. Care should be taken to ensure there is a 2-mm bony bridge between the tunnel wall and the proximal and posterior articular margins.

The trajectory and position of the femoral tunnel can be adjusted to account for previous femoral tunnels (in a revision case) or to avoid the femoral physis (in a skeletally immature patient).

Suture Anchor Placement

Adequate knee positioning is key to achieve a correct anchor placement. We perform knee hyperflexion, valgus, and external rotation with the patient's foot resting on the surgeon's thigh (Fig 9). This maneuver usually allows a direct shot to the lateral meniscus footprint (Fig 10). The degree of flexion and rotation can be modified to achieve a better access to the footprint.

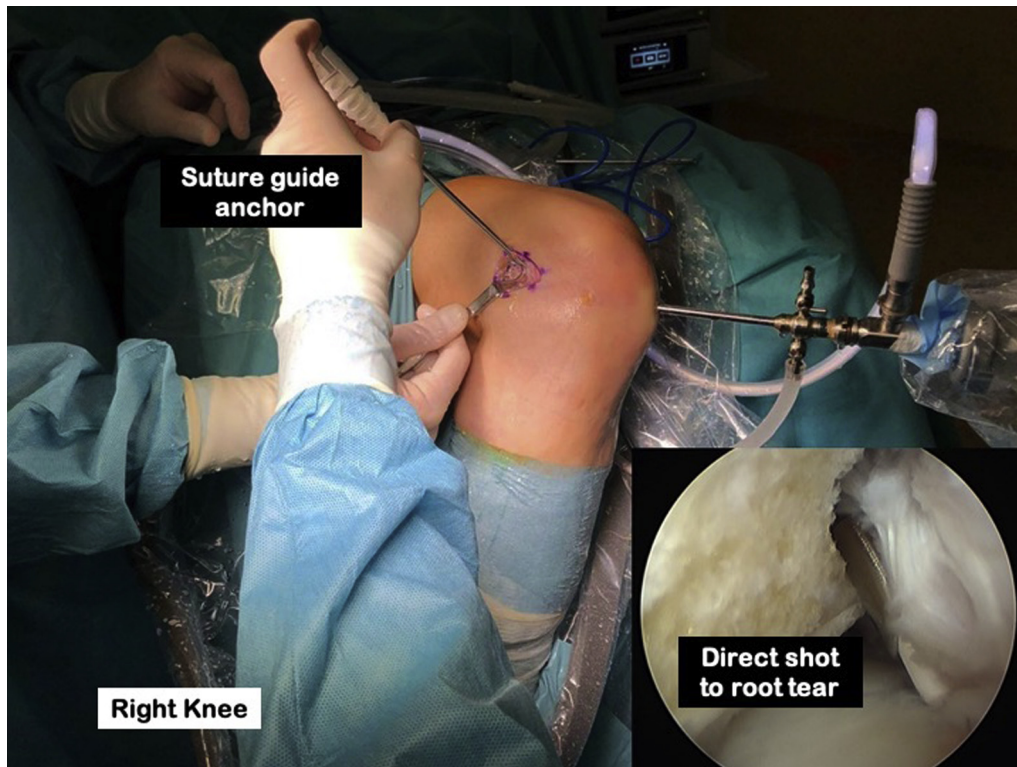


Fig 11. Maneuver and suture anchor guide. On a right knee hyperflexion, valgus and external rotation maneuver is performed. Then, a straight anchor guide of a JuggerKnot anchor (Zimmer Biomet, Warsaw, IN) is placed through the outside-in femoral tunnel on the prepared meniscus root footprint.

We then insert a straight guide through the outside-in femoral tunnel, the guide is placed at the prepared insertion site of the footprint (Fig 11), and a pilot hole is created at an appropriate angle using a flexible drill. Afterwards, we insert a 1.4-mm JuggerKnot anchor

loaded with a #1 MaxBraid Suture (Zimmer Biomet, Warsaw, IN) (Fig 12).

In most knees, a straight guide works perfect to reach the LPMR footprint; occasionally, a 25° curved guide works better. In those cases, we use the 2.3-mm

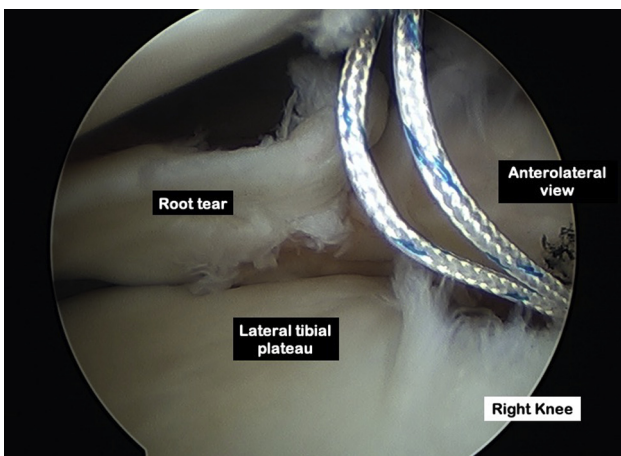


Fig 12. Suture anchor placement. On the right knee, viewing portal is changed from the anteromedial to the anterolateral portal and a 1.4-mm JuggerKnot anchor (Zimmer Biomet, Warsaw, IN) is inserted at the lateral meniscal posterior root footprint.

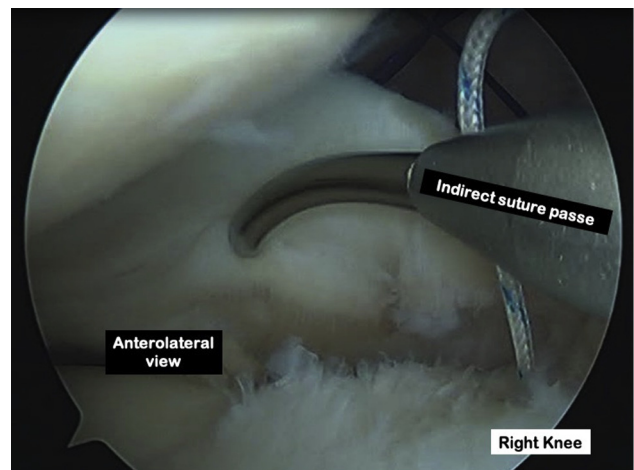


Fig 13. Indirect suture passage. On a right knee, viewing from the anterolateral portal and working through the anteromedial portal, an indirect suture passer, Spectrum II Tissue repair system (Conmed-Linvatec, Utica, NY) is used to penetrate the lateral meniscus root tear.

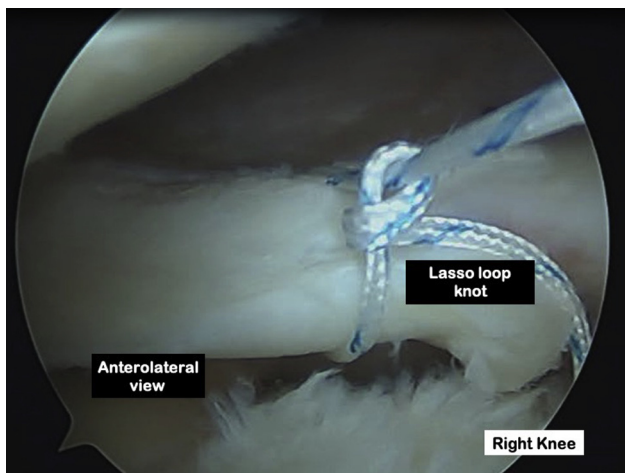


Fig 14. Lasso loop on the meniscus root. On the right knee, viewing from the anterolateral portal and working from the anteromedial portal a lasso loop knot of the lateral meniscus root is performed.

ICONIX soft suture anchor (Stryker Endoscopy, San Jose, CA) double loaded with no. 2 Force Fiber (Teleflex Medical OEM, Gurnee, IL).

Suture Passage and Knotting

A plastic cannula is then placed through the anteromedial portal to prevent the sutures from entangling the soft tissue during suture retrieving and sliding knot creation. Once we have the anchor in place, we can use an indirect suture passer Spectrum II Tissue repair system (Conmed-Linvatec, Utica, NY) (Fig 13) or a direct suture passer such as the Knee Scorpion suture passer (Arthrex, Naples, FL). Both work well to grab the meniscus and any suture configuration is possible (Fig 14).

Knot-tying can be performed through the anteromedial portal or through the ACL femoral tunnel. The latter allows us to push the meniscus against the tibial footprint while tying the knots. Once we finish the root repair (Fig 15), we perform the ACL reconstruction.

Postoperative Rehabilitation

We keep the knee immobilized in full extension, using a locked knee brace, for a week. Afterwards, we start passive range of motion exercises of the patellofemoral and tibiofemoral joints and joint mobilization techniques. Passive range of motion is restricted to 0° to 90° for 3 weeks to protect the repair from excess posterior translation of the femoral condyle during knee flexion. The repair is protected by restricting the patient to non-weight-bearing (WB) activity for 6 weeks. At week 7, partial WB activity (about 25% WB) begins. Transition from non-WB to full WB is progressed as tolerated based on assessment of pain and joint effusion response. If either pain or swelling increases, the degree of WB should be reduced. Active range of motion is

allowed once the patient is able to ambulate safely with the knee brace unlocked.

Discussion

A root tear of the lateral meniscus prevents the transformation of axial loads into tensile forces, increasing the contact area between the articular surfaces of the femur and the tibia and the force generated between them at 0° and 90° of flexion.¹ Repair of meniscal root injuries is currently accepted as the treatment of choice to restore knee biomechanics and delay osteoarthritis,⁸ both in young patients with healthy articular cartilage^{8,9} and in older patients with moderate knee osteoarthritis.¹⁰

Even though the majority of studies have shown a subjective improvement of the operated patients, some problems remain unsolved, such as poor reduction of meniscal extrusion, low cure rate evidenced by magnetic resonance imaging, and lack of evidence of long-term efficacy to prevent osteoarthritis.⁸

Various repair techniques of the LMPR have been described, including those performed through transosseous tibial tunnels^{8,11} and side-to-side sutures.^{10,12} When the root fragment of the meniscus is large enough, side-to-side repair technique is theoretically biomechanically superior, as it repairs the meniscus anatomically without changing its native physiologic properties.¹³⁻¹⁵ In contrast, transosseous tibial tunnel technique provides a favorable biological environment created during the tibial tunnel reaming.^{8,10} LMPR tears appear in 5.1% of ACL tears.⁴ In such cases, tibial tunnels to LMPR repair should be placed anterolaterally¹⁶ to avoid convergence with the ACL tibial tunnel. Some authors advocate refixation of the meniscal root combined with an ACL reconstruction

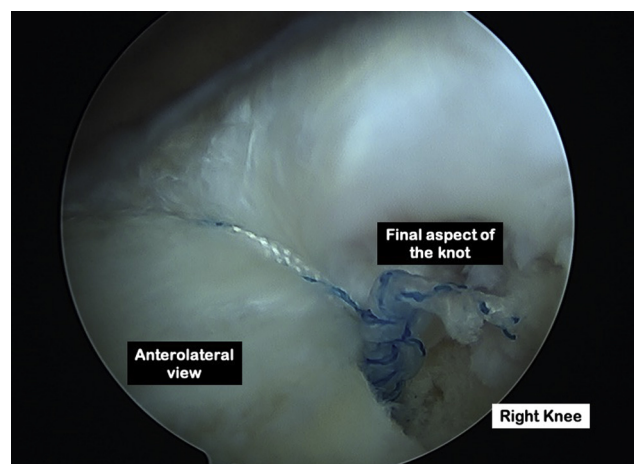


Fig 15. Final aspect of meniscus repair. On a right knee, viewing from the anterolateral portal. A final aspect of the root repair, where the knot lies under the repaired lateral meniscal posterior root and it is not in contact with the lateral femoral condyle.

Table 1. Advantages and Disadvantages of Lateral Meniscus Root Repair Through an Outside-in ACL Reconstruction Femoral Tunnel

Advantages
Direct shot to the lateral meniscus root footprint
Two options for knot tying: (1) through the AM portal; and (2) through femoral tunnel
Direct or indirect suture passage
No need for another tibial tunnel
Quick and efficient root repair
Disadvantages
Leaving an intra-articular knot
Outside-in ACL femoral tunnel is necessary
Specialized instrumentation is necessary

ACL, anterior cruciate ligament; AM, anteromedial.

using the same tibial bone tunnel and adding an extracortical backup fixation.¹⁷

In the past, we have tried to place suture anchors on the footprint of the posterior root of the lateral meniscus through a high anteromedial portal, placing the knee in a figure of 4 position while performing an anterior drawer, but in most cases, we were not able to achieve a good insertion angle. We have also tried inserting an anchor through a posterolateral portal but we found it too risky. All these drawbacks are avoided using the technique we propose because the LMPR footprint is easily reached through the femoral tunnel and an anatomic reduction can be achieved (Table 1). Hyperflexion and external rotation of the knee facilitates access to the lateral meniscus root footprint (Table 2).

Suture anchor fixation has been proven to be a biomechanically adequate construct in medial meniscus posterior root tears showing a greater load to failure, less displacement during cyclic loading and greater stiffness than transtibial pullout repair (TPR).¹⁸ In contrast, Chung et al.¹⁹ reported that TPR was biomechanically superior in terms of contact area and contact pressure compared with suture anchor fixation, although the difference between the 2 did not reach statistical significance. A prospective study in medial meniscus root avulsions comparing arthroscopic suture anchors versus pullout suture repair reported significant functional improvement in both groups at 2-year follow-up.²⁰ Extrapolating the results on the medial meniscus to the lateral meniscus we can assume that suture anchor fixation is an adequate option for posterior lateral root repair. We prefer to use all suture anchors to avoid leaving any hard implant that may cause cartilage damage in the event of anchor pullout (Table 1).

There is evidence that the modified Mason–Allen suture configuration is biomechanically superior to simple sutures used in TPR.²¹ In addition, more complex sutures exhibit greater maximum loads, and increasing the number of sutures of the same configuration also

increases the maximum load, but there is no consensus regarding the superiority or feasibility of more complex sutures. More clinical trials are required to determine whether different suture configurations used affect long-term clinical results.²¹ The author's technique allows different configurations either using one or 2 anchors or double-loaded anchors.

LMPR are 10.3 times more likely to occur with an ACL tear than medial meniscus posterior root tears.³ If an associated lateral meniscal root tear is present in a patient who is undergoing an ACL reconstruction, we favor an outside-in femoral tunnel technique, which allows us an easy access to repair the root tear. In an international survey, 68% of orthopaedic surgeons reported using independent technique (anatomic/outside in) to perform the femoral tunnel versus the transtibial technique.²² In addition, anteromedial and outside-in drilling allows a more oblique and shorter femoral tunnel. Therefore, the ACL graft more closely resembles the native ACL anatomy and biomechanics. A 2013 meta-analysis of cadaveric studies found similar intra-articular location of the tunnel between anatomical and outside-in techniques.²³ Regarding results and complication rates, there seem to be no differences between the anatomical and the outside-in techniques.²⁴

Our technique has its risks and limitations. The first limitation is that it can only be performed if an outside-in femoral tunnel is used for ACL reconstruction. Second, it requires of special instrumentation and a suture anchor that may increase costs. Third, certain arthroscopic skills are needed to avoid suture entangling during knot-tying. Risks can include an excessive decortication of the meniscal root which could decrease the pullout strength of the anchor, applying excessive tension through the knot and causing damage to the meniscus, or leaving a large intraarticular knot that may be harmful to the knee.

In conclusion, our technique allows an anatomic reduction of the LMPR and a biomechanically favorable repair avoiding the complications related to tibial tunnel reaming, such as chondral iatrogenic damage and tunnel coalescence.

Table 2. Pearls and Pitfalls of Lateral Meniscus Root Repair Through an Outside-in ACL Reconstruction Femoral Tunnel

Pearls
Knee hyperflexion, valgus, and external rotation to reach the meniscus root footprint
Plastic cannula on the AM portal to avoid suture entangling
Use of all suture anchors
Do not be aggressive while decorticating the LMPR footprint
Pitfalls
Not suitable for stiff knees
Grasping <2 mm from the meniscus root end, normally this tissue is feeble and can be torn by the sutures

ACL, anterior cruciate ligament; AM, anteromedial; LMPR, lateral meniscal posterior root.

References

1. Bhatia S, LaPrade CM, Ellman MB, et al. Meniscal root tears: Significance, diagnosis, and treatment. *Am J Sports Med* 2014;42:3016-3030.
2. Pache S, Aman ZS, Kennedy M, et al. Meniscal root tears: Current concepts review. *Arch Bone Joint Surg* 2018;6:250-259.
3. Matheny LM, Ockuly AC, Steadman JR, LaPrade RF. Posterior meniscus root tears: Associated pathologies to assist as diagnostic tools. *Knee Surg Sports Traumatol Arthrosc* 2015;23:3127-3131.
4. Shen JW, Song GY, Zhang H, et al. Prevalence of lateral meniscal extrusion for posterior lateral meniscal root lesion with and without concomitant midbody radial tear in anterior cruciate ligament injury. *Arthroscopy* 2016;32:828-834.
5. Praz C, Vieira TD, Saithna A, et al. Risk factors for lateral meniscus posterior root tears in the anterior cruciate ligament-injured knee: An epidemiological analysis of 3956 patients from the Santi study group. *Am J Sports Med* 2019;47:598-605.
6. Kolbe R, Schmidt-Hebbel A, Forkel P, Pogorzelski J, Imhoff AH, Feucht MJ. Steep lateral tibial slope and lateral-to-medial slope asymmetry are risk factors for concomitant posterolateral meniscus root tears in anterior cruciate ligament injuries. *Knee Surg Sports Traumatol Arthrosc* 2019;27:2585-2591.
7. Frank JM, Moatshe G, Brady AW, et al. Lateral meniscus posterior root and menisiofemoral ligaments as stabilizing structures in the ACL-deficient knee: A biomechanical study. *Orthop J Sport Med* 2017;5:2325967117695756.
8. Phocas A, Chahla J, LaPrade R. Meniscal root tears: A missed epidemic? How should they be treated? In: LaPrade R, et al., eds. *The menisci*. Berlin, Heidelberg: Springer-Verlag, 2017;49-61.
9. Bonasia DE, Pellegrino P, D'Amelio A, Cottino U, Rossi R. Meniscal root tear repair: Why, when and how? *Orthop Rev (Pavia)* 2015;7:5792.
10. Drago JL, Konopka JA, Guzman RA, Segovia N, Kandil A, Pappas GP. Outcomes of arthroscopic all-inside repair versus observation in older patients with meniscus root tears. *Am J Sports Med* 2020;48:1127-1133.
11. Chahla J, Moulton SG, LaPrade CM, Dean CS, LaPrade RF. Posterior meniscal root repair: The transtibial double tunnel pullout technique. *Arthrosc Tech* 2016;5:e291-e296.
12. Zhuo H, Chen Q, Zhu F, Li J. Arthroscopic side-to-side repair for complete radial posterior lateral meniscus root tears. *BMC Musculoskelet Disord* 2020;21:130.
13. Ahn JH, Lee YS, Yoo JC, et al. Results of arthroscopic all-inside repair for lateral meniscus root tear in patients undergoing concomitant anterior cruciate ligament reconstruction. *Arthroscopy* 2010;26:67-75.
14. Anderson L, Watts M, Shapter O, et al. Repair of radial tears and posterior horn detachments of the lateral meniscus: Minimum 2-year follow-up. *Arthroscopy* 2010;26:1625-1632.
15. Song HS, Bae TY, Park BY, et al. Repair of a radial tear in the posterior horn of the lateral meniscus. *Knee* 2014;21:1185-1190.
16. LaPrade CM, James EW, LaPrade RF. A modified transtibial pull-out repair for posterior root avulsions of the lateral meniscus with concomitant anterior cruciate ligament reconstruction: A report of two cases. *JBJS Case Connector* 2014;4:e96.
17. Forkel P, Foehr P, Meyer JC, et al. Biomechanical and viscoelastic properties of different posterior meniscus root fixation techniques. *Knee Surg Sports Traumatol Arthrosc* 2017;25:403-410.
18. Feucht MJ, Grande E, Brunhuber J, et al. Biomechanical comparison between suture anchor and transtibial pull-out repair for posterior medial meniscus root tears. *Am J Sports Med* 2014;42:187-193.
19. Chung KS, Choi CH, Bae TS, et al. Comparison of tibiofemoral contact mechanics after various transtibial and all-inside fixation techniques for medial meniscus posterior root radial tears in a porcine model. *Arthroscopy* 2018;34:1060-1068.
20. Kim JH, Chung JH, Lee DH, Lee YS, Kim JR, Ryu KJ. Arthroscopic suture anchor repair versus pullout suture repair in posterior root tear of the medial meniscus: A prospective comparison study. *Arthroscopy* 2011;27:1644-1653.
21. Jiang EX, Everhart JS, Abouljoud M, et al. Biomechanical properties of posterior meniscus root repairs: A systematic review. *Arthroscopy* 2019;35:2189-206.e2.
22. Chechik O, Amar E, Khashan M, Lador R, Eyal G, Gold A. An international survey on anterior cruciate ligament reconstruction practices. *Int Orthop* 2013;37:201-206.
23. Riboh JC, Hasselblad V, Godin JA, Mather RC 3rd. Transtibial versus independent drilling techniques for anterior cruciate ligament reconstruction: A systematic review, meta-analysis, and meta-regression. *Am J Sports Med* 2013;41:2693-2702.
24. CarlLee T, Ries Z, Duchman K, et al. Outside-in vs. anteromedial portal drilling during primary ACL reconstruction: Comparison at two years. *Iowa Orthop J* 2017;37:117-122.