



Treatment of neoplastic colonic lesions using the full-thickness resection device

Muhammad A. Shafqet, MD,¹ Carla R. Caruso, MD,² David L. Diehl, MD¹

Background and Aims: Advanced adenomas and scarred lesions pose difficulties for the endoscopist because of the need for complete resection and accurate pathologic staging, which cannot be afforded by standard resection techniques. Endoscopic full-thickness resection, first described in Europe for treatment of early adenocarcinoma or scarred lesions in the colon, allows potentially curative en bloc resection in patients who may be at a high risk for surgery. We describe our endoscopic approach and histologic outcomes with use of a commercially available endoscopic full-thickness resection device (FTRD) (Ovesco Endoscopy, Tubingen, Germany).

Methods: We report our experience using the FTRD for advanced polyps in patients referred to our tertiary care center. Three patients were identified from a prospectively maintained database of patients undergoing FTRD from December 2018 to February 2019. Demographic, endoscopic, and histologic data were collected.

Results: All patients underwent successful full-thickness resection of the adenocarcinoma, and histopathologic examination showed negative lateral and deep margins. No immediate or delayed adverse events occurred during an average 2-month follow-up period.

Conclusions: Full-thickness resection with an over-the-scope fitted FTRD is safe and effective in the management of advanced colonic neoplastic lesions. (VideoGIE 2019;4:535-8.)

Endoscopic full-thickness resection (EFTR) is a minimally invasive technique for resecting colorectal lesions that may not be amenable to resection by EMR or endoscopic submucosal dissection (ESD).¹ Nonlifting adenomas where submucosal invasion is suspected, residual or recurrent adenomas, lesions in difficult locations (ie, involving a diverticulum), and subepithelial lesions are all candidates for EFTR. Moreover, EFTR may serve as an alternative to surgery in patients with benign or malignant neoplastic lesions who are medically unfit or unwilling to undergo surgery.²

The full-thickness resection device (FTRD) (Ovesco Endoscopy, Tubingen, Germany) is the only commercially available and U.S. Food and Drug Administration—approved over-the-scope fitted device that allows a 1-step “clip and cut” full-thickness resection with simultaneous closure of the luminal defect (Video 1, available online at www.VideoGIE.org).³

ENDOSCOPIC FULL-THICKNESS RESECTION WITH FTRD

An initial preliminary colonoscopy is performed to identify and circumferentially mark the lesion with the use of coagulation current by a snare tip or the provided FTRD marking probe.

The colonoscope is then withdrawn and mounted with the FTRD device, consisting of a distal cap attachment with a built-in over-the-scope clip and a snare (Fig. 1).²

The colonoscope with the mounted FTRD system is reintroduced and advanced to the area of the lesion. The lesion is subsequently grasped with an FTRD grasper and retracted into the distal cap. Once the thermally marked borders of the lesion are identified through the transparent cap, the over-the-scope clip is deployed. Immediately after this step, the preloaded snare attached to the tip of the transparent cap is advanced over the lesion by closing the snare handle (Fig. 2). A blended cautery current is applied by the use of Erbe Endo-Cut Q settings (effect 1, duration 4, interval 1) to perform full-thickness resection.

The colonoscope with the grasped resected specimen is withdrawn from the patient. The resection site is then evaluated after the distal cap attachment is dismantled to confirm complete closure of the defect and rule out bleeding.

CASE SERIES

Three patients were referred to our tertiary care center between December 2018 and February 2019 to undergo resection of right-sided colonic lesions. The patients were given standard colonoscopy preparation instructions according to institutional policy. The procedures were performed under the supervision of 1 endoscopist who had

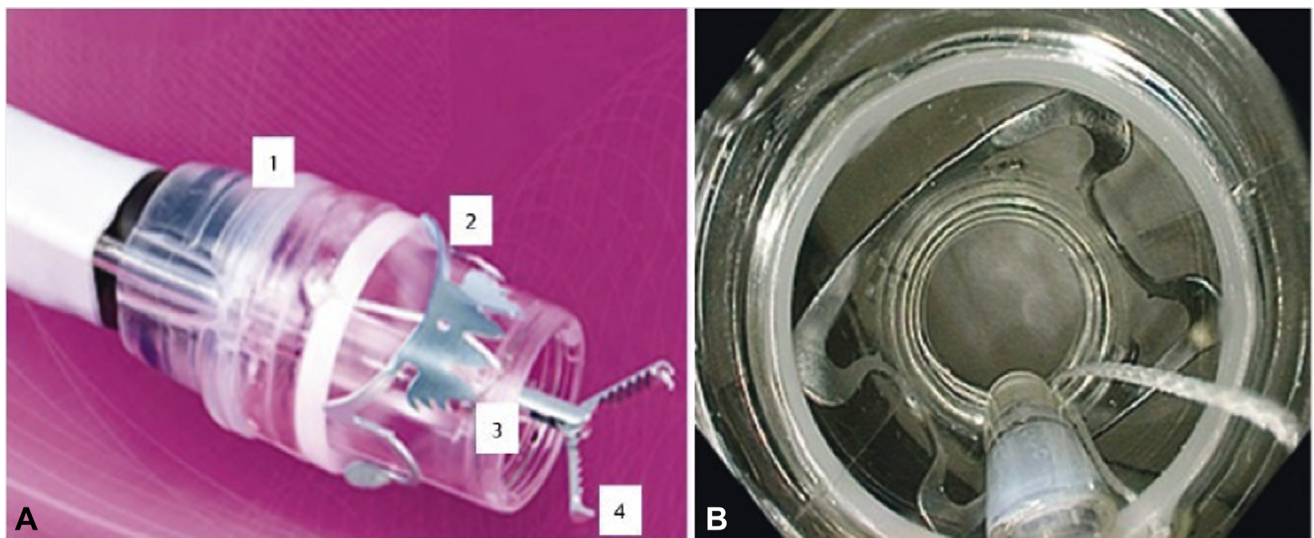


Figure 1. Full-thickness resection device (FTRD) system (Ovesco Endoscopy AG). **A**, The system consists of a single-use transparent cap (1), a modified over-the-scope clip (2), a polypectomy snare (3), and grasping forceps (4), which is advanced through the working channel of the colonoscope. **B**, Endoscopic view after the FTRD is mounted onto a colonoscope. (Image provided by Ovesco Endoscopy.)

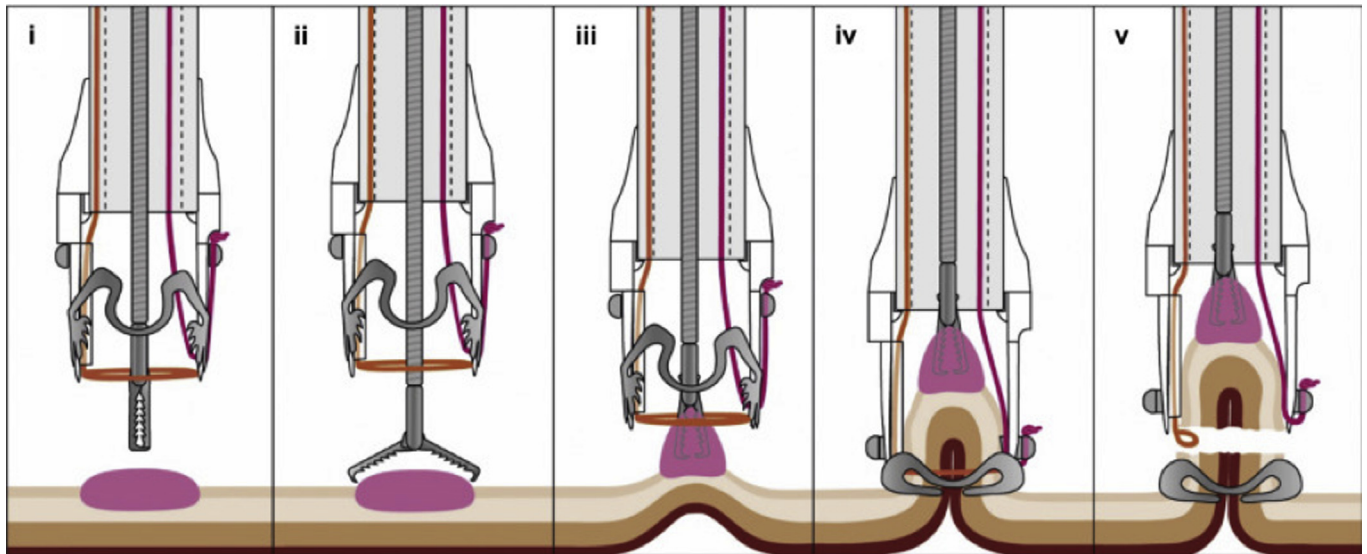


Figure 2. Schematic of full-thickness resection with the full-thickness resection device system. **(i)** The device is advanced to the marked lesion, **(ii-iii)** the lesion is retracted into the cap with a grasping forceps or tissue anchor, **(iv)** the over-the-scope clip is deployed, **(v)** resection is accomplished with pre-loaded snare. (Image provided by Ovesco Endoscopy.)

independently performed 15 full-thickness resection procedures with the FTRD system. The performing physicians were fourth-year advanced endoscopy fellows who had completed an FTRD certification course and observed live cases.

On the initial diagnostic colonoscopy, close inspection of the polyp was done before a decision was made on the appropriate resection technique. Polyp size was measured in reference to a standard 15-mm resection snare. Surface features of the polyp, including vessel and pit patterns, were ascertained by a combination of high-definition white-light endoscopy, narrow-band imaging, and chromoendoscopy

with methylene blue staining (Fig. 3). All patients appeared to have a morphologic appearance suggestive of an invasive lesion that would not be amenable to a successful resection by a standard EMR technique. Therefore, the decision was made to perform EFTR to allow potential curative resection and more accurate histopathologic staging of the suspected cancerous lesion. The lesion perimeters were marked with the snare tip (Fig. 4). EFTR was performed with the FTRD system fitted over a colonoscope. Successful full-thickness resection was performed by use of the FTRD for all 3 patients. The resection site was examined after resection to rule out bleeding or perforation (Fig. 5). No adverse events

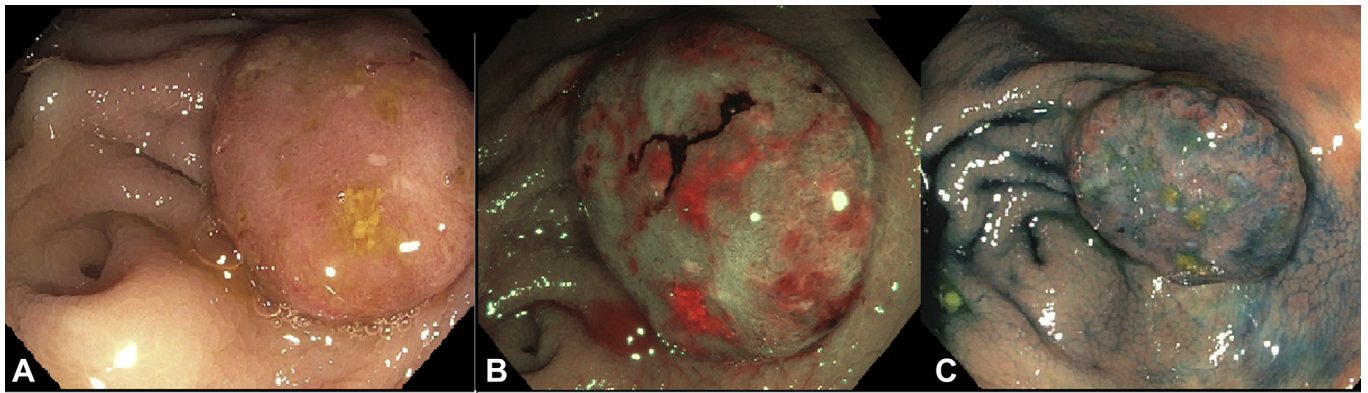

Figure 3. Cecal polyp with an advanced Kudo pit pattern seen by high-definition white light (A), narrow-band imaging (B), and methylene blue chromoscopy (C).

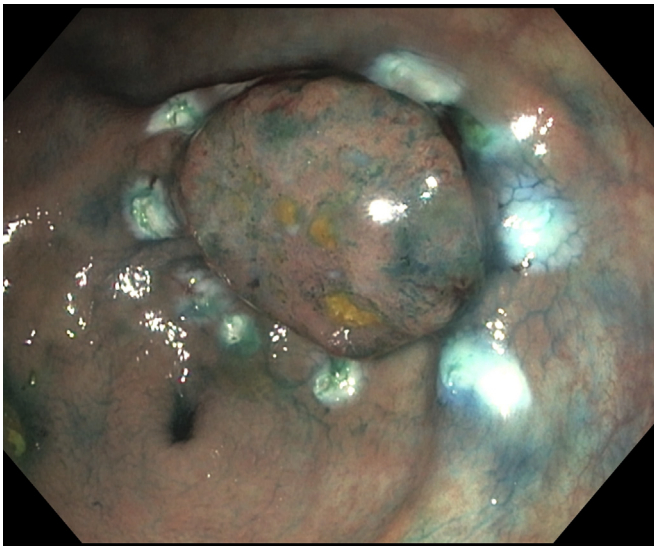

Figure 4. Cecal polyp after thermal markings in preparation for full-thickness resection.

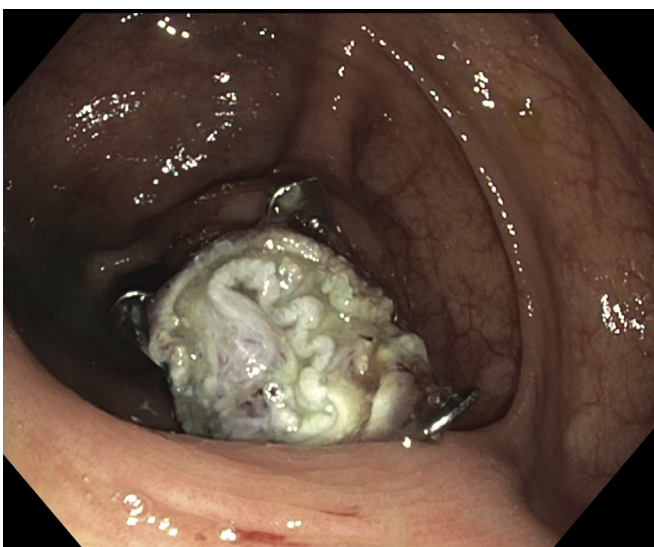

Figure 5. Base of resection site after full-thickness resection showing the over-the-scope clip and muscle and serosal tissue.

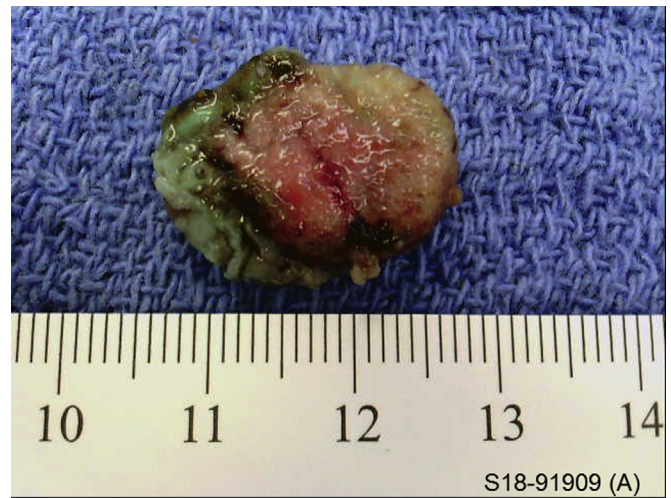

Figure 6. Gross specimen retrieved after en bloc full-thickness resection.

occurred during the procedure. All patients were discharged the same day after standard postprocedure recovery. The resected specimens were mounted and set in formalin for pathologic analysis (Fig. 6).

Histologic examination revealed invasive adenocarcinoma in all 3 patients with R0 resection (Table 1). No lymphovascular invasion was identified. All resected specimens contained muscularis propria or serosa, confirming a full-thickness resection.

During clinical follow-up, patient 1 was offered a right hemicolectomy because of muscularis propria invasion and the associated risk of lymph node metastasis. Interestingly, his subsequent surgical specimens did not reveal any evidence of residual adenocarcinoma or lymph node involvement. Patient 2 had a prior history of rectal cancer treated with lower anterior resection and was offered completion colectomy because of his high risk for the development of metachronous disease in the future. Patient 3 had no evidence of adenoma recurrence at a 3-month follow-up colonoscopy, and because of his advanced age, further surveillance colonoscopy was offered barring worsening of underlying comorbidities.

TABLE 1. Case series of patients undergoing endoscopic full-thickness resection by use of FTRD

Patient	Age (years)	Size (mm)	Paris class	Kudo pit pattern	Location	Previous intervention	Time of procedure (min)	Final pathologic diagnosis (AJCC stage)	R0 resection achieved?	Adverse events (2-month follow-up)
1	66	15	Is	V	Cecum	Yes, nonlifting lesion	49	Moderately differentiated adenocarcinoma invading muscular propria (T2)	Yes	None
2	59	15	Is	V	Cecum	Tattoo only	45	Moderately differentiated adenocarcinoma invading submucosa (T1)	Yes	None
3	83	20	Is	V	Ascending	None	43	Moderately differentiated adenocarcinoma invading submucosa (T1)	Yes	None

AJCC, American Joint Committee on Cancer; FTRD, full-thickness resection device.

DISCUSSION

We report our experience using the FTRD system for EFTR of colon cancer. EFTR with the FTRD system was technically successful and safe in our case series and provided clinically important prognostic information.

Current practice guidelines suggest that endoscopic resection of a cancerous lesion can be considered curative, provided the resected lesion is a single specimen with low-risk histologic features (lack of angiolymphatic invasion, favorable grade of differentiation, and negative resection margins).^{4,5} For lesions that may be nonlifting or where deep invasion is suspected, EFTR has emerged as a modality that provides R0 resection rates superior to those afforded by EMR and noninferior to those of ESD.^{1,6} Moreover, EFTR with the FTRD requires less technical expertise compared with the ESD, with lower reported adverse event rates (eg, perforation).^{6,7}

Histopathologic assessment of EFTR specimens allows appropriate staging and treatment of patients with colon neoplasms. For T1 lesions with low-risk histologic features, the long-term risk of lymph node metastasis or local recurrence has been shown to be very low.⁸ Therefore, EFTR allows curative resection and obviates the need for surgery. For lesions that have high-risk histologic features such as lymphovascular invasion, tumor invasion deeper than superficial submucosa, or a poor grade of differentiation, EFTR allows superior diagnostic staging than could be afforded by examination of superficial mucosal biopsy or resection specimens.^{6,7} These patients can then be more appropriately counseled on their risk of local or lymph node recurrence and can be appropriately offered surgery.

In conclusion, EFTR of colonic lesions is a safe and useful technique in staging of colon tumors. Further use of the FTRD will continue to delineate its role in the management of colorectal cancer.

DISCLOSURE

Dr Diehl is a consultant for Boston Scientific, Cook Medical, Olympus, Pentax, Steris, Lumendi, and

Medtronic. All other authors disclosed no financial relationships relevant to this publication.

Abbreviations: EFTR, endoscopic full-thickness resection; ESD, endoscopic submucosal dissection; FTRD, full-thickness resection device.

REFERENCES

- Andrisani G, Soriani P, Manno M, et al. Colo-rectal endoscopic full-thickness resection (EFTR) with the over-the-scope device (FTRD). *Dig Liver Dis* 2019;51:375-81.
- van der Spek B, Haasnoot K, Meischl C, et al. Endoscopic full-thickness resection in the colorectum: a single-center case series evaluating indication, efficacy and safety. *Endosc Int Open* 2018;6: E1227-34.
- Wannhoff A, Caca K. Endoscopic full-thickness resection of early mucosal neoplasms. *Tech Gastrointest Endosc* 2019;21:13-8.
- Fisher DA, Shergill AK, Early DS, et al. Role of endoscopy in the staging and management of colorectal cancer. *Gastrointest Endosc* 2013;78: 8-12.
- Benson A, Venook A. NCCN Clinical Practice Guidelines in Oncology: Colon Cancer. In: Vol Version 1. 2019. March 2019 ed: National Comprehensive Cancer Network; 2019. Available at: https://www.nccn.org/professionals/physician_gls/pdf/colon.pdf. Accessed Jun 28, 2019.
- Kuellermer A, Mueller J, Caca K, et al. Endoscopic full-thickness resection for early colorectal cancer. *Gastrointest Endosc* 2019;89:1180-9.
- Fazlollahi L, Remotti HE. Pathology perspective on endoscopic full thickness resection (EFTR). *Tech Gastrointest Endosc* 2019;21:7-12.
- Kikuchi R, Takano M, Takagi K, et al. Management of early invasive colorectal cancer: risk of recurrence and clinical guidelines. *Dis Colon Rectum* 1995;38:1286-95.

Department of Gastroenterology (1); Department of Pathology (2), Geisinger Medical Center, Danville, Pennsylvania, USA.

Copyright © 2019 American Society for Gastrointestinal Endoscopy. Published by Elsevier Inc. This is an open access article under the CC BY-NC-ND license (<http://creativecommons.org/licenses/by-nc-nd/4.0/>).

<https://doi.org/10.1016/j.vgie.2019.07.020>

If you would like to chat with an author of this article, you may contact Dr Shafqet at ashafqet@gmail.com.