

# Malakoplakia of Proximal Tibia- A Case Report

Samarjit Singh Bansal<sup>1</sup>, Vispi H Jokhi<sup>1</sup>, Saurabh Vilas Ponde<sup>2</sup>, Nitin Kaushik<sup>1</sup>, Chandrashekhar Sonawane<sup>1</sup>

## What to Learn from this Article?

*Presentation and Management of Malakoplakia of Tibia.*

### Abstract

**Introduction:** Malakoplakia is chronic granulomatous disorder resulting from an abnormal immunological response resulting in accumulation of histiocytes [1]. It normally involves the urinary bladder, colon, skin etc. But bone is rarely involved. Only seven cases have been reported in the literature. Ours is the first case involving the tibia.

**Case Report:** We report a rare case of malakoplakia of bone of upper end tibia in a 24 year old female with 1 month complaints of pain in the knee.

**Conclusion:** The importance of this case report lies in the fact that malakoplakia can mimic benign lytic lesion and we need not be over aggressive while treating these patients. These can be treated with course of antibiotics [2].

**Keywords:** Malakoplakia, lytic lesion, histiocytes.

### Author's Photo Gallery



Dr. Samarjit Singh Bansal



Dr. Vispi H Jokhi



Dr. Saurabh Vilas Ponde



Dr. Nitin Kaushik



Dr. Chandrashekhar Sonawane

### Reviewer's Photo Gallery



Dr. Ashok Shyam



Dr. Kunal Shah

<sup>1</sup>Department of Orthopaedics, ESIPGIMS and MGM Hospital, Parel, Mumbai-12. India.

#### Address of Correspondence

Dr. Samarjit Singh Bansal, 2nd Floor Plot No.85, Abhinavnagar, Borivali East, Mumbai-400066. India. Contact no- 91-9820964463. Email- samarjit212@gmail.com

## Introduction

We report a rare case of malakoplakia of upper end of left tibia in a 24 year old female with 1 month complaints of pain in the knee. Malakoplakia is an abnormal immunological response resulting in accumulation of histiocytes [1]. It normally involves the urinary bladder, skin etc. But bone is rarely involved. Only seven cases have been reported in the literature. Ours is the first case involving the upper end tibia.

## Case Report

A 24 year old female presented in outdoor patient department with complaints of pain in the left knee of 1 month's duration. Pain was insidious in onset and increased gradually over a period of 1 month. There was no swelling over the knee joint. There was no history of any significant trauma, fever, cough and night sweats. On clinical examination there was localized tenderness over the tibia just below the joint line. There was no evidence of joint effusion. Passive and active range of motion was within normal limits. There was no evidence of synovial hypertrophy. McMurray's and Drawer test were negative. An X-ray [Fig. 1&2] of the knee joints (AP and lateral) showed a lytic lesion in the centre of the right tibia in the epiphysis just below the joint line measuring 2\*1.5 cm. It was well defined lesion with well defined border and narrow zone of transition. Other bones being normal.

MR imaging was suggestive of brodie's abscess [Fig.3].

Differential diagnosis—brodie's abscess, tuberculosis, Giant Cell Tumor, Chondroblastoma, Langerhans Cell Histiocytosis, Metastases, Aneurysmal bone cyst, Osseous Lipoma, Osteomyelitis, Subchondral Cyst.

Fine needle aspiration cytology was inconclusive. Total leukocyte count was 9400/cmm with 60% of neutrophils and 35% of lymphocyte. ESR was 25 mm by Wintrobe's method. Since MRI was suggestive of Brodie's abscess, so needle biopsy or true cut biopsy was not done.

Treatment: Since aspiration cytology was inconclusive and MR was suggestive of brodie's abscess so our treatment was

to drain the abscess cavity and fill the cavity with bone graft substitutes. Intra-operatively there was thick sclerotic wall but there was no pus formation. There was soft tissue accumulation which had a yellowish tinge and cavity was found. Tissue was sent for histopathology and culture sensitivity. The cavity was filled with bone graft substitutes. Routine antibiotics were given post-operatively with Gram positive and Gram negative coverage.

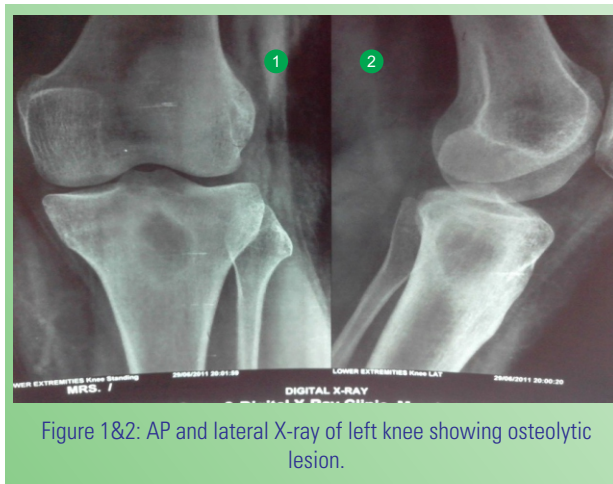


Figure 1&2: AP and lateral X-ray of left knee showing osteolytic lesion.

Histopathology[Fig.4&5]: Report was suggestive of malakoplakia and there was no growth on culture. Histopathology shows sheets of histiocytes and plasma cells in the bone. CD markers study showed positive for CD 68 and negative for CD 138, CD 38 and light chains (kappa and lambda)[3]. Michaelis and Gutman bodies were not seen. Our case was in stage 1 of malakoplakia also called as 'early pre-diagnostic' phase in which there is infiltration with plasma cells and macrophages with absent Michaelis and Gutman bodies [13].

## Discussion

Malakoplakia is rare inflammatory disorder involving an abnormal immunological response to underlying infection. It occurs most commonly in the urinary tract with causative

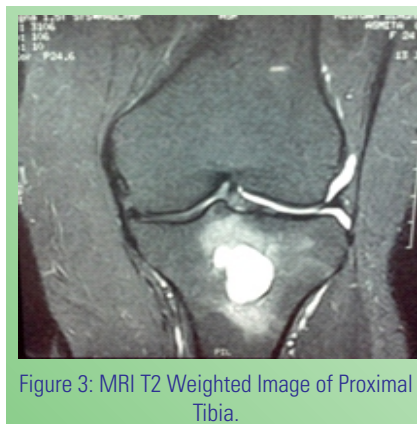


Figure 3: MRI T2 Weighted Image of Proximal Tibia.

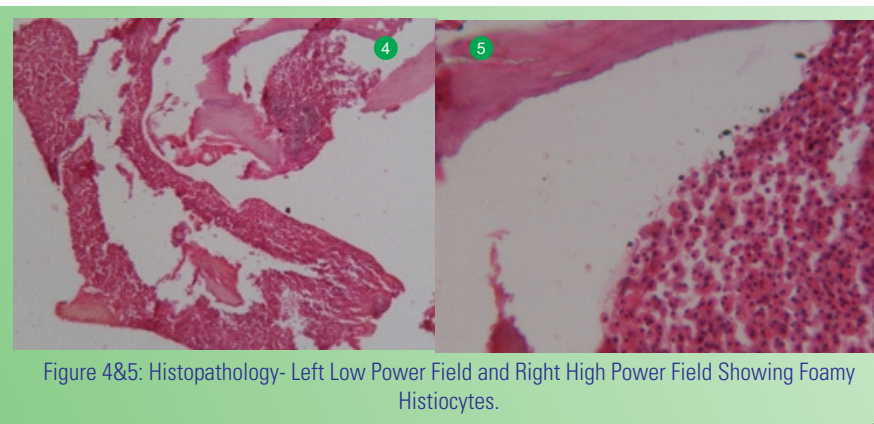


Figure 4&5: Histopathology- Left Low Power Field and Right High Power Field Showing Foamy Histiocytes.

agent being *E. coli* [4]. It is rarely found in the bone [5, 6&7]. Only 7 cases have been reported to date. Otherwise it is commonly seen in viscera, vagina, uterus, skin, thyroid, testes and lungs.

Malakoplakia was first described in the form of yellow mucosal plaques in the mucosa of urinary bladder in the early 1900s [1]. The word malakoplakia is derived from malakos (soft) and plakos mean plaque as the lesion was first described in urinary bladder [2].

Malakoplakia can occur at all ages and equally involve both male and female [1]. Peak incidence is in age group of greater than 50 years [4]. It is known to occur in patients who are malnourished or immunocompromised [2]. It has been found in association with tuberculosis, sarcoidosis and certain malignancies like lymphoma and carcinoma [8]. But our patient is not immunocompromised.

Malakoplakia is a spectrum of disease consisting of three stages- 1) early prediagnostic phase 2) classical phase 3) fibrosed phase [13].

Treatment modality for malakoplakia of bone is mainly a course of antibiotics for 4-6 weeks. If the disease process does not subside then it requires the removal of the material in the lytic cavities. Usually it follows a benign course and settles down with antibiotics [9]. Vitamin C has also been found to be beneficial as it lays new collagen fibrils.

Our treatment was clearing the cavity and filling it with bone substitutes. Patient is completely asymptomatic at follow up period of 18 months. There is no recurrence of any cavity or any lytic areas [Fig.4].

### Conclusion

The importance of this case report lies in the fact that malakoplakia can mimic benign lytic lesion. Treatment of these lytic lesions depends upon the diagnosis. Aspiration cytology must be accurate to get proper diagnosis so that treatment can be given accordingly. But as far as Malakoplakia is concerned, it can be managed with course of antibiotics. We need not be over aggressive while treating these patients.

### Clinical Message

Malakoplakia must be differentiated from other benign lytic lesions by accurate histopathology and CD markers. Histopathology is important for diagnosis and it is a spectrum of disease. Treatment is 4-6 weeks of antibiotics.

### References

1. D Geraint James. *A clinicopathological classification of granulomatous disorders Postgrad Med J* 2000; 76:457-465.
2. Eva Honsova, Alena Lodererova, Janka Slatinskab, Petr Boucek *Biomed Pap Med Fac Univ Palacky Olomouc Cured Malakoplakia of the renal allograft followed by long-term good function: A case report Czech Repub.* 2012 Jun; 156(2):180-182.
3. E benjamin, h fox *Malakoplakia of the adrenal gland From the department of Pathology J clin pathol* 1981; 34:606-611
4. Luan D. Truong, MD; Steven S. Shen, MD, PhD *Immunohistochemical Diagnosis of Renal Neoplasms*
5. Van den Bout, A.H. & Dreyer, L. *Malakoplakia of bone. A case report. J Bone Joint Surg* 1981, 63B: 254-256.
6. Weisenburger, D.D., Vinh, T.N. & Levinson, *Malakoplakia of bone - an unusual cause of pathologic fracture in an Immunosuppressed patient. Clin Ortho Related Res* 1985, 201:106-110.
7. Mojgan Mokhtari, MD.1, Shervin Pejhan, MD.2, Ahmad Shekarchizadeh, MD.3 *Vertebral Malakoplakia Department of Pathology, Isfahan University of Medical Sciences, Isfahan, Iran.*
8. Edna Toubes-Klingler; Vikram C. Prabhu; Kerry Bernal; David Poage; Susan Swindells (Profiled Author: Susan Swindells) *Malakoplakia of the cranium and cerebrum in a human immunodeficiency virus-infected man: Case report Journal of Neurosurgery* 2006;104(3):432-435.
9. Stanton, M.J. & Maxted, W. *Malakoplakia - a study of the literature and current concepts of pathogenesis, diagnosis and treatment. J Urol* 1981, 125: 139-146.
10. *Malakoplakia of bone presenting as a pathological fracture Nirmala Tyagi, Rana Sherwani, S.A. Sadiq, Veena Maheshwari, M. Abbas I And S.P. Tyagi-Postgrad Med J (1994) 70, 461 - 462.*
11. *Lastra-Camacho Gustavo, MD; Marie E. Robert, MD; Laura W. Lamps; Suzanne P. Lagarde, MD; Dhanpat Jain, MD Isolated Gastric Malakoplakia-A Case Report and Review of the Literature.*
12. George M. Yousef, MD, PhD, FRCPC; Bibi Naghibi, MD, FRCPC *Malakoplakia Outside the Urinary Tract.*
13. A. G. DOUGLAS-JONES, C. RODD, E. M. V. JAMES, R. G. S. MILLS (Cardiff) *Prediagnostic malakoplakia presenting as a chronic inflammatory mass in the soft tissues of the neck-The Journal of Laryngology and Otology February 1992, Vol. 106, pp. 173-177.*

Conflict of Interest: Nil  
Source of Support: None

### How to Cite this Article:

Bansal SS, Jokhi VH, Ponde SV, Kaushik N, Sonawane C. *Malakoplakia of Proximal Tibia- A Case Report. Journal of Orthopaedic Case Reports* 2014 April-June;4(2): 78-80