



## CASE REPORTS

# Cervical plexus block as an alternative anesthetic approach for type I thyroplasty: a case report



Antoine Abi Lutfallah <sup>a,\*</sup>, Khalil Jabbour<sup>a</sup>, Afrida Gergess<sup>a</sup>, Gemma Hayeck<sup>a</sup>,  
Nayla Matar <sup>b</sup>, Samia Madi-Jebara<sup>a</sup>

<sup>a</sup> Saint Joseph University, School of Medicine, Hôtel-Dieu de France Hospital, Department of Anesthesia, Critical Care and Pain Management, Beirut, Lebanon

<sup>b</sup> Saint Joseph University, School of Medicine, Hôtel-Dieu de France Hospital, Department of Otolaryngology Head and Neck Surgery, Beirut, Lebanon

Received 24 November 2019; accepted 11 July 2020

Available online 2 September 2020

### KEYWORDS

Type I thyroplasty;  
Anesthetic  
management;  
Cervical plexus block;  
Case report

### Abstract

**Background:** The role of type I thyroplasty (TIP) is well established as the treatment for glottal insufficiency due to vocal fold paralysis, but the ideal anesthetic management for this procedure is still largely debated. We present the case of a novel anesthetic approach for TIP using combined intermediate and superficial Cervical Plexus Block (CPB) and intermittent mild sedation analgesia.

**Case report:** A 51-year-old presenting with left vocal fold paralysis and obstructive sleep apnea was scheduled for TIP. An ultrasound-guided intermediate CPB was performed using the posterior approach, and 15 mL of ropivacaine 0.5% were injected in the posterior cervical space between the sternocleidomastoid muscle and the prevertebral fascia. Then, for the superficial CPB, a total of 10 mL 0.5% ropivacaine was injected subcutaneously, adjacently to the posterior border of the sternocleidomastoid muscle, without penetrating the investing fascia. An intermittent sedation analgesia with a target-controlled infusion of remifentanyl (target 0.5 ng·mL<sup>-1</sup>) was used to facilitate prosthesis insertion and the fiberoptic laryngoscopy. This technique offered a safe anesthetic airway and good operating conditions for the surgeon, as well as feasible voice monitoring and optimal patient comfort.

**Conclusion:** The use of a regional technique is a promising method for the anesthetic management in TIP, especially in patients with compromised airway.

© 2020 Sociedade Brasileira de Anestesiologia. Published by Elsevier Editora Ltda. This is an open access article under the CC BY-NC-ND license (<http://creativecommons.org/licenses/by-nc-nd/4.0/>).

\* Corresponding author.

E-mail: [Antoine.abilutfallah@net.usj.edu.lb](mailto:Antoine.abilutfallah@net.usj.edu.lb) (A. Abi Lutfallah).

**PALAVRAS-CHAVE**

Tireoplastia tipo I;  
Manejo anestésico;  
Bloqueio do plexo  
cervical;  
Relato de caso

**Bloqueio do plexo cervical como técnica anestésica alternativa para tireoplastia tipo I: relato de caso****Resumo**

**Introdução:** O papel da tireoplastia tipo I (TPI) está bem estabelecido no tratamento de insuficiência glótica após a paralisia das pregas vocais, mas o manejo anestésico ideal para a TPI ainda é controverso. Descrevemos uma nova técnica anestésica para a TPI usando o Bloqueio do Plexo Cervical (BPC) superficial e o BPC intermediário associados, em presença de analgo-sedação leve e intermitente.

**Relato de caso:** Paciente de 51 anos de idade com paralisia da prega vocal esquerda e apneia obstrutiva do sono foi agendada para TPI. BPC intermediário guiado por ultrassom foi realizado usando acesso posterior, e 15 mL de ropivacaína a 0,5% foram injetados no espaço cervical posterior entre o músculo esternocleidomastoideo e a fásia prevertebral. A seguir, para o BPC superficial, 10 mL de ropivacaína a 0,5% foram injetados na região subcutânea adjacente à borda posterior do músculo esternocleidomastoideo, sem transfixar a fásia de revestimento. Analgo-sedação intermitente com infusão alvo-controlada de remifentanil (alvo de 0,5 ng.mL<sup>-1</sup>) foi usada para facilitar a inserção da prótese e a laringoscopia com fibra ótica. A técnica ofereceu via aérea segura durante a anestesia, boa condição para o cirurgião, possibilidade de monitorar a voz, além de ótimo conforto à paciente.

**Conclusões:** O uso de anestesia regional é uma técnica promissora para o cuidado anestésico durante a TPI, especialmente em pacientes com via aérea comprometida.

© 2020 Sociedade Brasileira de Anestesiologia. Publicado por Elsevier Editora Ltda. Este é um artigo Open Access sob uma licença CC BY-NC-ND (<http://creativecommons.org/licenses/by-nc-nd/4.0/>).

**Introduction**

Patients afflicted by Unilateral Vocal Fold Paralysis (UVFP) often present with dysphonia, dysphagia and aspiration secondary to glottal insufficiency. Type I thyroplasty (TIP) is a surgical procedure performed to improve the voice and swallowing ability by medializing the paralyzed vocal fold with a permanent implant. Since its introduction in the 1970s, TIP was typically performed under local anesthesia with sedation analgesia, because intraoperative vocalization is required for the assessment of surgical repair.<sup>1</sup> However, it is not uncommon to encounter scenarios where an adequate depth of anesthesia is difficult to achieve; in certain situations such as morbid obesity or Obstructive Sleep Apnea (OSA), a slight increase in sedation might cause airway obstruction. Moreover, sedation exerts an important influence on voice quality and was reported to significantly reduce voice testing reliability during TIP.<sup>2</sup> Therefore, it would be interesting to maximize the efficacy of local anesthesia while reducing sedation periods during TIP.

Regional anesthesia using Cervical Plexus Block (CPB) is largely used in cervical surgery such as carotid or thyroid surgery.<sup>3</sup> In this report, we extend the application of CPB by describing the anesthetic management of TIP with combined intermediated and superficial CBP and mild sedation analgesia. We obtained written informed patient consent and Ethical Review Committee approval for this case publication.

**Case presentation**

A 51-year-old female (weight 70 kg; height 161 cm) presented with left UVFP following recurrent laryngeal nerve

injury during total thyroidectomy. Over the years, she underwent speech rehabilitation and injection laryngoplasty with insufficient results. She was therefore scheduled for TIP with Montgomery implant. Her past medical record included gastroesophageal reflux disease and OSA being treated with Continuous Positive Airway Pressure (CPAP). Physical evaluation showed moderate hoarseness with no episodes of dysphagia or laryngeal dyspnea. Her medication included esomeprazole and levothyroxine. Preoperative fiberoptic examination revealed a left UVFP with a moderate glottal gap. Given the history of OSA, we opted for regional anesthesia with minimal or no sedation.

During the preanesthetic evaluation, the patient was informed about the anesthetic and surgical steps, particularly the CPB, the use of fiberoptic endoscopy through the nose, and her being awake during the entire surgery. She was instructed to try to remain calm and immobile and to avoid unnecessary coughing and swallowing. No premedication was administered preoperatively with the exception of paracetamol 1000 mg.

Intraoperative monitoring included electrocardiogram, noninvasive blood pressure, oxygen saturation, end-tidal carbon dioxide, and bispectral index. In the operating room, the patient received dual antiemetic prophylaxis with dexamethasone 8 mg and ondansetron 4 mg, and cefazoline 2 g as antibiotic prophylaxis. Nasal mucosa was topicalised with xylometazoline (nasal decongestant) followed by 10% lidocaine spray. Oxygen was delivered via a nasal cannula at 4 L.min<sup>-1</sup>.

An ultrasound-guided intermediate CBP was performed using the posterior approach. Using a 12 MHz linear probe and a 22G × 2'' insulated needle (Stimuplex A; B. Braun, Germany), 15 mL of ropivacaína 0.5% were injected in the

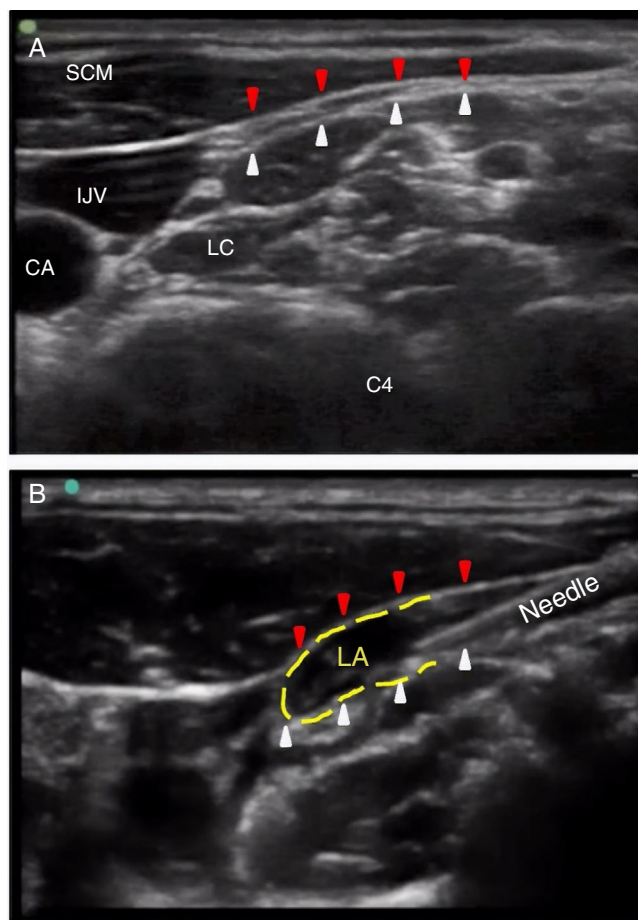
posterior cervical space (between the sternocleidomastoid muscle and the prevertebral fascia) as described by Choquet et al.<sup>4</sup> (Fig. 1). Then, for the superficial CPB, the needle was inserted subcutaneously adjacent to the posterior border of the sternocleidomastoid muscle, without penetrating the investing cervical fascia (Fig. 2). A total of 10 mL 0.5% ropivacaine was injected subcutaneously in a cephalad and caudal direction.

After assessing the CPB efficacy based on the absence of cold sensations, a TIP was performed using the Montgomery Thyroplasty Implant system (Boston Medical Products, USA). The surgical technique was followed as described in previous reports.<sup>5</sup> Horizontal incision was made at the level of the mid portion of the thyroid cartilage, and a subplatysmal flap was elevated until the level of the hyo-thyroid membrane superiorly and the cricoid cartilage inferiorly. Up to this moment, the patient was completely awake without any discomfort. A sedation analgesia with a Target-Controlled Infusion (TCI) of remifentanyl was then initiated (target 0.5 ng.mL<sup>-1</sup>) to facilitate subsequent surgical steps and the fiberoptic laryngoscopy that will follow. The prelaryngeal muscles were reflected laterally. A window was created in the antero-inferior portion of the thyroid cartilage using a small drill. Decision on the appropriate prosthesis size was made based on the intraoperative assessment of the quality of the patient's voice and the laryngoscopic appearance of the medialized vocal fold. After prosthesis placement, the remifentanyl infusion was stopped and the wound was sutured over a small drain.

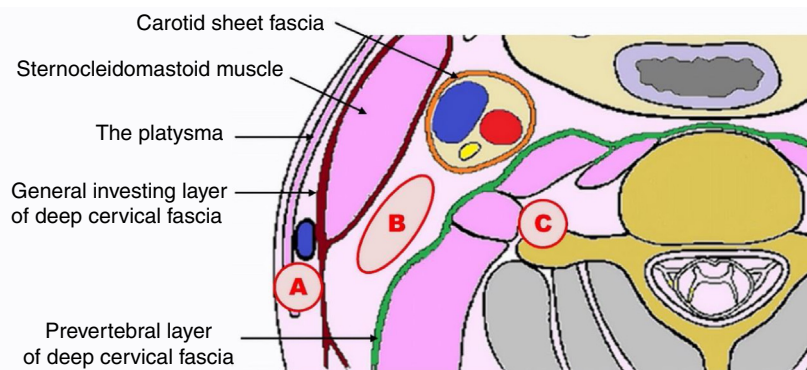
After one hour of observation in the postanesthesia care unit, the patient was returned to the ward uneventfully. Postoperatively, she ingested water 6 hours after the operation and started solid diet gradually from day 1 onwards. She was discharged on day 2 with significant improvement in her voice and no complications.

## Discussion

The role of TIP is well established in the treatment of glottal insufficiency due to vocal fold paralysis. However, the ideal anesthetic management for this procedure is still largely debated. Several anesthetic techniques



**Figure 1** (A) Transverse ultrasound images of the lateral cervical area at the C4 level: the posterior cervical space is located between the posterior border of the sternocleidomastoid muscle (red arrows) and the prevertebral fascia (white arrows). (B) Ultrasound-guided intermediate cervical plexus block: the needle is located in the posterior cervical space; the local anesthetic solution spreads towards the carotid sheath (yellow dashed line). CA, Carotid Artery; IJV, Internal Jugular vein; LA, Local Anesthetic; LC, Longus Colli; SCM, Sternocleidomastoid Muscle.



**Figure 2** Schematic depiction of the three target areas of Cervical Plexus Blocks (CPB) at the C4 level. (A) The target area for superficial CPB is subcutaneous tissue around the midportion of posterior border of the Sternocleidomastoid Muscle (SCM). (B) The target area for intermediate CPB is located between the SCM muscle and the prevertebral fascia. (C) The target area for deep CPB is located between the prevertebral fascia and the target transverse process.

have been described. They include local anesthesia alone or with sedation,<sup>1</sup> general anesthesia using laryngeal mask airway,<sup>6-8</sup> and general anesthesia with endotracheal intubation.<sup>9</sup> Each of these techniques has its advantages and disadvantages.

### Local anesthesia

Local anesthesia ensures patients' cooperation, which is necessary for intraoperative voice assessment.<sup>1</sup> However, the analgesia provided is sometimes insufficient, which requires supplemental infiltrations of local anesthetics during tissue dissection, making the patients anxious. Moreover, the procedure may last two to three hours, rendering the patients restless and uncomfortable. The adjunction of sedation promotes anxiolysis and a better surgical field. But the adequate plane of anesthesia can be difficult to achieve especially in patients with obstructive sleep apnea, chronic obstructive pulmonary disease, severe asthma, and obesity, leading to reduced airway muscles tone, obstructive breathing, and hypoxemia. Sedation also decreases voice testing reliability during TIP, which might explain some thyroplasty failures due to choosing an incorrect implant size.<sup>2</sup>

### General anesthesia

Anesthetic problems also arise during general anesthesia. The intraoperative voice testing becomes impossible, and the decision on optimum prosthesis size and placement is based solely on continuous fiberoptic visualization of the vocal cords, creating a potential challenge on shared airways. If a tracheal tube is used, the view of the vocal cords becomes limited. Furthermore, the use of laryngeal mask for procedures with arytenoid adduction may not be suitable, as it makes surgical exposure more difficult. In this context, Stow et al. suggested temporarily deflating the laryngeal mask for better exposure.<sup>6</sup>

### Sequential anesthesia

Considering all the above, some teams have proposed a sequential anesthesia where surgical dissection is done under general anesthesia, allowing patients immobility and suppression of laryngeal responses to surgical manipulation, followed by a period of awake sedation for vocalization.<sup>10,11</sup> However, smooth emergence from general anesthesia to sedation without coughing or bucking was not always guaranteed.

### Cervical plexus block

CPBs are largely used in cervical surgery such as carotid or thyroid surgery.<sup>3</sup> The cervical plexus (C2–C4) is responsible for the sensory innervation of the anterior cervical skin, the subcutaneous tissues and the extrinsic laryngeal muscles as well as the sternocleidomastoid muscle. A CPB at the intermediate level, coupled with a complementary superficial CPB (Fig. 2), can block all four cutaneous branches as well as the sensory and motor branches of the cervical plexus, providing adequate anesthesia for neck surgeries that involve

manipulation of the cervical skin and the underlying cervical muscles.<sup>3</sup> It is more effective than the superficial CPB alone, and provides a more complete anesthesia that is comparable to the deep CPB, but with fewer side effects.

To our knowledge, this is the first report on the use of combined intermediate and superficial CPB for TIP surgery. Suresh et al. reported a case for vocal cord surgery in an awake pediatric patient using a superficial CPB.<sup>12</sup> Their patient was, however, sedated with intravenous (IV) midazolam (2 mg), IV fentanyl (25 µg) and a propofol infusion (70 µg·kg<sup>-1</sup>·min<sup>-1</sup>). As mentioned before, such sedation could affect intraoperative phonation<sup>2</sup> and cause airway obstruction. In the present case, combining intermediate and superficial CPB offered optimal patient comfort and excellent surgical conditions from the skin incision to the skeletonization of the thyroid cartilage. The need of prolonged sedation periods was nullified, and the use of mild sedation analgesia was restrained to stages that might induce some discomfort, such as the fiberoptic laryngoscopy or final prosthesis insertion.

Complications associated with CPBs include systemic toxicity from injection of local anesthetics into the vertebral artery or the external or internal jugular veins, phrenic nerve palsy, temporary Horner's syndrome, hoarseness from Recurrent Laryngeal Nerve (RLN) paralysis and airway obstruction in case of a concomitant contralateral RLN paralysis. However, these safety issues are mostly related to deep CPBs.<sup>3</sup> Moreover, dysphonia due to ipsilateral blockade of RLN after an intermediate CPB is usually rare (2.4%),<sup>13</sup> not clinically significant, and unlikely to affect the intraoperative voice quality during TIP since the RLN is already paralyzed.

### Conclusion

This technique provides a safe anesthetic airway and good operating conditions for the surgeon, as well as feasible voice monitoring and optimal patient comfort. Thus, we believe that combined intermediate and superficial CPB with minimal sedation analgesia is a promising method for the anesthetic management in TIP, especially in patients with compromised airway.

### Ethical standards

For this article, written informed consent from the patient and Ethical Review Committee approval were obtained before writing the case report.

### Conflicts of interest

The authors declare no conflicts of interest.

### References

1. Isshiki N, Morita H, Okamura H, et al. Thyroplasty as a new phonosurgical technique. *Acta Otolaryngol (Stockh)*. 1974;78:451–7.

2. Oishi N, Herrero R, Martin A, et al. Is testing the voice under sedation reliable in medialization thyroplasty? *Logoped Phoniatr Vocol*. 2016;41:149–53.
3. Kim J-S-S, Ko JS, Bang S, et al. Cervical plexus block. *Korean J Anesthesiol*. 2018;71:274–88.
4. Choquet O, Dadure C, Capdevila X. Ultrasound-guided deep or intermediate cervical plexus block: the target should be the posterior cervical space. *Anesth Analg*. 2010;111:1563–4, author reply 1564–1565.
5. Montgomery WW, Blaugrund SM, Varvares MA. Thyroplasty: a new approach. *Ann Otol Rhinol Laryngol*. 1993;102:571–9.
6. Stow NW, Lee JW, Cole IE. Novel approach of medialization thyroplasty with arytenoid adduction performed under general anesthesia with a laryngeal mask. *Otolaryngol-Head Neck Surg Off J Am Acad Otolaryngol-Head Neck Surg*. 2012;146:266–71.
7. Razzaq I, Wooldridge W. A series of thyroplasty cases under general anaesthesia. *Br J Anaesth*. 2000;85:547–9.
8. Kanazawa T, Watanabe Y, Hara M, et al. Arytenoid adduction combined with medialization laryngoplasty under general anesthesia using a laryngeal mask airway. *Am J Otolaryngol*. 2012;33:303–7.
9. Zapater E, Oishi N, Hernández R, et al. Medialization thyroplasty under intubation anesthesia to restore the voice after cordectomy. *Laryngoscope*. 2016;126:1404–7.
10. Sproson E, Nightingale J, Puxeddu R. Thyroplasty type I under general anaesthesia with the use of the laryngeal mask and a waking period to assess voice. *Auris Nasus Larynx*. 2010;37:357–60.
11. Saadeh CK, Rosero EB, Joshi GP, et al. Reducing sedation time for thyroplasty with arytenoid adduction with sequential anesthetic technique. *Laryngoscope*. 2017;127:2813–7.
12. Suresh S, Templeton L. Superficial cervical plexus block for vocal cord surgery in an awake pediatric patient. *Anesth Analg*. 2004;98:1656–7, table of contents.
13. Alilet A, Petit P, Devaux B, et al. Ultrasound-guided intermediate cervical block versus superficial cervical block for carotid artery endarterectomy: The randomized-controlled CERVECHO trial. *Anaesth Crit Care Pain Med*. 2017;36:91–5.