

C A S E R E P O R T

Necrotizing fasciitis of the hand: a case report

Andrea Minini, Stefano Galli, Andrea Salvi, Guido Zarattini

Clinica Ortopedica dell' Università degli Studi di Brescia

Summary. Necrotizing Fasciitis is a rare life-threatening infection, usually polymicrobial, that frequently affects the extremities in as many as two thirds of the cases. It typically involves primarily the muscular fascia, and then spreads through muscular and subcutaneous tissues. The early diagnosis may be challenging, and appears to be crucial in the management of this condition. We report a case of a 45-year-old man, former drug abuser, diabetic, HCV+, who developed a necrotizing fasciitis of the hand following a minor trauma. Early diagnosis based on clinical, laboratory (LRINEC score) and radiological findings, together with an accurate debridement of the affected site, allowed us to limitate the amputation to the third ray only. The reconstruction with the capitate osteotomy and the coverage with the posterior interosseous flap helped us in further reduction of the functional impairment of the hand. (www.actabiomedica.it)

Key words: Necrotizing fasciitis, LRINEC score, posterior interosseous flap, capitate osteotomy, dishwater-like pus

Introduction

The term “Necrotizing Fasciitis” (NF) refers to a life-threatening infection, with a bacterial aetiology, characterized by a rapid necrosis that primarily involves fascial tissues, and then spreads to muscular and subcutaneous tissues. This condition, also known as “flesh-eating disease” frequently engages limbs, often unilaterally, although some cases of bilateral and multifocal involvement are described in literature (1,2).

The incidence of NF ranges between 0,4 (3) and 1,3 (4) /100 000 according to the country (Canada Vs Florida).

This condition can be classified in 4 clinical forms (5,6) depending on the causative organism: one anaerobic species with one or more facultative anaerobic streptococci (other than group A) and members of the Enterobacteriaceae (7), Haemolytic streptococcus group A, members of the *Vibrio* ssp, (8) and, at last, fungineal *Candida* infections (9).

Clinically NF usually presents as an erythema of the skin surrounding the affected area, with unregularly marginated edges, warm to the touch, very painful especially in the early stages; within 3 to 5 days from the onset blisters start to emerge, evolving then in skin necrosis.

Intense fever is a very common finding; at this stage pain and tenderness to the affected area dissolve; this characteristic can actually help in identifying a NF.

Gas formation in subcutaneous tissues is frequent mostly in polimicrobial forms, especially in diabetic patients (10).

The diagnosis is essentially clinical, and can rely on a clinical/anamnestic/laboratory score named LRINEC (11).

A score of 6 or more has a positive predictive value of 92% and a negative predictive value of 96%.

Still, surgical exploration remains the gold standard for definitive diagnosis (12-14).

E.V. antibiotic treatment should be started immediately, together with surgical debridement of affected

tissues, till the possibility of the amputation of the affected limb (15).

In this article we report the case of a patient with a NF of the right hand, focusing on the importance of a prompt diagnosis and treatment.

Case

A 45 y.o. male, unemployed, diabetic (insulin-dependent), HCV+, currently under treatment for a depressive disorder, alcoholic, with a history positive for EV drug abuse until 10 years earlier, was admitted to our E.R. with a swollen and painful hand (Fig. 1, Fig. 2).

He reported a minor crush injury to his right hand between the wings of a gate 3 days before, causing a small wound to the dorsal skin of the proximal phalanx of the third finger.

At first, he started an oral antibiotic prophylaxis with Amoxicilline/clavulanic acid (1 gr x 2/day) and dressed the wound with a topical preparation of gentamicine and steroid.

The patient reported the appearance of an erythema spreading to the whole forearm and swelling of his right hand over the following two days; for this reason he headed to our E.R., where he underwent an X-ray scan of his hand (negative for fractures) and was then hospitalized in the Infectious Diseases department with an initial diagnosis of a post-traumatic phlegmon;

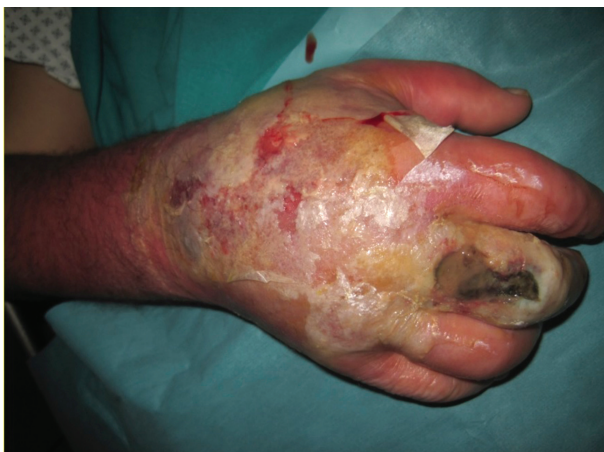

Figure 1. Dorsal and volar aspect of the hand at the admission to our E.R.

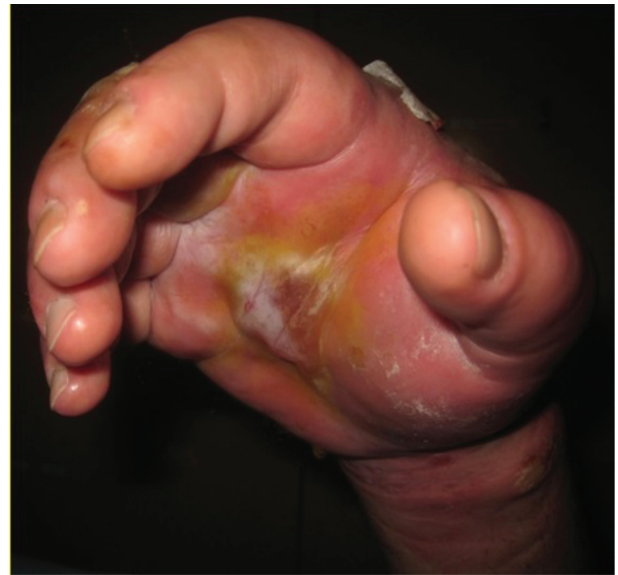

Figure 2. Dorsal and volar aspect of the hand at the admission to our E.R.

thus an E.V. antibiotic therapy has been promptly started (piperacillin/tazobactam and clindamycin).

Blood tests on entry, with regard to the LRINEC score, are reported in (Tab. 1):

The following day, as the symptoms kept worsening, the patient underwent a CT scan of his right hand; in view of the CT scan, we stated the need of a timely debridement, and transferred the patient to our ward.

Intraoperative findings were compatible with NF, with a malodorous “dishwater-like” pus, thrombotic subcutaneous blood vessels, and little-to none resistance to the digital detachment of subcutis from the extensor apparatus to the whole dorsum of the hand (Fig. 3).

The incision for pus drainage was centered dorsally on the third ray, extending to the distal forearm, together with a volar approach for the debridement of all the visible necrotic tissues from the first to the fifth ray. After

Table 1. Serum parameters of the patient on entry in the orthopaedic department with regard to the LRINEC score

WBC	8,2x10 ³ u/L	Glucose	14,37 mmol/L
Hb	11.8 g/dL	Serum Creatinine	58.3 micromol/L
Na+	123 mmol/L	CRP	181 mg/L
Total LRINEC			8

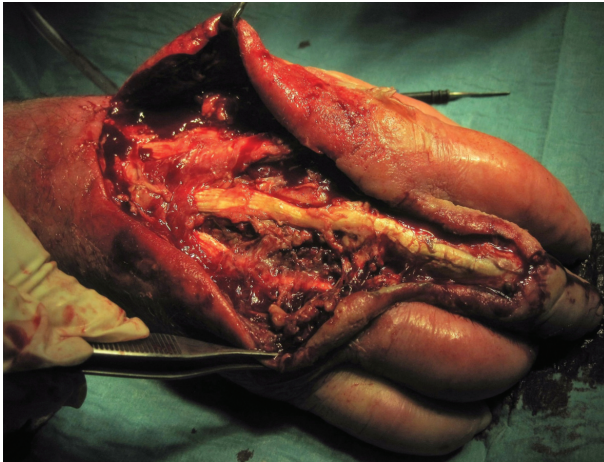


Figure 3. Intraoperative findings during the first debridement surgery (dorsal)

an abundant wash with hydrogen peroxide and sodium chloride solution, we decided not to close the wound with stitches in order to facilitate the drainage of pus.

Four days later, during the dressing of the wound, we noticed a bulge in the thenar area of the right hand,

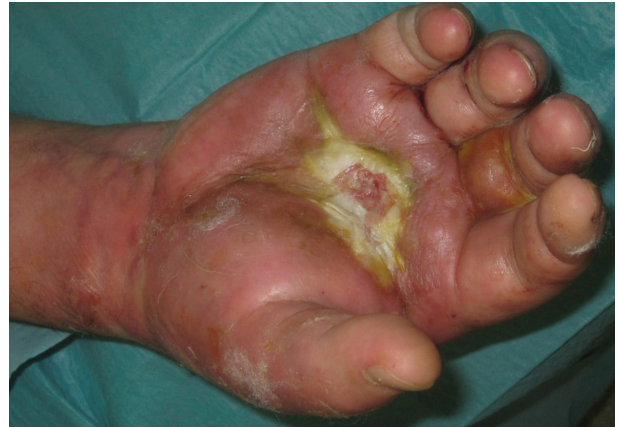

Figure 4. Septic collection (volar) at the 4th day after the first debridement.

compatible with a septic collection (Fig. 4). Therefore we opted for a second debridement with the excision of the whole extensor and flexor apparatus of the third ray (Fig. 5), and we sent a sample of this particulate material to the cultural exam.

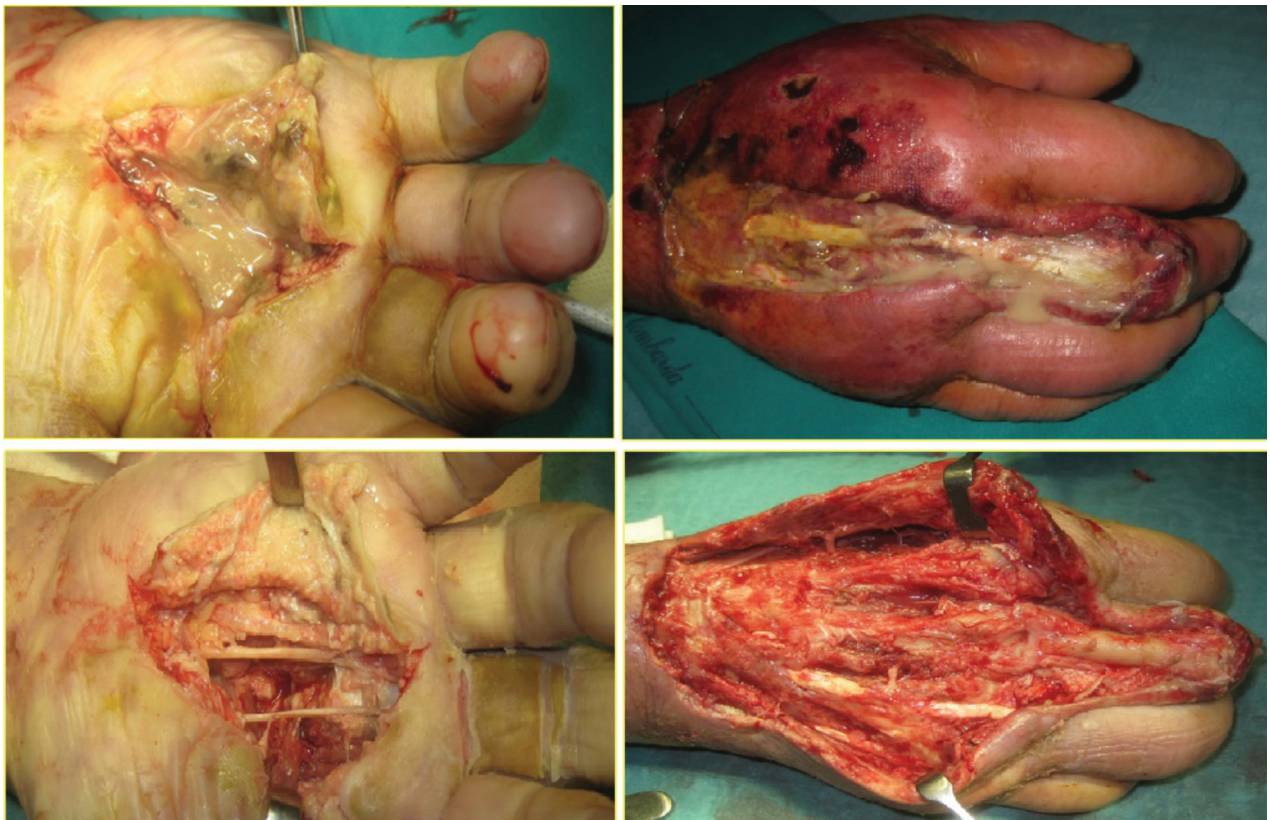


Figure 5. Intraoperative findings during the second debridement surgery and excision of the extensor and flexor apparatus of the third ray

The following day, one week from the admission, we received the laboratory result from the samples collected during the first debridement, which resulted positive for *Enterobacter Cloacae*.

Nine days later, the samples collected during the second debridement showed a positivity for a *Corynebacter*, so we shifted the current EV antibiotics therapy to Teicoplanin (400 mg x 2/die) and oral ciprofloxacin (750 mg x 2/die).

At the 25th day from the admission the patient underwent the third debridement surgery.

In anticipation of a surgical procedure for the coverage of the lesion with a posterior interosseous flap (P.I.F.) we prescribed an angiography of his right upper limb; then we took the patient to the O.R. in

order to amputate the third ray, whose function was severely impaired, and to perform a wedge osteotomy of the capitate and closure of the intermetacarpal space among second and fourth metacarpal bone with reabsorbable cerclages (Fig. 6). Together with these procedures we performed a coverage with a P.I.F. and a dermo-epidermic graft on the donor site (Fig. 7).

The normalization of inflammatory markers was noticed at 3 days from this last procedure; for this reason, at almost 40 days from his admission in our E.R., the patient has been released from the hospital.

At the last follow-up at 3,5 months, the patient reported a VAS of 1, and a grip strenght of 22,5 Kgs at the Jamar test (65% of the controlateral-non dominant hand) (Fig. 8).

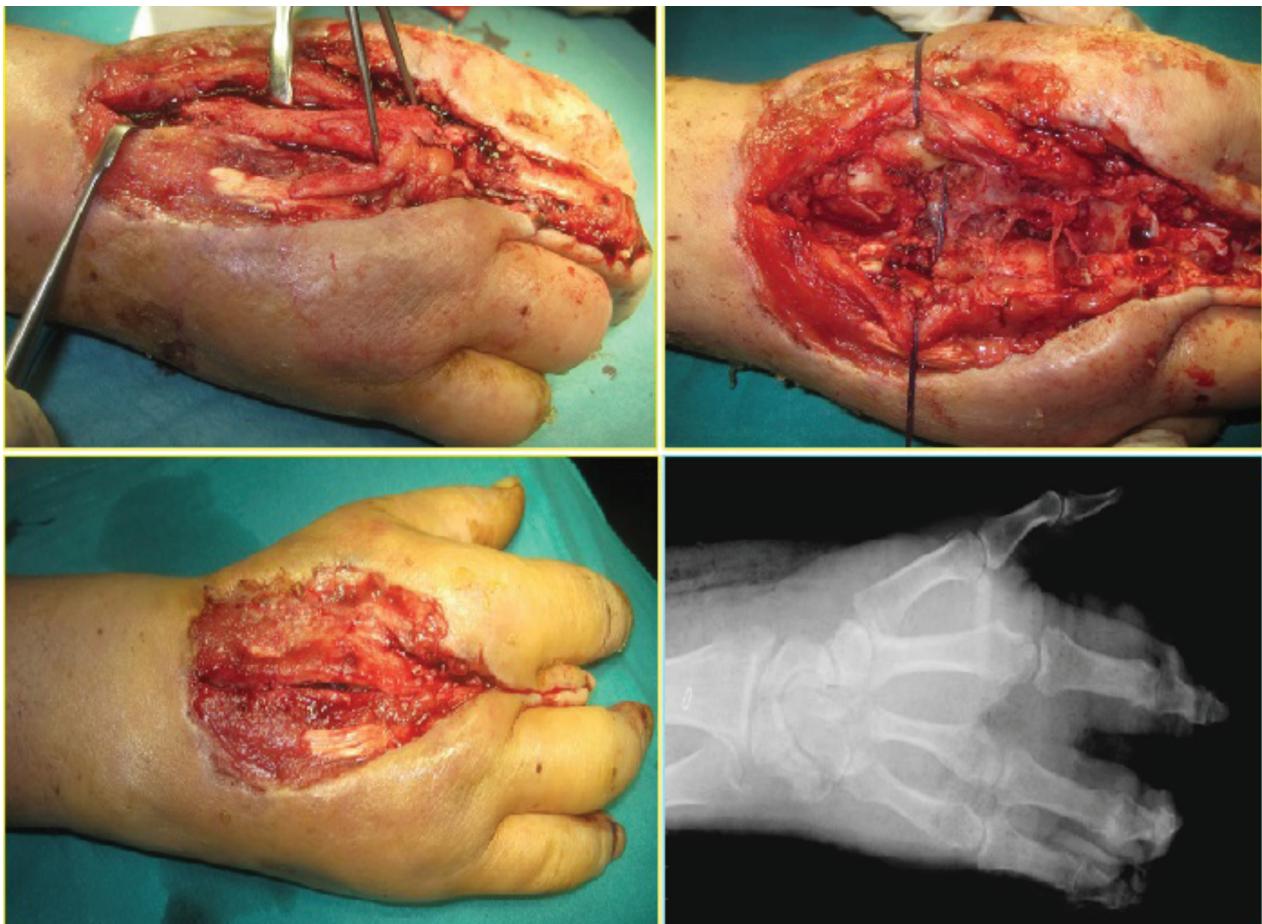


Figure 6. Sequence: isolation and excision of the third ray, capitate wedge osteotomy and closure of the corresponding web space with reabsorbable cerclages. On the lower right corner, post-op X ray

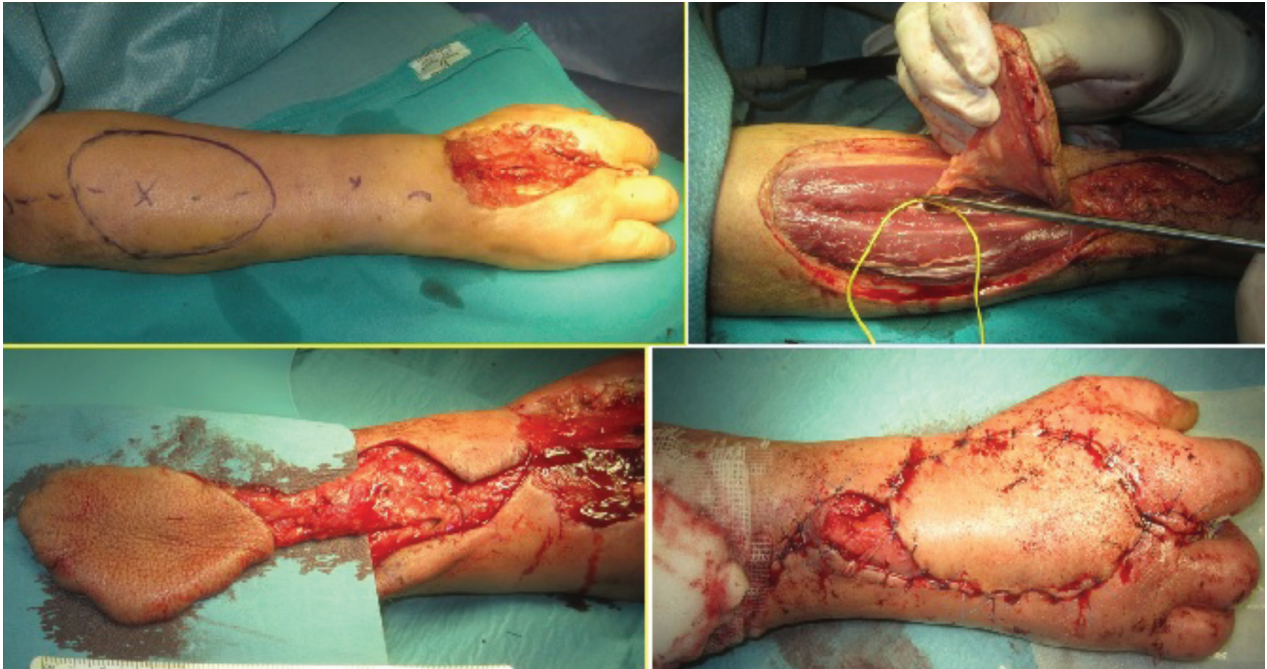

Figure 7. Sequence: skin marks, isolation of the posterior interosseous artery with a perforating vessel, and wound coverage with the posterior interosseous flap

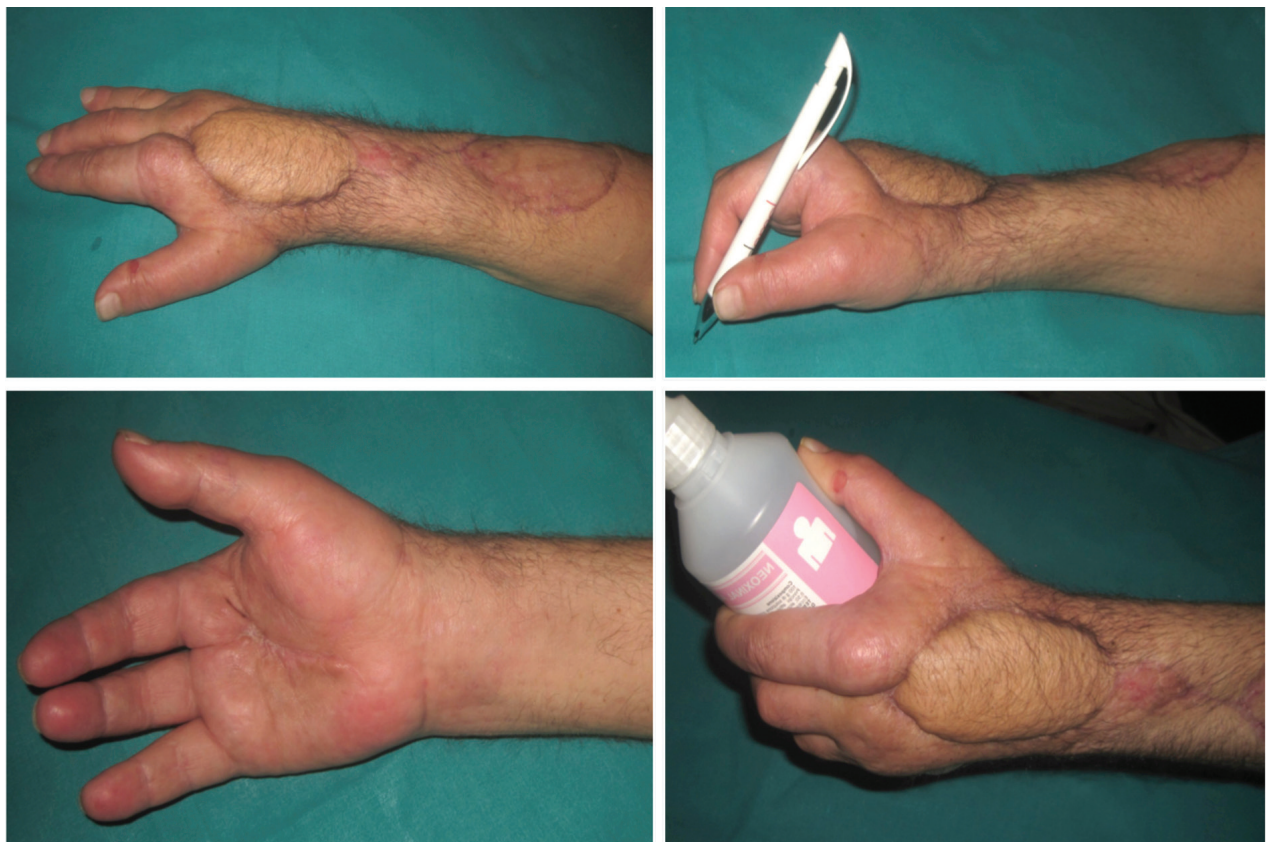

Figure 8. Last follow-up assessment at 3,5 months from the first surgery

Discussion

N.F. is a rare infectious disease, potentially lethal, usually developing on a polymicrobial aetiology, initially involving the muscular fascia and then secondarily spreading to muscular and subcutaneous tissues.

Diagnosis relies mainly on clinical findings and patient history, although laboratory and radiological findings may be a considerable support into early diagnosis of this condition.

The LRINEC score has proven to be an useful tool or the surgeon to direct the diagnosis based on clinical and laboratory parameters, although Burner et al. (16) observed an actual sensitivity of around 77%, lower than that calculated by Wong (11), in particular when used alone.

From a radiological point of view, Mc Gillicuddy et al. (17) developed a scoring system based on CT images which, by assigning scores to certain parameters (as presence of gas within the fascia -5 pts-, muscular and fascial edema -4 pts-, liquid collections - 3 pts-, lymphadenopathy -2 pts-, and subcutaneous edema -1 pt-), it allows to reach a sensitivity of 86% and specificity of 92% when the overall total score achieves more than 6 pts.

One of the crucial factors in the management of a patient affected by N.F. is time: survival rate lies approximately around 93% if the time between the admission and the first debridement does not exceed the 24 hours, decreasing dramatically to 75% at 48 hours (18).

In our case the time lapse between the indication to the first debridement and the surgery has been approximately of 26 hours; overall, time elapsed from the admission to the E.R. till the arrival in the O.R. has been around 42 hours.

International literature endorses that it takes on average 3 debridement procedures before reaching the stabilization of the clinical picture (as we noticed even in our case); amputation rate seemed to be variable between the 18% (19), the 21% (8), the 22,5% (18) and the 28% (20), although in this very last case the number of average procedures was reported to be 4.

The promptness of the debridement and his radicality have in all likelihood been the main factors that let us avoid the amputation of the patient's whole hand, limiting it just to his third ray.

The latter, deprived of the presence of flexor and extensor apparatus involved by the infection, has been removed; to overcome the disability following a ray amputation (inability in small objects grasping, weakening of the grip, presence of a visible gap between the II and III ray) (21), we performed secondarily a wedge-osteotomy of the capitate (procedure initially described by Iselin and Peze (22)); tissue coverage has been reached with a posterior interosseous flap (23), and the donor site covered with an autologous mesh-skin graft taken from the thigh.

References

1. Tocco I, Lancerotto L, Pontini A, Voltan A, Azzena B. "Synchronous" multifocal necrotizing fasciitis. *J Emerg Med* 2013; 45(6): e187-91.
2. El-Khani U, Nehme J, Darwish A, et al. Multifocal necrotizing fasciitis: an overlooked entity? *J Plast Reconstr Aesthet Surg* 2012; 65(4): 501-12.
3. Kaul R, McGeer A, Low DE, Green K, Schwartz B. Population-based surveillance for group A streptococcal necrotizing fasciitis: clinical features, prognostic indicators, and microbiologic analysis of seventy-seven cases. Ontario Group A Streptococcal Study. *Am J Med* 1997; 103(1): 18-24.
4. Mulla ZD, Gibbs SG, Aronoff DM. Correlates of length of stay, cost of care, and mortality among patients hospitalized for necrotizing fasciitis. *Epidemiol Infect* 2007; 135(5): 868-76.
5. van Stigt SF, de Vries J, Bijker JB, et al. Review of 58 patients with necrotizing fasciitis in the Netherlands. *World J Emerg Surg* 2016; 11-21.
6. Morgan MS. Diagnosis and management of necrotizing fasciitis: a multiparametric approach. *J Hosp Infect* 2010; 75(4): 249-57.
7. Mandell GL, Bennett JE, Dolin R. Principles and practice of infectious diseases. 7th. Philadelphia: Churchill Livingstone, 2010; 1307-8.
8. Angoules AG, Kontakis G, Drakoulakis E, Vrentzos G, Granick MS, Giannoudis PV. Necrotising fasciitis of upper and lower limb: a systematic review. *Injury* 2007; 38 Suppl 5: S19-26.
9. Davoudian P, Flint NJ. Necrotizing fasciitis. *Contin Educ Anaesth Crit Care Pain* 2012; 12: 245-50.
10. Ghafur A, Shareek PS. Skin and soft tissue infections. *Medicine Update* 2012; 22: 59-66.
11. Wong CH, Khin LW, Heng KS, Tan KC, Low CO. The LRINEC (Laboratory Risk Indicator for Necrotizing Fasciitis) score: a tool for distinguishing necrotizing fasciitis from other soft tissue infections. *Crit Care Med* 2004; 32(7): 1535-41.
12. Sarani B, Strong M, Pascual J, Schwab CW. Necrotizing

- fasciitis: current concepts and review of the literature. *J Am Coll Surg* 2009; 208(2): 279-88.
13. Stevens DL, Bryant AE. Necrotizing soft tissue infections. *N Eng J Med* 2017; 377(23): 2253-65
 14. Stoneback JW, Hak DJ. Diagnosis and management of necrotizing fasciitis. *Orthopedics* 2011; 34(3): 196.
 15. Mikić D, Takić-Radovanović T, Luković M, et al. Severe form of streptococcal necrotizing fasciitis of the upper limb—diagnostic and therapeutic challenge: A case report. *Vojnosanit Pregl* 2015; 72(8): 745-9.
 16. Burner E, Henderson SO, Burke G, Nakashioya J, Hoffman JR. Inadequate sensitivity of laboratory risk indicator to rule out necrotizing fasciitis in the emergency department. *Infectious Disease* 2016; 17(3): 333-6.
 17. McGillicuddy EA, Lischuk AW, Schuster KM, et al. Development of a computed tomography-based scoring system for necrotizing soft-tissue infections. *J Trauma* 2011; 70(4): 894-9.
 18. Wong CH, Chang HC, Pasupathy S, Khin LW, Tan JL, Low CO. Necrotizing fasciitis: clinical presentation, microbiology and determinants of mortality. *J Bone Joint Surg Am* 2003; 85-A(8): 1454-60.
 19. Mc Henry CR, Piotrowski JJ, Petrinic D, Malangoni MA. Determinants of mortality for necrotizing soft-tissue infections. *Ann Surg* 1995; 221(5): 558-65.
 20. Elliot DC, Kufera JA, Myers RA. Necrotizing soft-tissue infections: risk factors for mortality and strategies for management. *Ann Surg* 1996; 224(5): 672-83.
 21. O'Brien MS, Singh N. Surgical Technique Utilizing Suture-Button device for central Metacarpal Ray Resection. *J Hand Surg Am* 2016; 41(8): e247-50.
 22. Iselin F, Peze W. Ray centralization without bone fixation for amputation of the middle finger. *J Hand Surg Br* 1988; 13(1): 97-99.
 23. Zancolli EA, Angrigiani C. Posterior interosseous island forearm flap. *J Hand Surg Br* 1988; 13(2): 130-5.
-
- Received: 26 October 2018
Accepted: 10 December 2018
Correspondence:
Andrea Minini
Via M.G. Setti, 10 - Treviglio (BG) Italy
Tel. +39 340 82 82 729
E-mail: minini.andrea@gmail.com