

Fulminant hepatic failure: An unusual suspect

Nathalie Layios MD, PhD^{1,2}  | Dimitri Mathieu MD¹ | Romain Dumont MD¹ | Romain Gillard MD³

¹Department of Intensive Care, University Hospital of Liege, Liege, Belgium

²Laboratory of Cardiovascular Sciences, GIGA Institute, University Hospital of Liege, Liege, Belgium

³Department of Radiology, University Hospital of Liege, Liege, Belgium

Correspondence

Nathalie Layios, MD, PhD, Department of Intensive Care, University Hospital of Liege, Liege, Belgium.

Email: nathalie.layios@chuliege.be

1 | PATIENT PRESENTATION

A 66-year-old man was admitted to the emergency department for bradypsychia and asthenia. He had a history of alcohol consumption and epilepsy with no medical follow-up. Laboratory test results were compatible with acute liver failure and hyperammonemic encephalopathy: international normalized ratio, 3.35; fibrinogen, 2.25 g/L; total/direct bilirubin, 9.27/4.96 mg/dL; aspartate aminotransferase, 2595 U/L; alanine aminotransferase, 1958 U/L; ammonia, 125 µmol/L.

2 | DIAGNOSIS

2.1 | Inferior vena cava thrombosis

Axial (Figure 1A) and coronal (Figure 1B) contrast-enhanced computed tomography shows a 4-cm wide hepatic mass in the VII segment

(arrowheads) invading the right sub-hepatic vein (voided arrowheads) and inferior vena cava (IVC; voided arrows). The invaded veins are disproportionately enlarged for a cruric thrombus, which measures 14 cm in the cranio-caudal axis and extends to the right atrium (arrow). Transthoracic echocardiography (Figure 2) shows a bulky thrombus emerging at the atrio-caval junction. Several therapeutic options, such as in situ thrombolysis, fibrinolysis, and surgical resection, were discarded as first-line therapy because of the risks of thrombus fragmentation, secondary pulmonary embolism, and bleeding. Despite continuous infusion of therapeutic unfractionated heparin and supportive measures, the patient died a week later.

Elevated alpha-fetoprotein levels (33,460 µg/L) confirmed probable hepatocellular carcinoma causing intraluminal extension of tumor thrombosis into the IVC, which confers a very poor prognosis in the absence of curative surgical resection. Differential diagnoses, in the absence of congenital abnormalities of IVC, include primary leiomyosarcoma of the vessel wall or adjacent organ carcinoma causing extension of tumoral thrombosis, such as renal cell or adrenocortical carcinoma and retroperitoneal metastasis.^{1,2}

This is an open access article under the terms of the [Creative Commons Attribution-NonCommercial-NoDerivs](https://creativecommons.org/licenses/by-nc-nd/4.0/) License, which permits use and distribution in any medium, provided the original work is properly cited, the use is non-commercial and no modifications or adaptations are made.

© 2023 The Authors. *JACEP Open* published by Wiley Periodicals LLC on behalf of American College of Emergency Physicians.

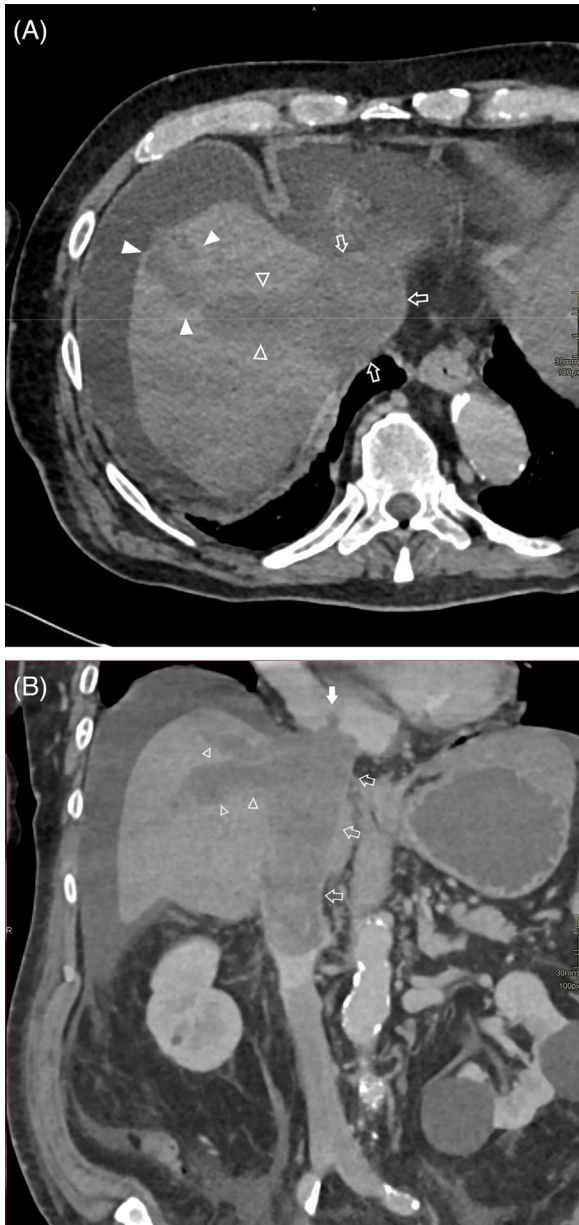

FIGURE 1 Axial (A) and coronal (B) contrast-enhanced computed tomography shows a 4-cm wide hepatic mass (arrowheads) invading the right sub-hepatic vein (voided arrowheads) and inferior vena cava (voided arrows). The invaded veins are enlarged, and the tumor thrombus extends to the right atrium (arrow). Peri-hepatic ascites are also present.

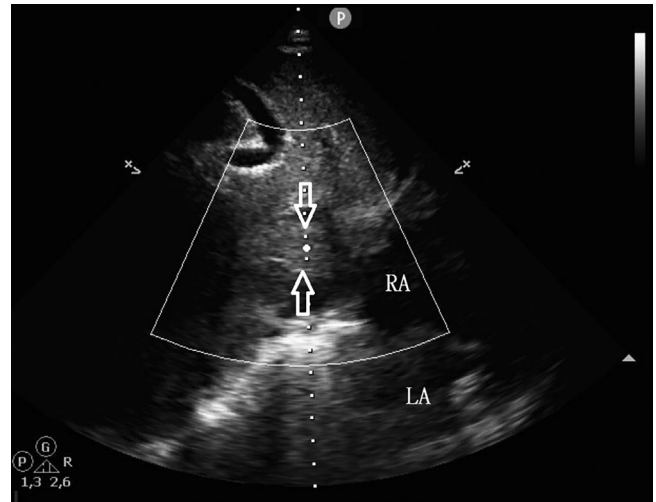


FIGURE 2 Bulky thrombus in the lower vena cava at the atrio-caval junction between the arrows. LA, left atrium; RA, right atrium.

ORCID

Nathalie Layios MD, PhD  <https://orcid.org/0000-0002-1360-4917>

REFERENCES

1. Cuevas C, Raske M, Bush WH, et al. Imaging primary and secondary tumor thrombus of the inferior vena cava: multi-detector computed tomography and magnetic resonance imaging. *Curr Probl Diagn Radiol.* 2006;35(3):90-101.
2. Alkhoul M, Morad M, Narins CR, Raza F, Bashir R. Inferior vena cava thrombosis. *JACC Cardiovasc Interv.* 2016;9(7):629-643.

How to cite this article: Layios N, Mathieu D, Dumont R, Gillard R. Fulminant hepatic failure: An unusual suspect. *JACEP Open.* 2023;4:e12912. <https://doi.org/10.1002/emp2.12912>