

Received: 2020.12.17

Accepted: 2021.02.04

Available online: 2021.02.18

Published: 2021.03.27

A Case of *Dialister pneumosintes* Bacteremia-Associated Neck and Mediastinal Abscess

Authors' Contribution:

Study Design A
Data Collection B
Statistical Analysis C
Data Interpretation D
Manuscript Preparation E
Literature Search F
Funds Collection G

EF 1 **Sonia Mannan**
E 1 **Tahir Ahmad**
E 2 **Asma Naeem**
E 3 **Vinod Patel**

1 Department of Cardiology, George Eliot Hospital NHS Trust, Nuneaton, U.K.
2 Acute Medical Unit, George Eliot Hospital NHS Trust, Nuneaton, U.K.
3 Department of Endocrinology and Diabetes Mellitus, George Eliot Hospital NHS Trust, Nuneaton, U.K.

Corresponding Author: Sonia Mannan, e-mail: Soniam0808@gmail.com

Conflict of interest: None declared

Patient: Female, 30-year-old
Final Diagnosis: *Dialister pneumosintes* bacteraemia associated mediastinal and neck abscess
Symptoms: Diarrhoea • fever • vomiting
Medication: —
Clinical Procedure: Incision and drainage
Specialty: General and Internal Medicine


Objective: Rare disease
Background: *Dialister pneumosintes* is a suspected periodontal pathogen. It can affect different parts of the body either by hematogenous transmission or regional spread. Here, we report a case of 30-year-old previously healthy woman diagnosed with mediastinal and neck abscess caused by this pathogen.

Case Report: A 30-year-old woman presented with a 1-day history of fever, vomiting, and diarrhea. She was on her last dose of a 2-week course of oral antibiotic for suspected dental abscess. On admission, parenteral broad-spectrum antibiotic was started for sepsis of unknown source. Because of intermittent spike of high temperature despite being on an antibiotic, cross-sectional imaging was performed, which revealed a superior mediastinal abscess with extension in the neck. She was referred to the ENT surgeon for incision and drainage of the collection. However, the procedure was complicated by injury to the right internal jugular vein. Her postoperative period was also convoluted with the development of pulmonary embolism, followed by deep vein thrombosis of the right upper limb. Her pus polymerase chain reaction test detected 16s rRNA gene, suggestive of gram-negative anaerobic bacilli, and anaerobic blood culture grew *Dialister pneumosintes*. After a prolonged course of illness and antibiotic treatment, she recovered well, and now is back to her normal activities.

Conclusions: Potential life-threatening complications may develop from periodontal infection by this microorganism. In patients being treated for sepsis of unknown origin, not responding to antibiotic treatment, and with a history of recent periodontal infection, a deep-seated abscess needs to be considered.

Keywords: 16s rRNA • Mediastinal Diseases • Periodontal Diseases • Sepsis

Full-text PDF: <https://www.amjcaserep.com/abstract/index/idArt/930559>




1410



—



3



16



Background

Dialister pneumosintes is a non-spore-forming, non-motile, non-fermentative, gram-negative anaerobic bacilli [1]. It is reported to occur as normal flora in the nasopharynx, oral cavity, intestine, and vagina [2,3]. This bacterium was first detected in 1921 from the nasopharyngeal secretion of patients during the influenza epidemic of 1918-1919, and was initially named *Bacterium pneumosintes* [4].

We present a case of *Dialister pneumosintes*-associated mediastinal and neck abscess in a previously healthy young patient who was getting treatment for a possible dental abscess. To the best of our knowledge, this is the first case report of mediastinal and neck abscess caused by this organism.

Case Report

A 30-year-old woman with no significant past medical history presented to the Emergency Department with a 1-day history of fever (38°C), vomiting, and diarrhea. Two weeks prior to admission, she visited her general practitioner for tooth ache, and she was prescribed a 14-day course of oral antibiotic (clarithromycin 500 mg BD) for a suspected dental abscess. On examination, she was tachycardic and febrile, with nontender, non-erythematous generalized swelling of the right side of her face. She had no lymphadenopathy or organomegaly. Her heart sounds were normal, and the chest was clear on auscultation.

Initial investigations showed neutrophilic leucocytosis (white blood cell 29.06×10^9 /liter, reference value 4.00 - 11.00×10^9 /liter; neutrophil 27.55×10^9 /liter, reference value 2.00 - 7.00×10^9 /liter) with high C-reactive protein (154 milligram/liter, reference value <11 milligram/liter) and lactate (3 millimole/liter). Her chest radiograph was normal (Figure 1). Considering the raised inflammatory marker and septic presentation, she was started on intravenous piperacillin and tazobactam (4.5 grams TDS) combination antibiotic. After 48 hours of initiation of broad-spectrum antibiotic, she was still having intermittent high-grade fever. Preliminary blood and stool cultures grew no organism.

After that, she was re-evaluated and an urgent CT scan of the neck-thorax-abdomen-pelvis was performed, which detected a septated, peripherally enhancing, anterior mediastinal abscess measuring $5.5 \times 3.2 \times 6$ cm in transverse, antero-posterior, and craniocaudal dimensions, respectively, with extension into the lower neck up to the level of the thyroid gland (Figure 2A, 2B). An X-ray orthopantomogram showed lucency around the lower premolar tooth, in keeping with the clinical suspicion of abscess formation (Figure 3). Given the CT scan finding, while waiting for the incision and drainage, parenteral metronidazole (500 milligram TDS) was added, as advised by the microbiologist.

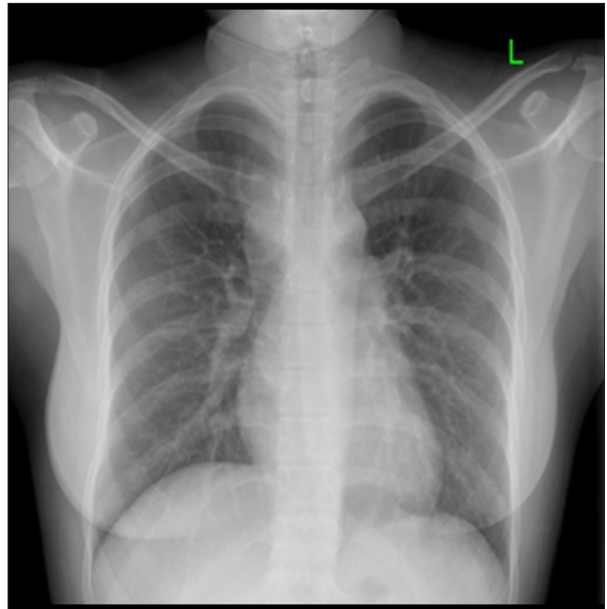


Figure 1. Chest radiograph (posteroanterior view). Chest X-ray posteroanterior view showing normal study.

Therefore, urgent referrals were sent to the Maxillofacial, ENT, and Cardio-thoracic Departments of the affiliated university hospital. After inter-departmental discussion, the patient was transferred under the ENT specialty. An emergency incision and drainage of the mediastinal and neck abscess was performed under general anesthesia. The procedure was complicated by massive hemorrhage. Suturing of the bleeding point was attempted without success owing to its unidentified source. Bleeding was controlled conservatively with pressure dressing. Major hemorrhage protocol was activated, and she was transfused with 7 units of red blood cells and 7 units of fresh frozen plasma. She was transferred to the Intensive Therapeutic Unit (ITU), where she remained intubated for 3 postoperative days.

Her pus sample was sent for culture and sensitivity. Auramine stain of pus was negative for acid-fast bacilli. Both aerobic and anaerobic cultures of the pus, including the culture for *Mycobacterium tuberculosis*, were sterile. Gram film of the pus sample showed profuse leucocytes. Pus polymerase chain reaction (PCR) testing for *Mycobacterium tuberculosis* and *Mycobacterium avium* complex were negative. Her HIV test result was also negative. However, PCR testing of pus detected 16s rRNA gene, suggestive of gram-negative anaerobic bacilli.

Gradually, she was stepped down from the ITU. A post-procedure CT angiogram of the neck and thoracic area detected thrombus inside and surrounding the right internal jugular vein, suggestive of an intra-operative bleeding site, and acute pulmonary embolism in the right-side lobar branch of the pulmonary artery. It also revealed minimal residual collection of

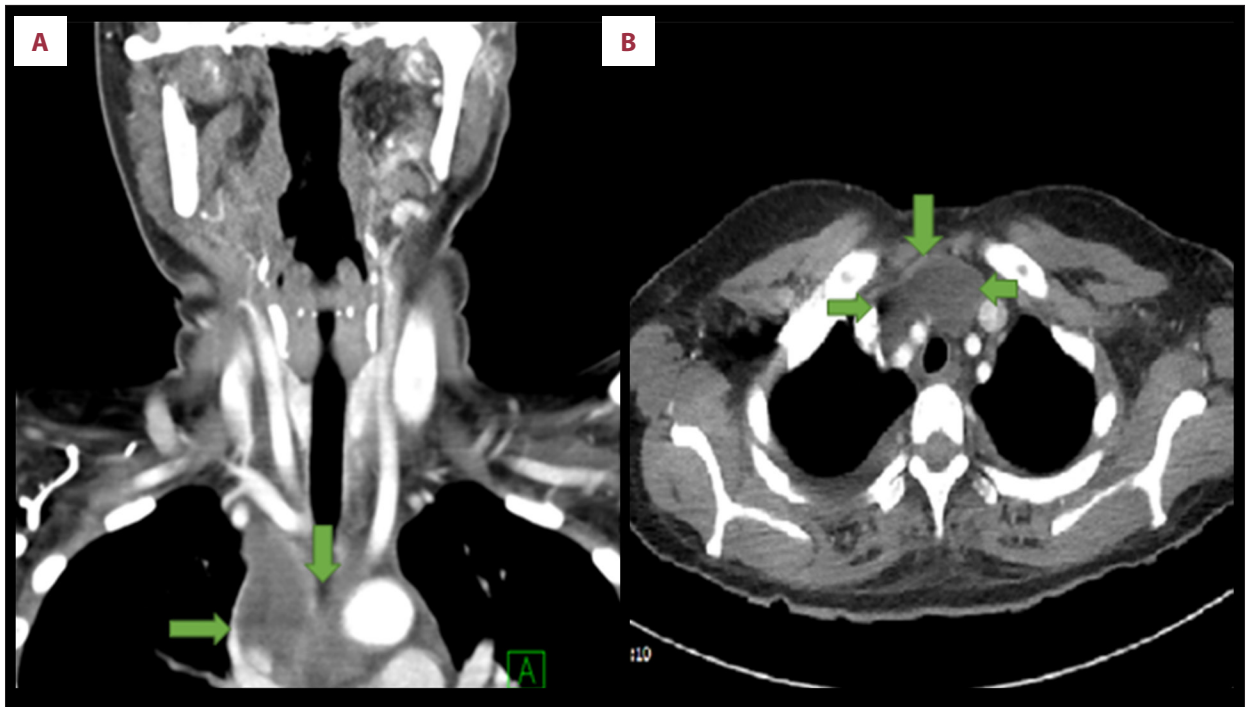


Figure 2. Computed tomography (CT) neck-thorax coronal (A) and axial (B) view. CT neck-thorax coronal (A) and axial (B) view showing septated peripherally enhancing anterior-superior mediastinal collection (green arrows).

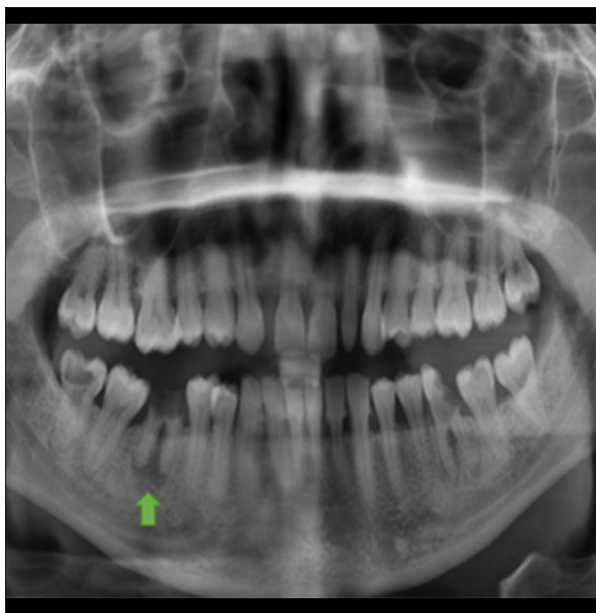

Figure 3. X-ray orthopantomogram. X-ray orthopantomogram showing lucency around the lower premolar root, consistent with the clinical suspicion of abscess formation (green arrow).

pus in the right supraclavicular space extending into the right superior mediastinum. Hence, she was treated with subcutaneous low-molecular-weight heparin (LMWH), which was later changed to oral anticoagulant (edoxaban 30 milligram OD).

Although her inflammatory markers were decreasing, she remained tachycardic with intermittent episodic high temperature. After discussion with the microbiologist, her antibiotics were changed to meropenem (1 gram iv TDS), vancomycin (1 gram iv BD), and oral fluconazole (50 milligram OD). On her seventh postoperative day, she developed swelling of her right upper limb due to deep vein thrombosis of her upper limb veins revealed by compression venography.

Eventually, one of her initial anaerobic blood culture sample, which was sent on the day of her admission, grew *Dialister pneumosintes*. Her antibiotic was changed to amoxicillin plus clavulanic acid (1.2 grams TDS) and metronidazole (500 milligrams TDS). Her inflammatory markers gradually came down. A repeat CT scan of her neck and thorax showed reduction in the amount of collection in the right supraclavicular fossa and superior mediastinum. She remained clinically well and afebrile. At the time of hospital discharge, she was prescribed a further 21-day course of oral antibiotic amoxicillin with clavulanic acid (625 milligrams TDS) and metronidazole (400 milligrams TDS).

A follow-up ultrasound scan, which was done 2 weeks after her discharge, showed absence of any residual collection in the neck. Four weeks later, she was seen in the Outpatient Department, where she reported she was feeling significantly better. At present, she is waiting for Venous Thromboembolism (VTE) Clinic follow-up.

Discussion

Initially, we were unable to identify the source of infection due to non-specific presentation of symptoms and signs. Computed tomography revealed a mediastinal and neck abscess, and an orthopantomogram revealed a dental abscess. However, there was no evidence of descending transmission of infection from the orthodontic source. In this case, it was a hematogenous spread of infection from the dental abscess, and *Dialister pneumosintes* bacteremia of periodontal origin has been documented in the literature [5,6]. A study of 135 systemically healthy dentistry patients revealed *D. pneumosintes* was the pathogenic organism in 83% of cases of severe periodontitis and 19% of cases of slight periodontitis [7]. We were unable to confirm that *D. pneumosintes* was the pathogenic organism causing her tooth infection, as we did not cultivate any specimen or aspirate from her tooth. Based on the characteristics of the pathogen and the nature of the infection, and with the absence of any other source, it is likely that the neck and mediastinal abscess was due to bacteremia from a periodontal infection.

Currently, there are 4 known species in *Dialister* genus, consisting of 135 strains; however, *D. pneumosintes* and *D. micraerophilus* are commonly encountered species [8]. *D. pneumosintes* is difficult to grow in the conventional culture media and the 16s rRNA-based PCR assay has been developed for the detection of this pathogen [9]. This microorganism has been isolated from periodontitis [7], gingivitis, root canal infection [10], sub-gingival plaque [9], human bite wound infection [11], respiratory tract, head and neck infection [3], and vaginal infection [12]. Severe infective complications have been reported, including brain abscess [13] and liver abscess [5] with a suspected dental source of origin.

Our patient developed pulmonary embolism and internal jugular vein (IJV) thrombosis following a major bleed during the intervention owing to injury to the IJV. Her pre-operative CT scan was not suggestive of any thrombosis. Two cases have been

reported as *D. pneumosintes* bacteremia-associated thrombosis. The first was suppurative thrombosis of ovarian vein in a young woman [12] and the second case was cavernous sinus thrombosis in an immunocompromised elderly woman in association with other anaerobes [14].

The mortality rate of patients with mediastinitis is up to 40% despite aggressive treatment with broad-spectrum antibiotics [15]. Frequently isolated organisms in culture of the deep neck and mediastinal infection are *Streptococcus*, *Bacteroides*, *Staphylococcus*, *Peptostreptococcus*, *Pseudomonas*, *E. coli*, *Klebsiella*, and *H. influenzae* [16]. Deep neck and mediastinal abscess are rare complications of dental abscess, which demand urgent surgical intervention with antibiotic treatment.

Conclusions

Both immunocompetent and immunocompromised individuals can be affected by *Dialister pneumosintes*. Patients who present with tooth ache who have been prescribed antibiotics need appropriate follow-up to monitor the response to therapy or any development of complications. Likewise, patients with septic presentation with a history of dental infection and who are not responding to antibiotic treatment needs urgent imaging to assess for presence of a deep-seated abscess. Due to the high mortality rate, an emergency surgical approach is necessary once the diagnosis of mediastinal abscess is confirmed.

Acknowledgement

Department of ENT and Infectious Disease, University Hospitals Coventry and Warwickshire.

Department and Institution Where Work Was Done

Acute Medical Unit, George Eliot Hospital NHS Trust; ENT Department and Infectious Disease Department, University Hospitals Coventry and Warwickshire.

References:

1. Siqueira JF, Rôças IN. *Dialister pneumosintes* can be a suspected endodontic pathogen. *Oral Surg Oral Med Oral Pathol Oral Radiol Endod.* 2002;94(4):494-98
2. Evaldson G, Carlström G, Lagrelus A, et al. Microbiological findings in pregnant women with premature rupture of the membranes. *Med Microbiol Immunol.* 1980;168(4):283-97
3. Holdeman LV, Kelley RW, Moore WEC. In: Krieg NR, Holt JG, editors. *Bacteriodes pneumosintes*. *Bergey's manual of Systematic bacteriology*. Vol. 1. Baltimore: Williams & Wilkins Co.; 1984; 628-29
4. Olitsky PK, Gates FL. Experimental studies of the nasopharyngeal secretions from influenza patients: IV. anaerobic cultivation. *J Exp Med.* 1921;33(6):713-29
5. Soeiro C, Quilici IR, Legoff A, et al. Hepatic abscess due to *Dialister pneumosintes* – A case report. *Anaerobe.* 2019;59:35-37
6. Kogure M, Suzuki H, Ishiguro S, et al. *Dialister pneumosintes* bacteremia caused by dental caries and sinusitis. *Intern Med (Tokyo, 1992).* 2015;54(6):663-67
7. Contreras A, Doan N, Chen C, et al. Importance of *Dialister pneumosintes* in human periodontitis. *Oral Microbiol Immunol.* 2000;15(4):269-72
8. Morio F, Jean-Pierre H, Dubreuil L, et al. Antimicrobial susceptibilities and clinical sources of *Dialister* species. *Antimicrob Agents Chemother.* 2007;51(12): 4498-501
9. Doan N, Contreras A, Flynn J, et al. Molecular identification of *Dialister pneumosintes* in subgingival plaque of humans. *J Clin Microbiol.* 2000;38(8):3043-47
10. Tani-Ishii N, Wang C-Y, Tanner A, et al. Changes in root canal microbiota during the development of rat periapical lesions. *Oral Microbiol Immunol.* 1994;9(3):129-35
11. Goldstein EJ, Citron DM, Finegold SM. Role of anaerobic bacteria in bite-wound infections. *Rev Infect Dis.* 1984;6:S177-83
12. Lepargneur JP, Dubreuil L, Levy J. Isolation of *Dialister pneumosintes* isolated from a bacteremia of vaginal origin. *Anaerobe.* 2006;12(5):274-75
13. Rousée JM, Bermond D, Piémont Y, et al. *Dialister pneumosintes* associated with human brain abscesses. *J Clin Microbiol.* 2002;40(10):3871-73
14. Matsumura H, Suzuki H, Ito Y, et al. A case of cavernous sinus thrombosis caused by *Dialister pneumosintes*, *Slackia exigua* and *Prevotella baroniae*. *JMM Case Reports.* 2014;1(3):0.002683
15. Jarboui S, Jerraya H, Moussi A, et al. [Descending necrotizing mediastinitis of odontogenic origin.] *Tunis Med.* 2009;87:770-75 [in French]
16. McDowell RH, Hyser MJ. *Neck abscess.* Treasure Island (FL): Statpearls Publishing, 2020