



Management of prolonged penile ring entrapment in an Indonesian tertiary hospital: A case report and literature review

Anak Agung Patriana Puspaningrat, Yudhistira Pradnyan Klopung, Johan Renaldo*

Department of Urology, Faculty of Medicine, Universitas Airlangga, Dr. Soetomo General-Academic Hospital, Mayjen Prof. Dr. Moestopo 6-8, Airlangga, Gubeng, Surabaya, East Java, 60286, Indonesia

ARTICLE INFO

Keywords:

Penile ring entrapment
Electric grinder
Continuous saline injection

ABSTRACT

Penile ring entrapment is a rare urological emergency with severe functional consequences if not treated in time. It may be challenging for physicians in limited-resource settings without a standardized intervention method. An electrical grinder is the most commonly used tool for ring removal. However, in prolonged cases, additional post-removal interventions may be necessary. We report a prolonged penile ring entrapment case in an Indonesian tertiary hospital.

1. Introduction

Penile ring entrapment is a rare urological emergency that could cause mechanical and vascular complications.¹ Its use during intercourse is frequently found in adults or adolescents to sustain erection. A prolonged entrapment of more than 30 minutes could lead to irreversible damage due to edema and ischemia. Therefore, urgent intervention is vital. Several patients may not be admitted to the emergency room in time due to a lack of awareness or shame. Although there is no universally established method for penile strangulation management, ring cutting using an electrical grinder is the most commonly used method.² This case report aimed to report a prolonged penile ring entrapment and discuss its management in an Indonesian tertiary hospital.

1.1. Case presentation

38 years-old-male came to the emergency department due to severe penile pain and swelling of the penis (Fig. 1A). The pain started 10 h before admission after a ring that he put on his penis could not be removed. He can still urinate, even though there is resistance at the beginning of urination.

The patient had put a metal ring on his penis as an experiment on the previous day. At first, it was possible for him to take it off and put. However, it got stuck at some point, and his penis started to hurt. After ten hours without any reduction in now, a swollen penis, he decided to look for help.

There was no fever, nausea, vomiting, hematuria, low back pain, and history of urinary stones found in the patient. He also denied a history of diabetes mellitus and hypertension. He had a history of psychiatric treatment 20 years ago but never controlled. A history of drug and psychotropic consumption was denied.

However, since his COVID-19 rapid test was reactive, the ring entrapment was released using an electric grinder (Fig. 1B) followed with removal using pliers (Fig. 1C) in the isolated emergency department. This procedure worked successfully without further intervention (Fig. 1D). The cystoscopy procedure was not done because the patient had no complaint of lower urinary tract symptoms, urinary retention, and suspicion of tissue necrosis prior to admission and during follow-up sessions, rendering no further indication of hospitalization. Psychiatric consultation revealed a borderline IQ observation diagnosis, and he was given supportive psychotherapy. The patient is then scheduled for a nasopharyngeal swab at the COVID-19 polyclinic after a pulmonology consultation due to suspected asymptomatic COVID-19 with reactive rapid test results.

2. Discussion

Penile ring entrapment has a poor prognosis due to delayed admission.³ A prolonged decrease in venous return can eventually lead to penile distal edema, strangulation, compromised arterial supply, and penile tissue damage. Several hours of impaired circulation can cause ischemic necrosis, urinary retention, tissue fibrosis, and even

* Corresponding author.

E-mail addresses: patriana.ptty@yahoo.com (A.A.P. Puspaningrat), yudhistira.pradnyan.klopung-2020@fk.unair.ac.id (Y.P. Klopung), joeurologi@gmail.com (J. Renaldo).

<https://doi.org/10.1016/j.eucr.2022.102202>

Received 19 June 2022; Received in revised form 15 August 2022; Accepted 20 August 2022

Available online 8 September 2022

2214-4420/© 2022 The Authors. Published by Elsevier Inc. This is an open access article under the CC BY-NC-ND license (<http://creativecommons.org/licenses/by-nc-nd/4.0/>).

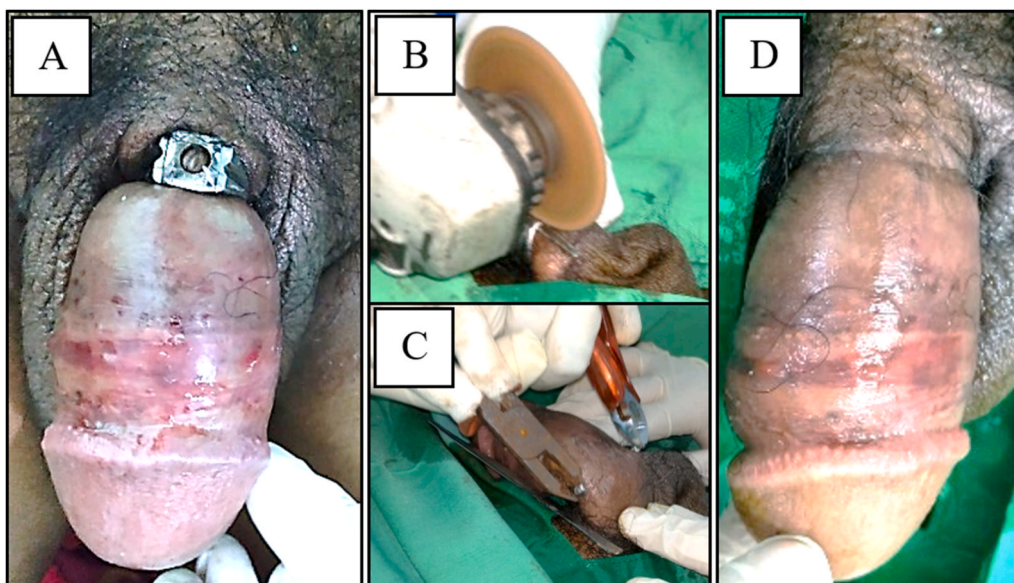


Fig. 1. 1A Presentation on arrival: penile strangulation by metal ring. 1B Release of ring entrapment. 1C Ring removal process using an electric grinder. 1D Post intervention: penile condition post ring entrapment release.

Table 1
Degree classification of penile ring entrapment.

System	Grade 0	Grade 1	Grade 2	Grade 3	Grade 4	Grade 5
Sawant et al.	No urethral injury	Partial division of corpus spongiosum + urethrocutaneous fistula	Complete division of corpus spongiosum + constriction of corpus cavernosum	Gangrene and amputation		
Bhat et al.		Edema distal to penis	Grade 1 + decreased distal penile sensation	Grade 1 + loss of distal penile sensation	Grade 3 + complete separation of corpus cavernosa	Gangrene or amputation
Dawood et al.		Superficial injury with distal edema	Injury to corpora or urethra	Gangrene, amputation, fistula or separation of corpora		

multi-organ failure due to septic shock.^{2,3} The patient was admitted due to swelling and entrapment of the penis following a penile insertion into a metallic ring. It was classified as first degree based on the Bhat and Dawood criteria (Table 1).²

There is no universally accepted method of treating penile strangulation. Metal cutting required heat. However, to prevent burns, the metal must be cooled. The penis must be protected during cutting, although access is difficult due to a narrow gap between the metal and the penile skin. Penile ring entrapment removal procedures are generally performed by urologists,⁴ but the involvement of other fields may be necessary.^{1,4} Grade 1 and 2 are not associated with urethral trauma and can be managed with temporary urethral catheterization to reduce penile edema and pain.^{1,3}

The penile ring entrapment was removed with an electric grinder and continuous saline injection to reduce heat. The metal plate was inserted between the ring and penile skin to prevent burn or pressure injury. There was no iatrogenic trauma reported. The patient underwent psychiatry consultation, where a borderline intellectual function was established as the diagnosis. Prior to ring removal, there was no urinary retention, necrosis, decreased penile sensation, abscess, or amputation of the penis. The patient was immediately discharged from the hospital after ring removal procedures. In cases where the onset of injury occurs within a few hours, the penile function may still be preserved, as reported by Rahmita et al.⁵

3. Conclusion

Penile ring entrapment is a urological emergency that can lead to

ischemic complications such as tissue necrosis or injury, sexual dysfunction, and urinary tract disorders if not managed immediately. The main treatment goal is to maintain organ function with the least complications. An adequate treatment in collaboration with the Facility Maintenance Unit experts may quickly relieve penile strangulation without causing iatrogenic trauma. The patient had grade 1 injury and mild early complication. Psychiatric assessment may be necessary in several cases.

Formatting of funding sources

This research did not receive any specific grant from funding agencies in the public, commercial, or not-for-profit sectors.

Acknowledgements

None.

References

1. Bhat G. Penile entrapment: a case where innovation is the need of the hour. *Acta Med Int.* 2018;5:90. https://doi.org/10.4103/ami.ami_87_17.
2. Dawood O, Tabibi S, Fiuk J, et al. Penile ring entrapment - a true urologic emergency: grading, approach, and management. *Urol Ann.* 2020;12:15-18. https://doi.org/10.4103/UA.UA_16_19.

3. Ichaoui H, Sallami S, Samet A, et al. Strangulation of the penis by a metallic ring: prevention is better than cure. *Case Rep Urol*. 2018;1–4. <https://doi.org/10.1155/2018/1725752>, 2018.
4. Koifman L, Hampl D, Silva MI, et al. *Treatment Options and Outcomes of Penile Constriction Devices*. vol. 45. 2019:384–391. <https://doi.org/10.1590/S1677-5538.IBJU.2018.0667>.
5. Rahmita MM, Parikesit D, Widia F. Penile entrapment by metal ring: case reports of effective non-surgical management. *Urol Case Rep*. 2020;33, 101387. <https://doi.org/10.1016/j.eucr.2020.101387>.