



## Inflammation and Infection

## Tuberculous Granuloma in the Scrotal Skin After Intravesical Bacillus Calmette-Guerin Therapy for Bladder Cancer: A Case Report



Hiroshi Shimura, Tatsuya Ihara, Takahiko Mitsui\*, Masayuki Takeda

Department of Urology, University of Yamanashi Graduate School of Medical Science, Chuo city, Yamanashi, Japan

## ARTICLE INFO

## Article history:

Received 21 September 2016

Accepted 1 November 2016

## Keywords:

Tuberculous granuloma

Scrotum

BCG

Bladder

Carcinoma

## ABSTRACT

Rare cases of tuberculous urinary tract or genital infection caused by intravesical Intravesical Bacillus Calmette-Guerin (BCG) instillation therapy have been reported. We encountered a patient with tuberculous granuloma in the scrotal skin after intravesical BCG therapy for bladder cancer. There was evidence of infection in the scrotal skin, but not in the epididymis. To the best of our knowledge, this is the first report of tuberculous granuloma in the scrotal skin without epididymitis after intravesical BCG therapy. In our case, lower urinary tract symptoms such as the terminal dribbling of urine appear to support the theory of direct BCG inoculation.

© 2016 The Authors. Published by Elsevier Inc. This is an open access article under the CC BY-NC-ND license (<http://creativecommons.org/licenses/by-nc-nd/4.0/>).

## Introduction

Intravesical Bacillus Calmette-Guerin (BCG) instillation therapy is commonly used in the treatment of bladder carcinoma *in situ* (CIS) and prophylaxis to prevent the recurrence of non-muscle-invasive bladder cancer. However, complications such as low grade fever, fatigue, and irritative bladder symptoms are associated with this therapy. Rare cases of systemic tuberculous infections such as pneumonitis and hepatitis or local tuberculous infections including granulomatous prostatitis, balanoposthitis, and epididymitis have been reported. These infections occur because BCG is a living organism.

Inflectional findings in the scrotal skin have been observed after intravesical BCG instillation as a result of epididymitis. We encountered a case of tuberculous granuloma in the scrotal skin, but not in the epididymitis after intravesical BCG therapy for bladder cancer. We herein present our rare case of tuberculous infection in the scrotal skin, which may have been caused by direct BCG inoculation, along with a discussion of the literature.

## Case report

A 74-year-old man presented to our institution with a right scrotal nodule with rubor. He was not diabetic and had no history of tuberculosis. However, he had a voiding dysfunction due to benign prostate hypertrophy and received a long-term treatment with

medication. At 64 years old, he was incidentally diagnosed with a bladder tumor and underwent transurethral resection for bladder tumor (TURBT). The pathological histology was non-invasive papillary urothelial carcinoma. He subsequently underwent TURBT six more times over ten years due to the recurrence of bladder cancer. The pathological histology each time was non-muscle-invasive papillary urothelial carcinoma, with the exception of the 7th pathological diagnosis, which was CIS.

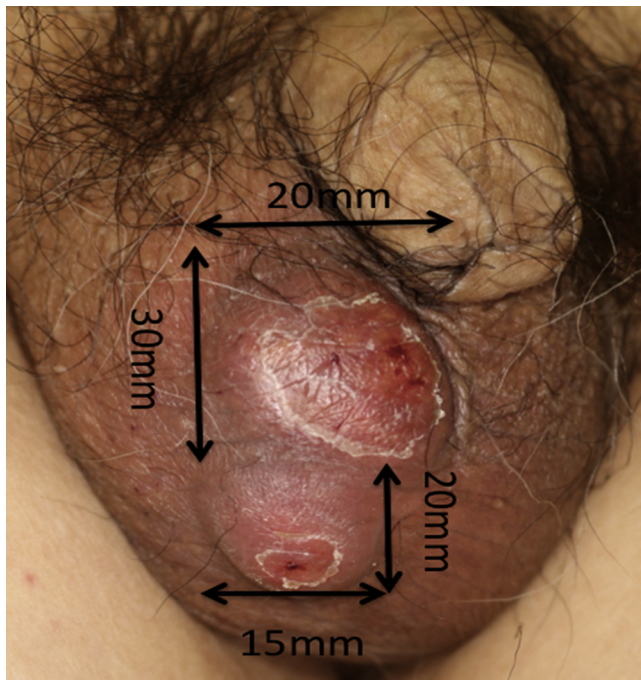
After the 7th TURBT, we selected intravesical BCG instillation therapy in an attempt to prevent the frequent recurrence of non-invasive bladder cancer. The patient received intravesical instillation therapy of BCG (80 mg) once a week for 8 weeks without any adverse complications. However, 4 weeks after the last instillation, he noted a cutaneous nodule on the right scrotum and visited our hospital.

He was afebrile with a good general condition. Two cutaneous nodules with rubor were detected on the right scrotum (Fig. 1). On palpation, the nodules were not very hard, and the right testis was a normal size without tenderness. An ultrasonographic examination revealed hypoechoic nodules, without any specific changes in the right testis or epididymis. These examinations indicated that there was no infection in the epididymis, and nodules were only located in the scrotal skin.

We performed resection of these nodules without orchiectomy. In specimens of resected nodules, staining for acid-fast bacilli (Ziehl-Neelsen) was negative; however, *Mycobacterium* species were cultured, and a polymerase chain reaction detected *Mycobacterium bovis*. A histopathological examination showed epithelioid granuloma with necrosis (Fig. 2), and we diagnosed a tuberculous infection in the scrotal skin.

\* Corresponding author. Fax: +81 55 273 9659.

E-mail address: [tmitsui@yamanashi.ac.jp](mailto:tmitsui@yamanashi.ac.jp) (T. Mitsui).

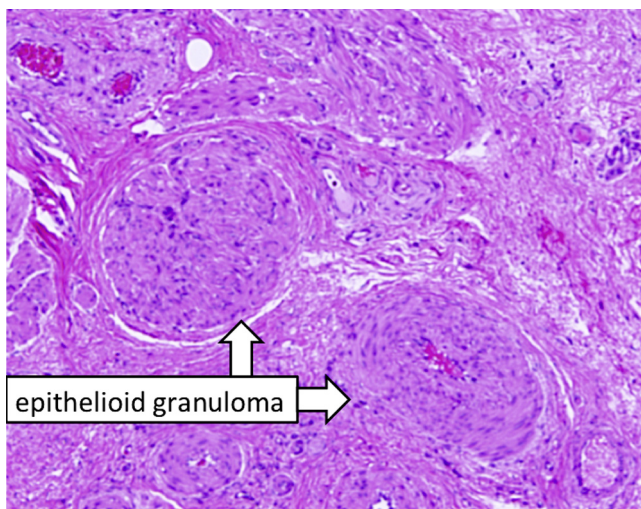


**Figure 1.** Photograph of right scrotal nodules. After intravesical BCG therapy, two cutaneous nodules occurred on the right scrotum with rubor.

We initiated anti-tuberculosis chemotherapy with rifampicin and isoniazid for three months. During this treatment, the scrotal skin became clear, and there were no significant adverse effects. He has received anti-tuberculosis chemotherapy for three months, and there is currently no recurrence of tuberculous granuloma in the scrotal skin.

## Discussion

Urogenital tuberculosis is a relatively rare complication in intravesical BCG therapy. Granulomatous prostatitis has been reported to occur in at least 41% of patients after this therapy; however, it is typically asymptomatic and does not require antibiotic therapy.<sup>1</sup> In some cases, latent granulomatous prostatitis has



**Figure 2.** Hematoxylin and eosin stain ( $\times 400$ ). A histopathological examination showed epithelioid granuloma with necrosis.

led to tuberculous epididymitis caused by benign prostatic hyperrophy with a voiding dysfunction. Lamn et al reported that tuberculous epididymitis occurred with a probability of 0.4%,<sup>2</sup> and orchiectomy was the only effective therapy for tuberculous epididymitis. On the other hand, cases of granulomatous balanoposthitis are more rarely reported, in only approximately 10 cases.<sup>3</sup> This study identified traumatic catheterization and concurrent cystitis as risk factors for BCG infection.

Based on the route of infection, tuberculous infection is generally considered to only occur in the urinary tract and genitals, while tuberculous granuloma in the scrotal skin is attributed to tuberculous epididymitis. In our case, there was no evidence of tuberculous epididymitis, and tuberculous infection in the scrotal skin fully resolved without orchiectomy.

Only two studies have suggested other routes of tuberculous infection. Ng et al present a case of cutaneous tuberculous infection after intravesical BCG therapy.<sup>4</sup> In this case, skin eruption occurred on the patient's left hand during the second course of intravesical BCG therapy. A histological specimen from skin biopsy showed granuloma, and the skin lesion resolved with anti-tuberculous therapy. The author proposed two routes of tuberculous spread to the hand: hematogenous spread and direct inoculation. The hypothesis of hematogenous spread was not likely because there was no evidence of any other site of tuberculous infection. The direct inoculation theory was more likely because the patient previously received an insect bite with a wound on the left hand, which enabled the infestation of the tuberculosis bacterium. Another case of cutaneous tuberculous infection was caused by a needle-stick injury.<sup>5</sup>

In our case, we speculated that tuberculous infection in the scrotal skin was caused by direct inoculation. Since the patient had a voiding dysfunction and phimosis, the dribbling of urine may be a factor for direct BCG inoculation. The results of ultrasonography, surgery for nodules, and the course of the treatment did not support the hypothesis of spread from epididymitis to the skin. However, as a limitation of our case, computed tomography, blood cultures, and orchiectomy were not performed. These examinations may have excluded the possibility of tuberculous epididymitis and hematogenous spread.

## Conclusion

We encountered a case of tuberculous granuloma in the scrotal skin after intravesical BCG therapy for bladder cancer. In our case, direct BCG inoculation into the skin may have been the route of infection, because lower urinary tract symptoms (LUTS) such as the terminal dribbling of urine may support the theory of direct BCG inoculation.

LUTS and skin wounds may be risk factors for this infection. It is important to establish the existence of LUTS before initiating intravesical BCG therapy, and prevent not only urinary tract infection, but also tuberculous granuloma in the scrotal skin.

## Conflict of interest

All authors declare that there are no competing financial interests in relation to this work.

## Acknowledgment

No funding sources.

## References

- Oates RD, Stilmant MM, Freedlund MC, Siroky MB. Granulomatous prostatitis following bacillus Calmette-Guerin immunotherapy of bladder cancer. *J Urol.* 1988;140:751–754.

2. Lamm DL. Efficacy and safety of bacille Calmette-Guerin immunotherapy in superficial bladder cancer. *Clin Infect Dis*. 2000;31 Suppl 3:S86–S90.
3. Yusuke H, Yoshinori H, Kenichi M, Akio H. Granulomatous balanoposthitis after intravesical Bacillus-Calmette-Guerin instillation therapy. *Int J Urol*. 2006;13:1361–1363.
4. Ng YH, Bramwell SP, Palmer TJ, Woo WK. Cutaneous mycobacterial infection post intravesical BCG installation. *The Surgeon*. 2006;4:57–58.
5. Atiyeh BS, Wazzan WC, Kaddoura IL, et al. Bacille Calmette-Guerin (BCG)-itis of the hand: A potential hazard for health workers. *Ann Plast Surg*. 1996;36:325–329.