



Contents lists available at ScienceDirect

## International Journal of Surgery Case Reports

journal homepage: [www.casereports.com](http://www.casereports.com)

## Gallbladder cancer of two histological origins: A case report and review of literature

Aqdas A. Al Omran<sup>b</sup>, Abdullah M. Alkhalifa<sup>c</sup>, Abdullah Saleh Alqattan<sup>a</sup>, Abdulwahab A. Alshahrani<sup>a,b,\*</sup><sup>a</sup> Department of General Surgery, Hepatobiliary Surgery Section, King Fahad Specialist Hospital, Dammam, Saudi Arabia<sup>b</sup> College of Medicine, Imam Abdulrahman Bin Faisal University, Dammam, Saudi Arabia<sup>c</sup> Department of General Surgery, King Fahad Hospital of the University, Khobar, Saudi Arabia

## ARTICLE INFO

## Article history:

Received 25 January 2021

Received in revised form 23 February 2021

Accepted 23 February 2021

Available online 4 March 2021

## Keywords:

Adenocarcinoma

BILCAP

Cancer

Carcinosarcoma

Gallbladder

GBCS

Sarcomatoid

Case report

## ABSTRACT

**INTRODUCTION AND IMPORTANCE:** Carcinosarcoma is an extremely rare subtype of gallbladder cancer with a worldwide prevalence of less than 1%. Carcinosarcomas are composed of a mixture of epithelial and mesenchymal components. Preoperative diagnosis of carcinosarcoma is challenging considering the non-specific clinical presentation and radiological findings.

**CASE PRESENTATION:** A 63 years old female presented with right hypochondrium abdominal pain for 6 months. CA 19.9 level was high. Computed tomography of abdomen showed gallstones with enhancing wall thickening, along with enlarged portacaval lymph node. Endoscopic ultrasound-guided biopsy of porta hepatis lymph node was done which showed moderately differentiated adenocarcinoma. Hence, she underwent extended cholecystectomy with extended porta hepatis lymph node dissection. Final histopathological result showed carcinosarcoma (pT2a, pN1 M0). Unfortunately, she passed away 7 months post-operatively.

**CLINICAL DISCUSSION:** The majority of patients with carcinosarcomas are asymptomatic but can develop unspecific symptoms in advanced stages. The diagnosis is usually made incidentally on histopathological examination. Surgical resection is the mainstay treatment and longer survival can be achieved if combined with chemotherapy and radiation therapy. BILCAP trial suggested that capecitabine can improve survival in patients with gallbladder cancer. Unfortunately, even with these treatment modalities prognosis remains poor with a survival rate ranging from 2.9 to 6 months.

**CONCLUSION:** Gallbladder carcinosarcoma is a rare tumor with a poor prognosis. However, some cases reported a good survival rate after surgery. Further research is needed to understand the behavior of these tumors well and identify the role of chemotherapy and radiotherapy and which patients would benefit the most from surgery.

© 2021 The Author(s). Published by Elsevier Ltd on behalf of IJS Publishing Group Ltd. This is an open access article under the CC BY-NC-ND license (<http://creativecommons.org/licenses/by-nc-nd/4.0/>).

## 1. Introduction

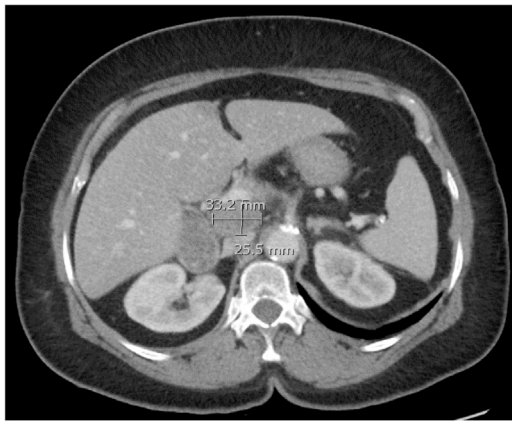
Carcinosarcoma is an extremely rare type of gallbladder cancer that has both epithelial and mesenchymal component. The worldwide prevalence is less than 1% [1]. The total reported cases of carcinosarcoma in the literature were 108 in 2018 [2]. It has a female predominance with a mean age of presentation of 68 years. The preoperative diagnosis of carcinosarcoma is challenging considering the non-specific clinical presentation and radiological findings [2]. We report a case of a 63 years old female with gallbladder carcinosarcoma which was managed with an extended cholecystectomy with porta hepatis lymph node dissection fol-

lowed by adjuvant chemotherapy in a referral tertiary hospital with a review of the English literature of carcinosarcoma of gallbladder. This case report has been reported in line with the SCARE Criteria [3].

## 2. Case presentation

We report a case of a 63 years old female who presented with a right hypochondrium abdominal pain of 6 months duration, radiating to the back associated with nausea and vomiting, aggravated by fatty food, there was no history of gall stones or any previous surgeries. She is non-smoker, her past medical, psychosocial, drug and family history were unremarkable. On physical examination, she was vitally stable; her abdomen was soft and lax with no tenderness. All her laboratory work-up were unremarkable except for CA 19.9 was 39.96 U/ml.

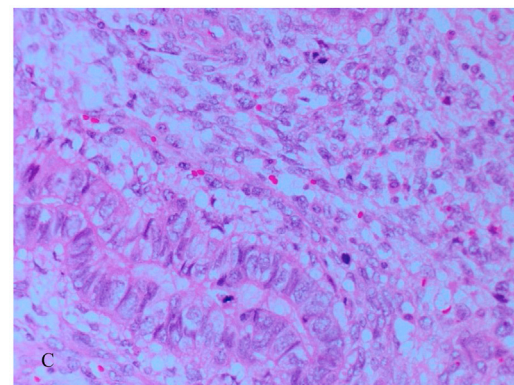
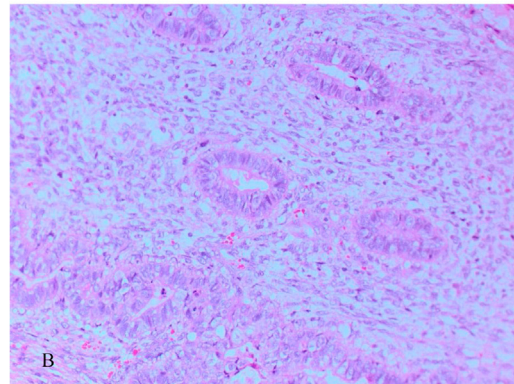
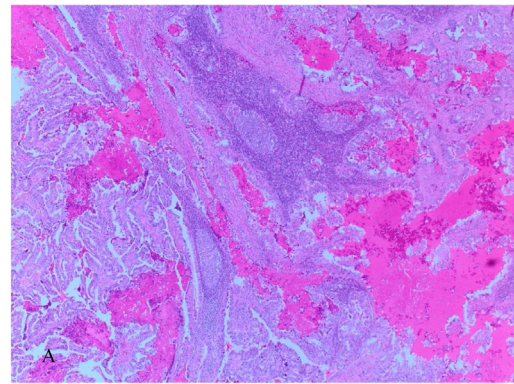
\* Corresponding author at: Department of General Surgery, Hepatobiliary Surgery Section, King Fahad Specialist Hospital, Dammam, 31146, Saudi Arabia.  
E-mail address: [dr.wahab1@hotmail.com](mailto:dr.wahab1@hotmail.com) (A.A. Alshahrani).



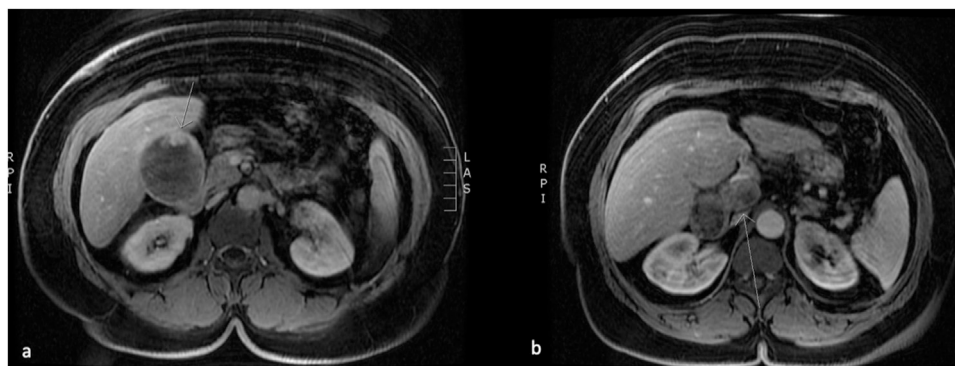
**Fig. 1.** CT Abdomen on axial view showing distended gallbladder with gallstones and asymmetric wall thickness with fat stranding, portacaval lymph node close to the pancreatic head.

Abdominal ultrasound showed: cholelithiasis with wall thickening (0.6 cm), intrahepatic biliary sludges and anechoic mass in the porta hepatis. Computed Tomography of chest, abdomen, and pelvis showed: distended gallbladder with gallstones and sludge, associated with an enhancing asymmetric wall thickening, surrounding fat stranding highly suspicious for malignancy and an enlarged portacaval lymph node (Fig. 1). MRI of the abdomen showed: a distended gallbladder with heterogeneous intraluminal signal intensity as well as an enhancing component, multiple gallbladder stones with enlarged portocaval lymph node (Fig. 2).

Endoscopic ultrasound-guided biopsy of the porta hepatis lymph node demonstrated moderately differentiated adenocarcinoma. Subsequently, the patient underwent extended cholecystectomy with complete porta hepatis lymph node dissection by hepatobiliary surgeon. Microscopically, the tumor was invading the peri-muscular connective tissue on the peritoneal side without serosal involvement. Both the cystic duct and the gallbladder fossa margin were negative for malignancy. Immunohistochemistry staining showed some areas positive for vimentin, caldesmon, and SMA consistent with sarcomatous appearance and areas positive for cytokeratin and CA19.9 consistent with carcinomatous appearance, two lymph nodes were positive for metastatic carcinoma (Fig. 3A–C). The final histopathological diagnosis was gallbladder carcinosarcoma (pT2a, pN1 Mx). The patient had uneventful recovery with no complications and was discharged home in a good condition and referred to medical oncology where she received adjuvant Xeloda. Patient experienced improvement in her symptoms, quality of life and the capability of coping with daily demands.



**Fig. 3.** Microscopic examination of the gallbladder using H & E staining demonstrating; (A) both epithelial component as well as the sarcomatous component of carcinosarcoma of the resected gallbladder at a low power field X10. (B) at power field of X20 (C) at power field of X40; nests of malignant epithelial cells surrounded by malignant mesenchymal cells.



**Fig. 2.** MRI abdomen on axial view showing distended gallbladder with heterogeneous intraluminal signal intensity as well as enhancement component and multiple gallbladder stones. (a). Enlarged lymph node noted at the portocaval lesion (b).

**Table 1**  
Thirteen reported cases regarding carcinosarcoma of gallbladder since 2019.

Author	Year	Age/ Gender	Size	Stage / TNM	Procedure	Chemotherapy	Recurrence	Survival
Present case	2021	63 Y F	18 × 7 × 4.5 cm	pT2a, pN 1 Mx.	Extended cholecystectomy with complete porta hepatis lymph node dissection	adjuvant Xeloda.	No evidence of recurrence	Died; 7 months post-operatively
Khurram et al. [20]	2021	64 Y F	21 × 14 × 13 cm	N/R	Cholecystectomy, central hepatic lobectomy	N/R	No evidence of recurrence	N/R
Ayoub et al. [17]	2020	66 Y M	15 × 8 × 6 cm	IVA (pT4.0NO,M0)	Extended gallbladder cholecystectomy	N/R	No evidence of recurrence	N/R
Kaneko et al. [18]	2020	70s Y F	11 × 7 × 3 cm	N/R	Cholecystectomy	Gemcitabine	No evidence of recurrence	Alive; 44 months since visit
Shi et al. [16]	2020	60 Y F	N/R	N/R	Radical cholecystectomy, intestinal adhesiolysis omental excision After recurrence; right hemicolectomy, special hepatectomy, juejenal fistula, adhesiolysis	Gemcitabine, oxaliplatin, tiggio, anlotinib	Hepatic recurrence 5 months after surgery	Died; 5 months after stopping anlotinib
Tiabi et al. [19]	2020	66 Y M	15 × 6 cm	N/R	Cholecystectomy and hepatic bisegmentectomy	N/R	No evidence of recurrence	N/R
Siddiqui et al. [2]	2020	56 Y M	6.2 cm	Stage IV TNM: N/R	Not a surgical candidate.	PC: with doxorubicin (adriamycin), ifosfamide and mesna (AIM regimen). 2 cycles of AC. (Chemotherapy regimen: N/R.)	No evidence of recurrence	Died; 2ry to sepsis
Aldossary et al. [1]	2019	42 Y M	11.5 × 9.2 × 5 cm	IVB (pT3, pNO, M1)	Radical cholecystectomy + extended right hemicolectomy, + resection of segment V	Patient refused AC.	Hepatic recurrence; 3 months after surgery	Died; 3 months after recurrence
		52 Y F	13.6 × 12 × 9.5 cm	IVB (pT4, pN2, M1)	Radical cholecystectomy, transverse colectomy, and distal gastrectomy with Roux-en-Y gastrojejunostomy, limited lymphadenectomy		Hepatic recurrence; 2 months after surgery	Died; 1 Month after recurrence
		62 Y F	2 × 2 cm	Stage II (pT2, pNO, Mx)	completion radical cholecystectomy, lymphadenectomy, segment IV and V resection, and port site excision.		port-site metastasis; 2 years after surgery	Alive; 86 months postoperatively
Mochizuki et al. [4]	2019	88 Y F	6 × 2.5 cm	N/R	Cholecystectomy + choledocholithotomy	N/R	No evidence of recurrence	Alive; 10 months postoperatively
Matsubayashi, et al. [11]	2019	72 Y F	8.4 × 7.2 cm	Stage IIIA (pHInfb by Japanese classification) TNM: N/R	Extended cholecystectomy	N/R	No evidence of recurrence	Alive; 73 months post operatively
Alratroot et al. [15]	2019	52 F	8 × 6 cm	Stage III (pT4 pN2pMx)	Radical cholecystectomy, transverse colectomy, distal gastrectomy, omentectomy.	6 cycles of AC (Gemcitabine + Cisplatin)	N/R	N/R

GB: Gallbladder. F: Female. M: Male. N/R: Not reported. AC: Adjuvant chemotherapy. PC: Palliative chemotherapy.



### 3. Discussion

The First reported case of gallbladder carcinosarcoma (GBCS) was published by Landsteiner k et al. back in 1907 [19]. Carcinosarcoma known as Sarcomatoid carcinoma, spindle cell carcinoma, and pseudosarcoma can be seen in different organs e.g; uterus, kidneys, pancreas, and esophagus [1]. Carcinosarcomas are composed of epithelial and mesenchymal components, most commonly adenocarcinoma and spindle cells, respectively [1,3]. Squamous cell carcinoma could also be present as the epithelial component, while the mesenchymal component can also be chondrosarcoma, osteosarcoma, and other mesenchymal tissues [3]. Interestingly, Mochizuki et al. reported a case of carcinosarcoma consisting of variable components of adenocarcinoma, neuroendocrine carcinoma, undifferentiated carcinoma, and chondrosarcoma of the gallbladder [4].

Carcinosarcoma has an incidence of approximately 1.2 per 100,000 per year [1]. It has a higher prevalence in South America and South-East Asia. [6]. It is usually an aggressive tumor with poor prognosis, with the best reported median survival of 5.5 months [2]. Zhang L et al. conducted a meta-analysis on the published cases of Gallbladder carcinosarcoma and reported that the female to male ratio was 3.25: 1 with a median age of diagnosis was 68 and 69, respectively. The median tumor size is 5 cm, and the mean survival was 17.5 months [3]. The total number of gallbladder carcinosarcomas that have been reported in the literature is 108 cases till 2018. From 2019 to 2020 there have been 13 newly reported cases [2]. The characteristics of which are highlighted in the table (Table 1).

The pathogenesis of these tumors is not yet fully understood, mostly due to the low incidence of these tumors [1]. However, five theories have been proposed, two of them are quite conflicting theories; The multiclonal theory or so-called convergence, collision, true sarcoma hypothesis; which consider carcinosarcoma to be a buildup from two or more stem cells of separate epithelial and mesenchymal origin. On the other hand, the monoclonal theory or so-called divergent, metaplastic hypothesis; regards that the two components of carcinosarcoma are derived from a single pluripotential stem cell that subsequently develops atypical differentiation [14,20].

Most patients are diagnosed after histopathological examination of gallbladder while only 30% are suspected pre-operatively [7]. However, patients become symptomatic eventually with the growth and invasion of the tumor into the adjacent organs [8]. Furthermore, most of the patients with gallbladder carcinosarcoma have associated gallstones [2]. Therefore, a high index of suspicion is necessary in order not to overlook the presence of malignancy. There are few reported case of GBCS with a unique and unusual presentation in the literature such as; Tonouchi et al. reported a case of GBCS associated with choleystocolic fistula and liver abscess ruptured at the gallbladder-bed, Varshney et al. reported a case of GBCS with Mirizzi syndrome and Sadamori et al. reported a case of GBCS which presented as cholangitis due to haemobilia [8–10].

Laboratory investigations and Imaging studies are helpful but unfortunately the findings are not specific for carcinosarcoma [4]. Therefore, the definitive diagnosis of carcinosarcoma is based on histopathological examination showing a tumor composing of both malignant epithelial and mesenchymal components [2]. Immunohistochemistry can show positive staining of cytokeratin for the epithelial component and vimentin for the mesenchymal component [11].

Surgery is the mainstay of treatment in resectable cases and a longer survival can be achieved whenever it's combined with radiotherapy and chemotherapy [1]. Recently, a randomized, controlled, multicentric clinical trial the BILCAP trial published their results, they assessed the overall survival in patients with biliary tract cancer resected with curative intent and receiving oral Capecitabine,

although the analysis didn't show a statistical significant result regarding the overall survival endpoint in the intention-to-treat population, the sensitivity and secondary analysis suggest that capecitabine can improve overall survival in resected biliary tract cancer when used as adjuvant chemotherapy [12].

Commonly at presentation, there would be an infiltration to the gallbladder wall and the adjacent structures [8]. There are multiple surgical options to achieve a complete oncological resection including radical cholecystectomy with or without common bile duct resection, partial resection of the small intestine and/or colon, and pancreaticoduodenectomy [14]. It appears that the gallbladder carcinosarcoma behave more aggressively than gallbladder carcinoma with median time to recurrence of less than 1 year. Usually, the recurrence occurs in the liver, lymph nodes, and peritoneal cavity. [5,14]. The median time of tumor recurrence after surgery is 50 days [1].

The prognosis of these tumors is poor even after complete resection with a survival rate range from 2.9 to 6 months [1]. Okabayashi et al. found in their review that the 5-year overall survival of carcinosarcoma patients who underwent surgical resection was 31% [13]. This poor prognosis could be attributed to the fact that most of these patients present in an advanced stage. However, Aldosary et al. reported patients with Gallbladder Carcinosarcoma that survived 86 months after curative resection [1]. Also, Wada et al. reported a case of carcinosarcoma with a survival of more than 60 months that could be attributed to the induction of adjuvant chemotherapy with gemcitabine chloride [14].

In cases of carcinosarcoma with invasion limited to muscularis propria who underwent resection with intent curative their 5-year survival rate increased to 88.9%. [11]. Some suggested good prognostic factors are tumor size less than 5, early-stage disease at the time of diagnosis, Japanese race, and complete oncological resection [1,3]. It is important to think of sarcomatoid cancers as a distinct category to allow more focused therapies targeting their altered pathway because it is believed that they are the ultimate of "epithelial-mesenchymal transition" and stem cell regression [5].

### 4. Conclusion

Carcinosarcoma of the gallbladder is a rare, aggressive tumor with poor prognosis even after complete oncological resection. The etiology of these tumors is poorly understood, due to the small number of published cases. Further research is needed to understand the behavior of this entity and identify the role of chemotherapy and radiotherapy and which patients would benefit the most from surgery.

### Declaration of Competing Interest

The authors report no declarations of interest.

### Funding

This study did not receive any funding.

### Ethical approval

IRB approval are not needed for Case reports in our center.

### Consent

Written informed consent was obtained from all of the patients for publication of this case report and accompanying images. A copy of the written consent is available for review by the Editor-in-Chief of this journal on request.

### Author contribution

**Aqdas A. Al Omran:** study concept or design, data collection, data interpretation, literature review, drafting of the paper, final review of the manuscript.

**Abdullah M. Alkhalifa:** study concept or design, data collection, data interpretation, literature review, drafting of the paper, final review of the manuscript.

**Abdullah S. AlQattan:** study concept or design, literature review, drafting of the paper, final review of the manuscript.

**Abdulwahab AlShahrani:** Study concept or design, literature review, drafting of the paper, final review of the manuscript.

### Registration of research studies

Not applicable.

### Guarantor

Dr. Abdulwahab Alshahrani.

### Provenance and peer review

Not commissioned, externally peer-review.

### Acknowledgement

Not available.

### References

- [1] M.Y. Aldossary, A.S. AlQattan, Y.M. Alghamdi, A.A. Alayed, F. Alquraish, O.A. AlAnzi, N. Alabdulrahim, A. Alateeq, M.S. Alqahtani, Surgical outcomes of primary carcinosarcoma of the gallbladder after curative resection: a rare case series, *Int. J. Surg. Case Rep.* 65 (2019) 32–39.
- [2] M. Siddiqui, S. Hegde, T. Nguyen, S. DePaul, Sarcomatoid carcinoma of the gallbladder: a rare form of gallbladder cancer, *SAGE Open Med. Case Rep.* 8 (2020), 2050313X20906739.
- [3] L. Zhang, Z. Chen, M. Fukuma, L.Y. Lee, M. Wu, Prognostic significance of race and tumor size in carcinosarcoma of gallbladder: a meta-analysis of 68 cases, *Int. J. Clin. Exp. Pathol.* 1 (1) (2008) 75.
- [4] K. Mochizuki, H. Hata, K. Naitou, U. Motosugi, T. Kondo, Carcinosarcoma (adenocarcinoma, neuroendocrine carcinoma, undifferentiated carcinoma and chondrosarcoma) of the gallbladder, *Clin. J. Gastroenterol.* (2019) 1–6.
- [5] O.C. Taskin, G. Akkas, B. Memis, I.E. Seven, O. Basturk, K.T. Jang, J.C. Roa, J.C. Araya, E. Bellolio, H. Losada, J. Sarmiento, Sarcomatoid carcinomas of the gallbladder: clinicopathologic characteristics, *Virchows Arch.* 475 (1) (2019) 59–66.
- [6] M.Y. Aldossary, A.A. Alayed, S.S. Amr, S. Alqahtani, M. Alnahawi, M.S. Alqahtani, Gallbladder cancer in Eastern Province of Saudi Arabia: a retrospective cohort study, *Ann. Med. Surg.* 35 (2018) 117–123.
- [7] A. Cavallaro, G. Piccolo, M. Di Vita, A. Zanghi, F. Cardì, P. Di Mattia, G. Barbera, L. Borzi, V. Panebianco, I. Di Carlo, M. Cavallaro, A. Cappellani, Managing the incidentally detected gallbladder cancer: algorithms and controversies, *Int. J. Surg.* 12 (2014) S108–S119.
- [8] H. Sadamori, H. Fujiwara, T. Tanaka, H. Yanai, D. Satoh, T. Yagi, T. Fujiwara, Carcinosarcoma of the gallbladder manifesting as cholangitis due to hemobilia, *J. Gastrointest. Surg.* 16 (6) (2012) 1278–1281.
- [9] A. Tonouchi, N. Yokoyama, H. Hashidate, N. Matsuzawa, N. Katayanagi, T. Otani, Education and Imaging. Gastroenterology: carcinosarcoma of the gallbladder presenting as a cholecysto-colic fistula, *J. Gastroenterol. Hepatol.* 30 (7) (2015) 1112.
- [10] V.K. Varshney, J.N. Bharti, B. Sureka, S.C. Soni, Gallbladder carcinosarcoma with mirizzi syndrome: a rare presentation, *J. Gastrointest. Cancer* 50 (4) (2019) 997–1000.
- [11] H. Matsubayashi, T. Matsui, T. Sugiura, R. Makuuchi, J. Kaneko, J. Satoh, T. Satoh, S. Fujie, H. Ishiwatari, K. Sasaki, H. Ono, A large carcinosarcoma of the gallbladder accompanied by pancreaticobiliary maljunction-A case with a six-year survival, *Intern. Med.* (2019), 2783–2719.
- [12] J.N. Primrose, R.P. Fox, D.H. Palmer, H.Z. Malik, R. Prasad, D. Mirza, A. Anthony, P. Corrie, S. Falk, M. Finch-Jones, H. Wasan, Capecitabine compared with observation in resected biliary tract cancer (BILCAP): a randomised, controlled, multicentre, phase 3 study, *Lancet Oncol.* 20 (5) (2019) 663–673.
- [13] T. Okabayashi, Z.L. Sun, R.A. Montgomey, et al., Surgical outcome of carcinosarcoma of the gall bladder: a review, *World J. Gastro-enterol.* 15 (2009) 4877–4882.
- [14] Y. Wada, Y. Takami, M. Tateishi, T. Ryu, K. Mikagi, S. Momosaki, H. Saitsu, Carcinosarcoma of the gallbladder: report of a case, *Clin. J. Gastroenterol.* 7 (5) (2014) 455–459.
- [15] J. Alratroot, A. Joudeh, S. Amr, Carcinosarcoma of the gallbladder with chondrosarcomatous differentiation and intracytoplasmic eosinophilic hyaline globules (Thanatosomes): a report of a case and review of the literature, *Case Rep. Pathol.* 2019 (2019) 1–11.
- [16] Y. Shi, J. Chen, H. Chen, Sarcomatoid Carcinoma of the Gallbladder: A Case Report, 2020.
- [17] M. Ayoub, R. Jabi, M. Achraf, A. Benani, E. Arabi, K. Imani, et al., CASE REPORT – OPEN ACCESS International Journal of Surgery Case Reports Surgical management of gallbladder carcinosarcoma: a case report and review of the literature, *Int. J. Surg. Case Rep.* 75 (2020) 460–463, <http://dx.doi.org/10.1016/j.ijscr.2020.09.114> [Internet].
- [18] R. Kaneko, Y. Kimura, H. Sakata, T. Ikehara, H. Mitomi, T. Uekusa, CASE REPORT A case of primary hepatic mixed neuroendocrine non neuroendocrine tumor (MiNEN) associated with gallbladder carcinosarcoma, *Clin. J. Gastroenterol.* (2020), <http://dx.doi.org/10.1007/s12328-020-01202-8> [Internet].
- [19] E.L.M. Tiabi, Carcinosarcoma of the Gallbladder with Two Heterologous Components: A Case Report and Review of the Literature. 1–9.
- [20] R. Khurram, R. Khamar, R. Lunat, D. Novelli, R.F. Hospital, R. Free, et al., Gallbladder carcinosarcoma masquerading as a hepatic abscess, *Radiol. Case Rep.* 16 (2021) 152–156.

### Open Access

This article is published Open Access at [sciencedirect.com](https://www.sciencedirect.com). It is distributed under the [IJSCR Supplemental terms and conditions](#), which permits unrestricted non commercial use, distribution, and reproduction in any medium, provided the original authors and source are credited.