



Case report

Pulmonary venous thrombosis secondary to radiofrequency ablation of the pulmonary veins

Raquel López-Reyes^a, Alberto García-Ortega^{a,*}, Ana Torrents^a, Laura Feded^a, Pilar Calvillo^b, Eugenia Alejandra Libreros-Niño^c, Juan Escrivá-Peiró^c, Dolores Nauffal^a

^a Department of Pulmonology, University and Polytechnic LA FE Hospital, Valencia, Spain

^b Department of Radiology, University and Polytechnic LA FE Hospital, Valencia, Spain

^c Department of Thoracic Surgery, University and Polytechnic LA FE Hospital, Valencia, Spain

ARTICLE INFO

Keywords:

Venous thrombosis
Atrial fibrillation
Radiofrequency ablation
Hemoptysis
Lung consolidation
Lung infarction
Lung resection surgery

ABSTRACT

Background: Pulmonary Vein Thrombosis (PVT) is a rare and underdiagnosed entity produced by local mechanical nature mechanisms, vascular torsion or direct injury to the vein. PVT has been described in clinical cases or small multicenter series mainly in relation to pulmonary vein stenosis, metastatic carcinoma, fibrosing mediastinitis, as an early surgical complication of lung transplantation lobectomy and radiofrequency ablation performed in patients with atrial fibrillation, although in some cases the cause is not known.

Case: We report the case of a 57 years old male with history of atrial fibrillation treated by radiofrequency ablation who was admitted in our center because of a two-week history of consistent pleuritic pain in the left hemithorax and low-grade hemoptysis and a lung consolidation treated as a pneumonia with antibiotic but not responding to medical therapy. In view of the poor evolution of the patient, computed tomography angiography was performed with findings of PVT and secondary venous infarction and anticoagulation therapy was optimized. At the end, pulmonary resection was performed due to hemorrhagic recurrence.

Conclusion: PVT remains a rare complication of radiofrequency ablation and other procedures involving pulmonary veins. Clinical suspicion and early diagnosis is crucial because is a potentially life-threatening entity.

1. Introduction

Pulmonary Vein Thrombosis (PVT) is a rare and underdiagnosed entity [1,2], whose actual incidence is unknown. The potential mechanisms that produce it are of local mechanical nature, vascular torsion, or direct injury to the vein [3].

PVT has been described in clinical cases or small multicenter series mainly in relation to pulmonary vein stenosis, metastatic carcinoma, fibrosing mediastinitis, as an early surgical complication of lung transplantation lobectomy and radiofrequency ablation performed in patients with chronic atrial fibrillation, although in some cases the cause is not known [4–9].

Among the most common complications are pulmonary infarction, interstitial edema, right ventricular dysfunction, or graft failure in cases secondary to lung transplantation [1,6,10,11]. The diagnosis is difficult if there is not a high level of suspicion because it presents with symptoms common to other respiratory diseases such as dyspnea, cough or hemoptysis [12].

The present case report describes a patient who experienced left

superior lobar pulmonary vein thrombosis and secondary infarction after radiofrequency ablation.

2. Case presentation

We report a 57-year-old man, never smoker, that suffers sleep apnea-hypopnea syndrome on continuous positive air-pressure (CPAP) treatment and permanent atrial fibrillation treated by radiofrequency ablation 6 months before the admission that led to this case report, and treated with acenocoumarol and amiodarone.

The patient was admitted in the hospital in February 2017 presenting a two week history of consistent severe left pleuritic chest pain and low-grade hemoptysis without fever and other accompanying cardiorespiratory symptoms. The analysis was anodyne: normal hemogram, hemostasis in a therapeutic range, no elevation of acute phase reactants and preserved renal function. On the chest radiograph (CXR) of admission, an image of alveolar consolidation was found in the left upper lobe (LUL) [Fig. 1a]. An antibiotic cycle was followed and the anticoagulation remained unchanged.

* Corresponding author.

E-mail address: albortgva@gmail.com (A. García-Ortega).

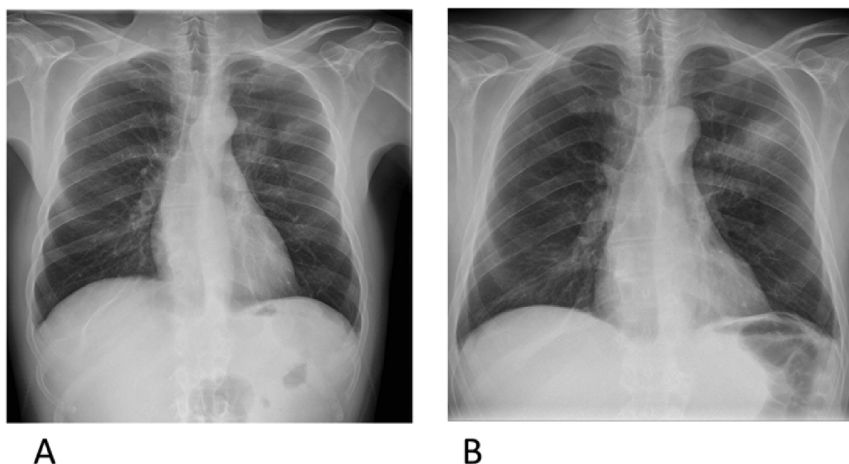


Fig. 1. Comparison between chest radiograph images at the time of first admission (A) and at the time of the second admission after completion of the antibiotic cycle (B).

At the end of the antibiotic regimen, the patient consulted again in the emergency room for recurrence of chest pain with pleuritic characteristics and hemoptysis.

Physical examination indicated the following: Blood pressure 133/78 mmHg; heart rate 84 beats/min, oxygen saturations 98% on air; temperature 36 °C; eupneic at rest and good tolerance to decubitus; good peripheral perfusion and no cyanosis; pulmonary auscultation with preserved vesicular murmur in both hemithorax and arrhythmic heart auscultation without blows.

Complementary tests performed on emergency room showed: Laboratory test proved normal white blood cell count ($9.51 \times 10^9/l$), normal platelet count ($242 \times 10^9/l$) normal value of hemoglobin (15.9 g/dl), not elevated C reactive protein, 4.8 mg/dl (0.0–5.0 mg/dl), haemostasis with INR in rank and negative autoimmunity; electrocardiogram evidenced atrial fibrillation with ventricular response at 80 bpm without alterations of repolarization; CXR showed increased size of the LUL consolidation, with no associated pleural effusion, and no alterations in the mediastinum and pulmonary hilia [Fig. 1b]. The result of sputum culture for bacteria and mycobacteria was negative. The patient underwent a bronchoscopy with the only finding of traces of blood at the entrance of the bronchus of the upper left lobe and bronchoalveolar lavage (BAL) and transbronchial biopsy samples were collected during the procedure. Anatomopathological analysis revealed nonspecific interstitial inflammation and the BAL results were negative for microbes. Evaluation was completed with computed tomography angiography (CTA) which showed extensive consolidation in the anterior segment of the LUL, with central hyperdensity and hypodense periphery, and complete thrombosis of the left superior lobar pulmonary vein. There was no evidence of filling defects in the pulmonary arteries. After these findings, a diagnosis of PVT and secondary venous infarction was made [Fig. 2] and we decided to switch anticoagulation with heparin at therapeutic doses.

Initially the patient remained stable throughout the admission with progressive remission of hemoptysis until discharge. However, at 15 days the patient was readmitted in hospital due to hemoptoic recurrence of about 30 ml. Anticoagulation was withdrawn and CTA was repeated, which ruled out progression of thrombosis, but not pulmonary hemorrhage, and surgical treatment was decided by resection of the left culmen. Since surgery, hemoptysis remitted and the patient remains asymptomatic.

3. Discussion

Chronic atrial fibrillation is an increasingly common entity and the radiofrequency ablation has emerged as an efficacious therapeutic alternative for drug-refractory patients but ablation catheter procedures are associated to known complications as pericardial effusion, stroke,

transient ischemic attacks, and pulmonary vein stenosis [12,13].

The PVT is a very rare condition, since the pulmonary circulation has an extensive network of collaterals for pulmonary venous drainage [1], and its diagnosis is difficult.

Symptoms depend by the number and the severity of affected pulmonary veins, the collaterals and the rate of progression [13]. The form of presentation varies widely and may include dyspnea, chest pain, cough or hemoptysis but these nonspecific symptoms are more frequently related to other diseases such as community-acquired pneumonia (CAP), pulmonary arterial infarction or vasculitis [14].

Because of the PVT is a life-threatening entity and the variability in presenting symptoms, clinicians must have heightened sensitivity to the presence of the condition, although the diagnosis is now simpler given the increase in radiological explorations performed in our patients.

CXR finding could be nonspecific such as pulmonary and interstitial opacities and pleural effusion, so the final diagnosis is usually obtained with transesophageal echocardiogram, magnetic resonance imaging, which can distinguish between tumor and thrombus, or CT after injection of intravenous contrast in the late phase to reduce flow artifacts [3].

In the presented clinical case, the appearance of hemoptysis and pleuritic pain in a patient with alveolar condensation and correctly anticoagulated made suspicious the onset of CAP. The clinical and radiological evolution was not as expected for a CAP, and the study was completed by assessing other less frequent diagnostic possibilities: vasculitis was ruled out by negative autoimmunity study, radiological pattern of focal hemorrhagic involvement and histological findings. The final diagnosis of pulmonary venous involvement was obtained by CTA.

The PVT usually presents in relation to a known antecedent that justifies the direct venous pulmonary lesion, reason why we consider crucial to rule out this entity in the patients with presentation symptoms and signs as hemoptysis, pulmonary infiltrate and/or thoracic pain after a potentially damaging procedure for the pulmonary veins such as venous anastomosis in lung transplant patients, lobectomies and lung carcinomas, among others [5,8,9]. Of all these, the most frequent origin are in lung transplantation, where up to 15% of patients have been documented in the most immediate postoperative period [3].

In the present case, the radiofrequency ablation of the pulmonary veins is the more likely etiology of the vascular lesion, as it has been described before; Some series of patients who underwent radiofrequency ablation of the pulmonary veins revealed a prevalence of pulmonary vein stenosis after the procedure from 3 to 42% [13–15], but PVT is a rare complication of radiofrequency ablation, due to the anticoagulant treatment that is introduced immediately after the procedure [15]. In our case, the venous perfusion deficit is explained by a thrombus (Fig. 2) and not by a stricture; Subsequently we can rule out the diagnosis of pulmonary vein atresia, but we cannot rule out a

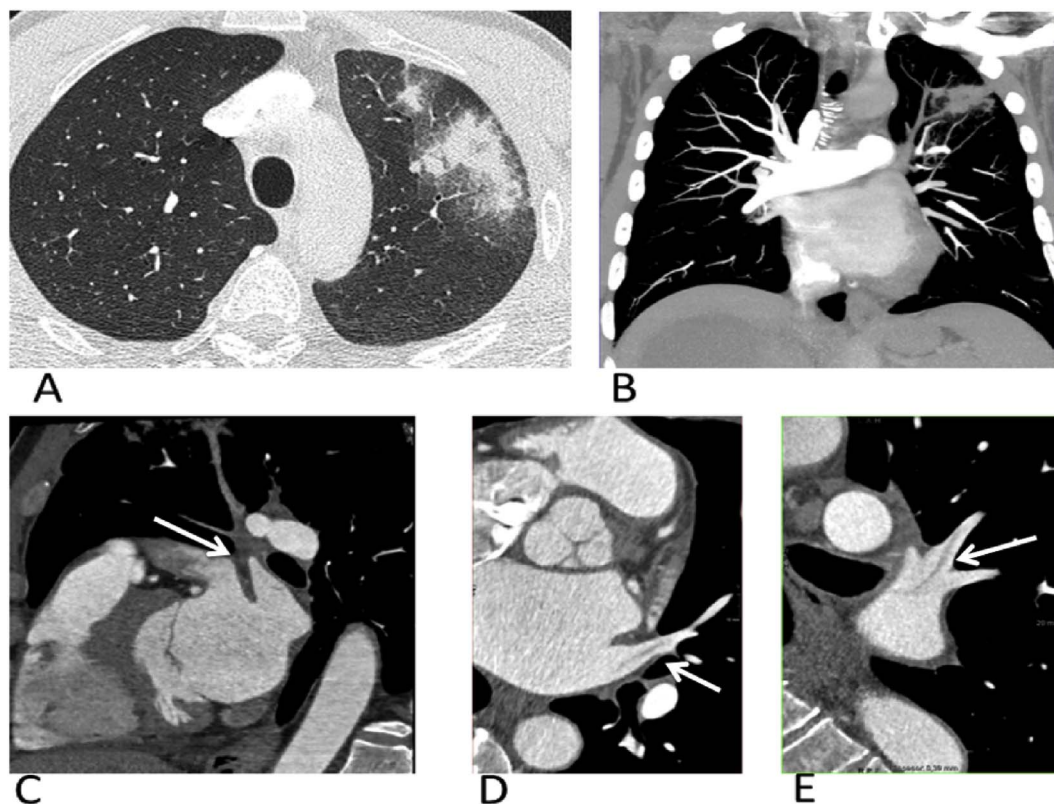


Fig. 2. Thoracic angiography (A and B) showing extensive consolidation in the anterior segment of the LUL with a high-density central component, corresponding to lung infarction, and a low-density periphery due to hemorrhage; Cardiac CT (C, D and E) after injection of intravenous contrast in the late phase with filling defect of the left superior lobar vein (white arrow) and its subsegmental branches.

previous narrowing of the pulmonary vein as has been described in those series.

Therapeutic management should be guided by the severity of DVT, although there are no published guidelines. In milder cases conservative management can be decided with antibiotics and anticoagulation although there is controversy over the protective effect of anticoagulation [1]. In cases where the disease does not improve with conservative management, recurrence or massive hemoptysis or necrosis of lung tissue, thrombectomy and/or resection surgery may be necessary [9].

To conclude, PVT remains a rare complication of radiofrequency ablation and other procedures involving pulmonary veins but clinical suspicion and early diagnosis is crucial for appropriate therapeutic management.

Appendix A. Supplementary data

Supplementary data related to this article can be found at <http://dx.doi.org/10.1016/j.rmcr.2017.11.008>.

References

- [1] G. Chaaya, P. Vishnubhotla, Pulmonary vein thrombosis: a recent systematic review, *Cureus* 9 (1) (2017) e993.
- [2] N.H. Kim, C.A. Roldan, B.K. Shively, Pulmonary vein thrombosis, *Chest* 104 (2) (1993) 624–626.
- [3] D.V. Porres, O.P. Morenza, E. Pallisa, A. Roque, J. Andreu, M. Martinez, Learning from the pulmonary veins, *Radiographics* 33 (4) (2013) 999–1022.
- [4] K. Ohtaka, Y. Hida, K. Kaga, Y. Iimura, N. Shiina, J. Muto, et al., Pulmonary vein thrombosis after video-assisted thoracoscopic left upper lobectomy, *J. Thorac. Cardiovasc. Surg.* 143 (1) (2012) e3–e5.
- [5] K. Ohtaka, Y. Hida, K. Kaga, Y. Takahashi, H. Kawase, S. Hayama, et al., Left upper lobectomy can be a risk factor for thrombosis in the pulmonary vein stump, *J. Cardiothorac. Surg.* 9 (2014) 5.
- [6] J. Saoraya, P.C. Inboriboon, Pulmonary vein thrombosis associated with a large hiatal hernia, *J. Emerg. Med.* 44 (3) (2013) e299–e301.
- [7] N. Mumoli, M. Cei, Idiopathic pulmonary vein thrombosis, *J. Emerg. Med.* 42 (2) (2012) 182–183.
- [8] B. Malm, S. Hull, F. Jadbabaie, Left upper pulmonary vein thrombus in a patient with atrial fibrillation and prior lobectomy, *Am. J. Med.* 127 (11) (2014) e7–e8.
- [9] I. Nagahiro, M. Horton, M. Wilson, J. Bennetts, P. Spratt, A.R. Glanville, Pulmonary vein thrombosis treated successfully by thrombectomy after bilateral sequential lung transplantation: report of a case, *Surg. Today* 33 (4) (2003) 282–284.
- [10] L. Bonnet, N. Raposo, N. Blot-Souletie, M. Faruch Bilfeld, F. Chollet, J. Maziere, et al., Stroke caused by a pulmonary vein thrombosis revealing a metastatic hio-carcinoma, *Circulation* 131 (23) (2015) 2093–2094.
- [11] A.J. Grau, S.O. Schoenberg, C. Lichy, F. Buggle, M. Bock, W. Hacke, Lack of evidence for pulmonary venous thrombosis in cryptogenic stroke: a magnetic resonance angiography study, *Stroke* 33 (5) (2002) 1416–1419.
- [12] R.A. Cavaco, S. Kaul, T. Chapman, R. Casaretti, B. Philips, A. Rhodes, et al., Idiopathic pulmonary fibrosis associated with pulmonary vein thrombosis: a case report, *Cases J* 2 (2009) 9156.
- [13] D.R. Holmes Jr., K.H. Monahan, D. Packer, Pulmonary vein stenosis complicating ablation for atrial fibrillation: clinical spectrum and interventional considerations, *JACC Cardiovasc. Interv.* 2 (4) (2009) 267–276.
- [14] J. Yataco, J.K. Stoller, Pulmonary venous thrombosis and infarction complicating pulmonary venous stenosis following radiofrequency ablation, *Respir. Care* 49 (12) (2004) 1525–1527.
- [15] J.M. Madrid Perez, P.M. García Barquin, A.J. Villanueva Marcos, J.I. García Bolao, G. Bastarrica Alemañ, Complications associated with radiofrequency ablation of pulmonary veins, *Radiologia* 58 (6) (2016) 444–453.