




CASE REPORT

Two cases of parapharyngeal space tumor resected by a double split mandibular osteotomy technique

Shinichiro Kato¹  | Kei Ijichi² | Asako Fukushima³ | Tomohisa Nakamura¹  |
Hiroyuki Takashima¹ | Tsuyoshi Nabeta¹ | Hironori Miyamoto¹ |
Kenichiro Ishibashi¹ | Shuhei Tsuchiya¹ | Sumiyo Hishida¹ | Yasuyuki Shibuya¹ 

¹Department of Oral and Maxillofacial Surgery, Nagoya City University Graduate School of Medical Sciences, Nagoya, Japan

²Akaike ORL-HNS Clinic, Nissin, Japan

³Mizuho Dental Clinic, Fukuoka, Japan

Correspondence

Shinichiro Kato, Department of Oral and Maxillofacial Surgery, Nagoya City University Graduate School of Medical Sciences, Kawasumi, Mizuho-cho, Mizuho-ku, Nagoya 467-8601, Japan.
Email: st205-st183yuhi@pro.odn.ne.jp

Abstract

Parapharyngeal space tumors have poor subjective symptoms and often grow until diagnosed; therefore, mandibular transection may be needed to obtain a wider field of view during surgery. However, if a median lower lip incision is performed for the mandibular transection, esthetic problems occur after surgery. Here, we report two cases of parapharyngeal space tumors that were removed with a mandibular lateral segment-osteotomy technique without median lower lip incision to avoid esthetic problems. Case 1 was a 49-year-old woman. She was aware of a right tonsillar swelling, and an imaging test revealed a tumor lesion 60 mm in size in the right parapharyngeal space. Case 2 was a 40-year-old woman with an abnormal position of the uvula, and an imaging test showed the left parapharyngeal space tumor lesion 45 mm in size. Both cases were diagnosed as a pleomorphic adenoma, and surgery under general anesthesia was performed jointly with otolaryngology and oral surgery. The incision was performed from the lower part of the right auricle to the anterior part of the submandibular area. After the tumor resection, the mandible was repositioned, fixed by plates, and the intermaxillary fixation was performed with a surgical stent. In both cases, slight paralysis of the mandibular branch of the facial nerve and the mental nerve was observed after the operation, but they were improved immediately. One year after the operation, the plates were removed. There have been no recurrences until now.

KEYWORDS

double split osteotomy, mandibular osteotomy, median lower lip incision, parapharyngeal space tumor, pleomorphic adenoma

This is an open access article under the terms of the [Creative Commons Attribution-NonCommercial](https://creativecommons.org/licenses/by-nc/4.0/) License, which permits use, distribution and reproduction in any medium, provided the original work is properly cited and is not used for commercial purposes.

© 2022 The Authors. *Clinical Case Reports* published by John Wiley & Sons Ltd.

1 | INTRODUCTION

The neoplastic lesion in the parapharyngeal space accounts for 0.5% of all head and neck tumors and is a relatively rare disease.¹ Most parapharyngeal space tumors are benign but are difficult to remove because the parapharyngeal space has a complex structure including anatomically important blood vessels and nerves.² In addition, the tumor often grows at the time of detection, and in many cases, the mandibular bone needs to be transected to secure a wide surgical field and perform a safe surgical procedure.³ Especially, if a top of tumor be located around the surface of external cranial base, it is difficult to tumor resection with bright field observation. There is one technique of a mandibular swing approach, in which a midline incision is made in the lower lip and the mandible is cut midline. However, this technique has a cosmetic disadvantage in that a postoperative scar is left on the face and may not be the first choice in consideration of the patient's age, gender, and living background. On the contrary, there is another technique without a lower lip incision but with the double split of the mandibular body to avoid esthetic problems.

Here, we report two cases of parapharyngeal space tumor resected by the double mandibular split osteotomy technique.

2 | CASE 1

The case was a 49-year-old woman. There were uterine fibroids and anemia (Hb: 12.8 g/dl), while there were no special notes on family history. In October 2015, she consulted her otolaryngology clinic for right tonsillar swelling. Imaging examination revealed a neoplastic lesion in the parapharyngeal space, and fine needle aspiration cytology revealed a suspected pleomorphic adenoma. She was referred to our hospital in May 2016. The right upper neck was slightly swollen. In oral findings, severe swelling was observed in the right tonsils, but no occlusal mutation was observed. On MR imaging, a tumor lesion with a maximum diameter of 62 mm was found in the right parapharyngeal space, showing a low signal on the T1-weighted image and an unevenly high signal on the T2-weighted image (Figure 1A,B). No abnormalities were observed on a panoramic radiography (Figure 2A).

The patient agreed to a tumor removal using a double mandibular split osteotomy technique, so a joint operation with oral surgeons under general anesthesia was planned. To record the preoperative occlusal position, oral surgeons performed an impression of the upper and lower dentition using an alginate impression material and an occlusion by a silicone-based impression material. A surgical stent was prepared preoperatively based on them.

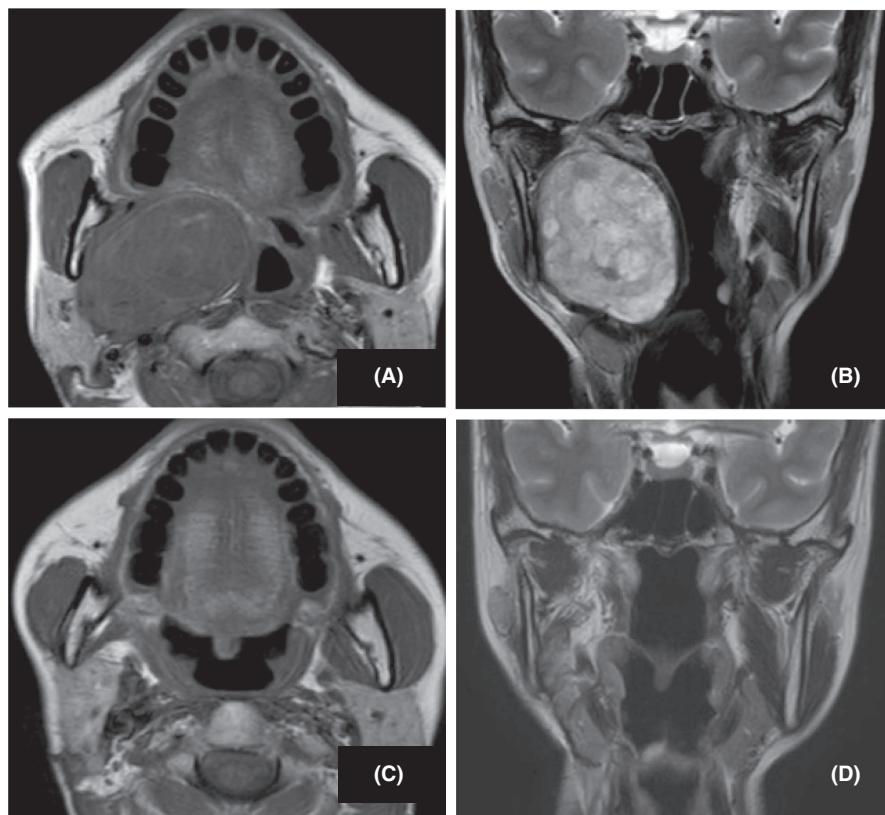


FIGURE 1 MR imaging of Case 1. (A) Preoperative T1-weighted horizontal section. (B) Preoperative T2-weighted coronal section. (C) T1-weighted horizontal section at 3 years and 10 months after the operation. (D) T2-weighted coronal section at 3 years and 10 months after the operation

FIGURE 2 Panoramic radiograph of Case 1. (A) Preoperative. (B) One day after the operation. (C) One year and 5 months after the operation (the mandibular metal plates are removed).

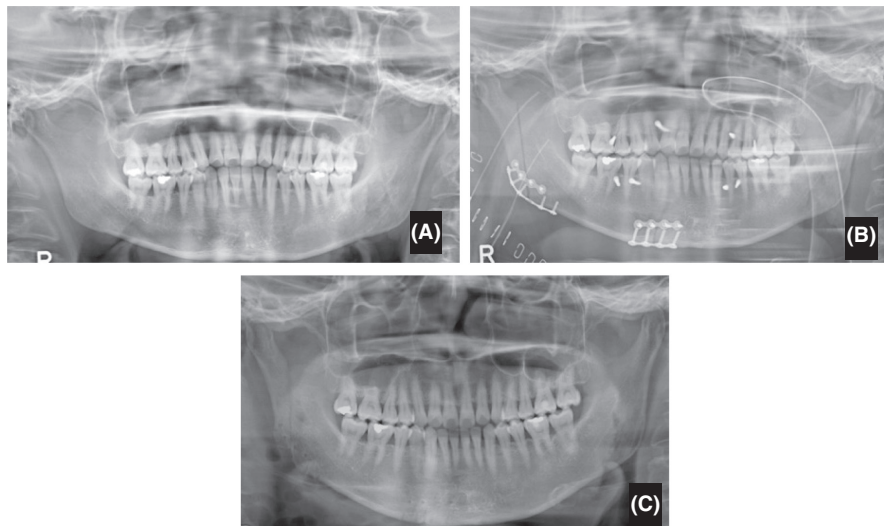
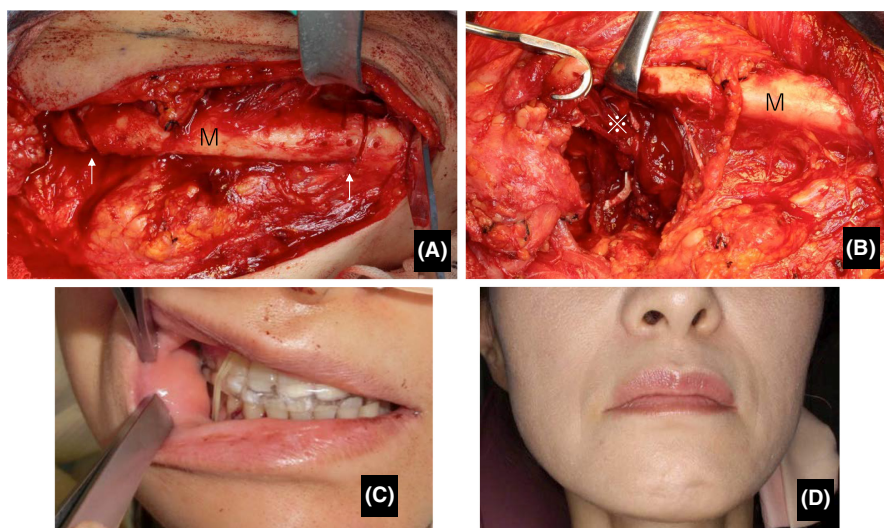


FIGURE 3 Surgical and postsurgical viewing of Case 1. (A) A double mandibular split osteotomy on the right side is performed completely. (B) After tumor resection. (C) A surgical stent is attached to confirm restoration of the occlusal position. (D) Postsurgical face appearance without a cosmetic problem. M—mandible. Asterisk—medial pterygoid muscle. Arrows—split position



The surgery was first started by otolaryngologists. The skin was incised from the lower part of the right auricle to the anterior part of the submandibular area, and the flap was raised until the lower margin of the mandible. The mandibular branch of the facial nerve was preserved and placed on the flap side. From this point on, the operation was performed by an oral surgeon. The subperiosteal detachment was performed on the mandible, and the mental nerve was identified and preserved. The mucoperiosteal flap was detached until the cervical part of the canine tooth and lifted toward the posterior part until the mandibular notch. To preserve a mandibular nerve between the mental and the mandibular foramen, double mandibular vertical splits were used. The first split was made anterior to the mental foramen, which cut longitudinally between the right lower canine and the first premolar. The second vertical split was made behind the mandibular foramen, from the mandibular notch to the mandibular angle. In order to accurately reposition the cut surface of the bone,

the metal plate for fixing between the bone fragments was adapted beforehand and the bone was temporarily fixed with screws. After removing those temporal plates, a double mandibular split osteotomy was performed completely. The segmental mandibular body was turned toward the head side to obtain the visual field, and the tumor was removed by an otolaryngologist (Figure 3A,B). After tumor resection, a surgical stent made before the operation was attached to confirm restoration of the occlusal position (Figure 3C). An intermaxillary fixation screw was implanted, and intermaxillary fixation was performed with a wire. Finally, two split lines of the mandible were fixed by the metal plates (Figure 2B).

Two days after the operation, the intermaxillary fixation was changed to rubber traction, and nasal tube feeding was started. Mild paralysis of the mandibular branch of the facial nerve and the mental nerve was noted but recovered. Seven days after the operation, the rubber traction was released, and the patient was discharged due to

good progress. One year and 5 months after the operation, the mandibular metal plates were removed (Figure 2C). Three years and 10 months after the operation, the condition is good without recurrence (Figure 1C,D and 3D). The pathological diagnosis after the operation was pleomorphic adenoma.

3 | CASE 2

The case was a 41-year-old woman with a premature ventricular contraction. She underwent tonsillectomy at age 9 years. There were no special notes on family history. In February 2016, she consulted her otolaryngology clinic for a right-sided displacement of the uvula and was referred to our hospital in March 2016. A swelling was observed around the left tonsils. No occlusal mutation was observed. On MR imaging, a tumor lesion with a maximum diameter of 40 mm was found in the left parapharyngeal space, showing a moderate signal on the T1-weighted image and an unevenly high signal on the T2-weighted image (Figure 4A,B). No abnormalities were observed on a panoramic radiography (Figure 5A).

An operation under general anesthesia with otolaryngologists and oral surgeons was performed. In the operation, similar surgical procedures to those of Case 1 were selected (Figure 5B).

After the operation, mild paralysis of the mandibular branch of the facial nerve and the mental nerve was found. Moreover, a strong opening disorder was observed immediately after releasing the intermaxillary fixation. However, those symptoms showed improvement. One

year and 8 months after the operation, the mandibular metal plates were removed (Figure 5C). Three years and 2 months after the operation, the condition is good without recurrence (Figures 4C,D and 6). The postoperative pathological diagnosis was pleomorphic adenoma.

4 | DISCUSSION

The anatomical boundaries of the parapharyngeal space are: the external skull base is above; the pharyngeal constrictor muscle and the pharyngeal wall are inside; the medial pterygoid muscle, the parotid gland, the posterior belly of digastric muscle, and the mandible are outside; the posterior cervical vertebrae and the anterior vertebrae are backward; and the hyoid bone is below; therefore, this space is an inverted conical gap. The parapharyngeal space is further divided into pre- and poststyloid spaces by the styloid process and the attached stylopharyngeus muscle, styloglossus muscle, and stylohyoid muscle (the stylomandibular ligament).² The prestyloid space contains the external carotid artery and parotid deep lobe, and the poststyloid space contains the internal carotid artery, internal jugular vein, cranial nerve (IX, X, XI, and XII), sympathetic nerve, and lymph node.

Parapharyngeal space tumor is a general term for tumors that have developed in the parapharyngeal space. Of the tumors that occur in the head and neck region, the incidence of parapharyngeal space tumors is about 0.5%, which is a relatively rare disease. About 90% of parapharyngeal space tumors is benign, and most tumor in the prestyloid space is pleomorphic adenoma derived from

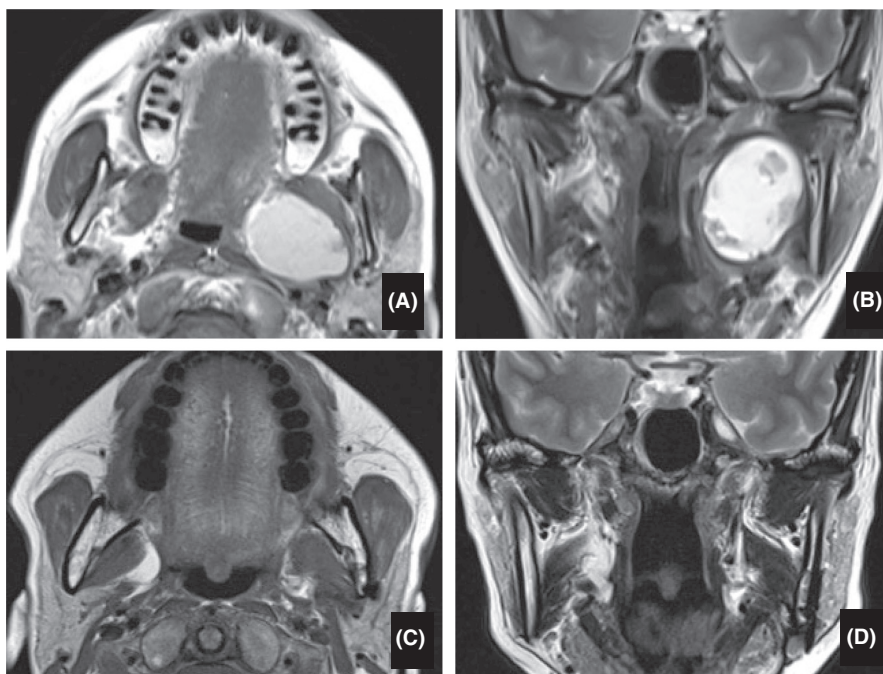


FIGURE 4 MR imaging of Case 2. (A) Preoperative T1-weighted horizontal section. (B) Preoperative T2-weighted coronal section. (C) T1-weighted horizontal section at 3 years and 2 months after the operation. (D) T2-weighted coronal section at 3 years and 2 months after the operation

FIGURE 5 Panoramic radiograph of Case 2. (A) Preoperative. (B) One day after the operation. (C) One year and 8 months after the operation (the mandibular metal plates are removed)

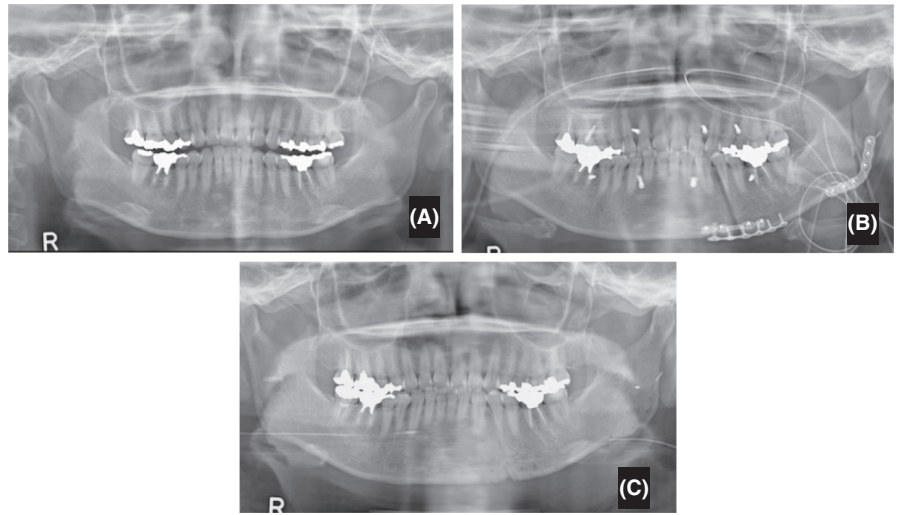
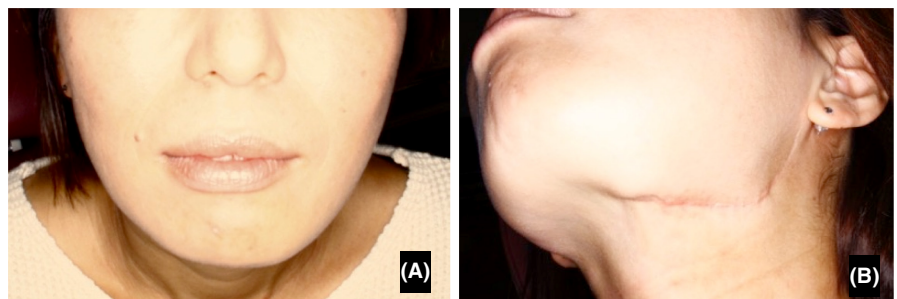


FIGURE 6 Postsurgical viewing of Case 2. (A) Postoperative face appearance without a cosmetic problem. (B) The skin scar after incision from the lower part of the left auricle to the anterior part of the submandibular area



the parotid gland, while that in the poststyloid space is schwannoma derived from nerve tissue.¹ Due to the anatomical characteristics mentioned above, symptoms of parapharyngeal space tumors often do not appear until the tumor grows until 40 to 50 mm in size, and it is often found by chance on CT or MRI. The part surrounded by the skull base, the mandibular joint process, and the styloid mandibular ligament is called the stylomandibular tunnel, which plays as a constriction between the deep parotid gland and the parapharyngeal space.⁴ When the tumor originating from the parotid deep lobe like pleomorphic adenoma spreads to the pharynx and is strangled by this tunnel, it exhibits a dumbbell shape. The presence of styloid increases the risk of tumor capsule damage during intraoperative manipulation because it is difficult to visually recognize the uppermost part of the tumor by the transcervical method in a case of a tumor in which the apex reaches near the external skull base. The tumor is often blindly removed manually in this case. Practically, Okamoto et al demonstrated that cervical approach procedures in the vicinity of the cranial base should cause capsule rupture during surgery. Rupture of the pleomorphic adenoma capsule risks disseminating the tumor and causing multiple recurrences. In order to remove the tumor without rupture as much as possible, it is desirable to place the apex of the tumor under the clear surgical vision. For this reason, many surgeons have proposed a

technique to cut the mandible once to ensure a wide field of view during surgery and to operate safely in a protective manner. There have been many methods regarding the mandibular amputation.³ As one of those, a midline single osteotomy is performed in many medical facilities. In this method, the hemimandible is swung around the temporomandibular joint without damage of the mandibular nerve, and a parapharyngeal space tumor can be removed safely. However, this method requires a midline incision in the lower lip, which has the cosmetic disadvantage of leaving scars after surgery. Lazaridis et al.³ showed another technique in 2003 without a midline single osteotomy accompanied by a lower lip incision but with double splits method on the mandibular body. In this technique, one vertical split was made anterior to the mental foramen and another was made at the base of the condylar process; therefore, parapharyngeal tumors can be resected without the lip incision. On the contrary, in 2007, Kolokythas et al.² improved the Lazaridis et al.'s method in which a vertical ramus mandibulae osteotomy was done instead of a basal condylar process osteotomy. This method avoided a preauricular parotid incision and a lower lip incision. We followed the method of Kolokythas in this report. In both methods, the oral cavity cannot be breached and the mylohyoid muscle can be preserved. Okamoto et al suggested that one of the demerits in the mandibular osteotomy was postsurgical malocclusion.¹ However, in our two

cases, restoration of the occlusal position was reproduced by a surgical stent and no malocclusion was found after surgery. In addition, paralysis of the mandibular branch of the facial nerve and the mental nerve was insignificant after surgery. The tumor could be removed completely without a cosmetic problem. Until now, the patient's condition has been good without recurrence.

Consequently, this double-split osteotomy technique is useful in removing the parapharyngeal space tumor.

AUTHOR CONTRIBUTIONS

Shinichiro Kato: Writing – original draft. **Kei Ijichi:** Supervision. **Asako Fukushima:** Data curation. **Tomohisa Nakamura:** Data curation. **Hiroyuki Takashima:** Data curation. **Tsuyoshi Nabeta:** Data curation. **Hironori Miiyamoto:** Data curation. **Kenichiro Ishibashi:** Data curation. **Shuhei Tsuchiya:** Data curation. **Sumiyo Hishida:** Data curation. **Yasuyuki Shibuya:** Supervision.

ACKNOWLEDGMENTS

None.

CONFLICT OF INTEREST

None declared.

DATA AVAILABILITY STATEMENT

The data that support the findings of this study are openly available in [repository name e.g “figshare”] at [http://doi.org/\[doi\]](http://doi.org/[doi]), reference number [reference number].

CONSENT

The authors obtained written consent for publication from the patients.


ETHICAL APPROVAL

Not applicable.

ORCID

Shinichiro Kato  <https://orcid.org/0000-0002-4691-8322>

Tomohisa Nakamura  <https://orcid.org/0000-0002-8222-9225>

Yasuyuki Shibuya  <https://orcid.org/0000-0001-6332-1483>

REFERENCES

1. Okamoto I, Tsukahara k, Tsukahara K, Sato H. Parapharyngeal space tumor surgery using a modified cervical-parotid approach. *Acta Otolaryngol.* 2018;138:165-169.
2. Kolokythas A, Fernandes RP, Ord R. A non-lip-splitting double mandibular osteotomy technique applied for resection of tumors in the parapharyngeal and pterygomandibular spaces. *J Oral Maxillofac Surg.* 2007;65:566-569.
3. Lazaridis N, Antoniadis K. Double mandibular osteotomy with coronoidectomy for tumours in the parapharyngeal space. *Br J Oral Maxillofac Surg.* 2003;41:142-146.
4. Abrahams JJ, Culver RR, Kalra VB. Stylomandibular tunnel widening versus narrowing: a useful tool in evaluating suprahyoid mass lesions. *Clin Radiol.* 2014;69:e450-e453.

How to cite this article: Kato S, Ijichi K, Fukushima A, et al. Two cases of parapharyngeal space tumor resected by a double split mandibular osteotomy technique. *Clin Case Rep.* 2022;10:e06786. doi:[10.1002/ccr3.6786](https://doi.org/10.1002/ccr3.6786)