


RESEARCH ARTICLE

Intralesional margin after excision of a high-grade osteosarcoma: Is it a catastrophe?

Panagiotis Tsagkosis^{1,2,3}  | Czar L. Gaston^{1,4} | Emelie Styring⁵ | Felix Haglund⁶ | Robert Grimer¹

¹The Royal Orthopaedic Hospital Oncology Service, Royal Orthopaedic Hospital, Birmingham, UK

²Musculoskeletal Tumor Service, Karolinska University Hospital, Stockholm, Sweden

³Department of Molecular Medicine and Surgery, Karolinska Institute, Stockholm, Sweden

⁴Department of Orthopaedics, University of the Philippines Manila–Philippine General Hospital, Manila, Philippines

⁵Department of Orthopaedics, Skane University Hospital, Lund University, Lund, Sweden

⁶Department of Oncology-Pathology, Karolinska Institute, Stockholm, Sweden

Correspondence

Panagiotis Tsagkosis, Musculoskeletal Tumor Service, Karolinska University Hospital, Solna 17176, Stockholm, Sweden.

Email: panagiotis.tsagkosis@regionstockholm.se

Abstract

Background and Objectives: Treatment of high-grade osteosarcoma (OS) relies on a combination of systemic chemotherapy and radical surgical excision of the tumor. Little is known on what happens in case of an irrefutably inadequate (intralesional) margin. We aimed to describe the outcome of patients with high-grade OSs of the trunk and the extremities where planned wide resection resulted in an intralesional margin.

Methods: A retrospective study from the Scandinavian Sarcoma Group registry and the Royal Orthopaedic Hospital databases including data from 53 patients surgically treated between the years 1990 and 2017.

Results: Local recurrence was observed in 13/53 patients. All patients with local recurrence where the neoadjuvant chemotherapy response could be retrieved ($n = 9$) were shown to be poor responders. None of the patients with good response to chemotherapy relapsed. Postoperative radiotherapy was not associated with improved local control of the disease. Re-excision surgery was performed in only seven patients, and two of them had tumor relapse.

Conclusions: Good response to chemotherapy salvages the outcome of surgical excision with a poor margin in patients with high-grade OSs and a watchful waiting strategy may be justified in these cases. Poor responders have a higher recurrence risk and their approach should be individualized.

KEYWORDS

chemotherapy, intralesional surgery, osteosarcoma, recurrence

1 | INTRODUCTION

A wide surgical margin is imperative in the treatment of osteosarcoma (OS) to reduce the risk of local relapse.¹ However, adequate margins are not always achieved, even in the hands of experienced surgeons.

Although there is no consensus on how radical the resection should be, an intralesional margin is absolute proof that microscopic contamination is present and has thus been considered a surgical disaster. Whether this is true and how to deal with this scenario is obscure since it fortunately happens quite rarely. The current ESMO guidelines do

This is an open access article under the terms of the Creative Commons Attribution-NonCommercial-NoDerivs License, which permits use and distribution in any medium, provided the original work is properly cited, the use is non-commercial and no modifications or adaptations are made.

© 2022 The Authors. *Journal of Surgical Oncology* published by Wiley Periodicals LLC.

TABLE 1 Patient demographics

Eligible patients (SSG/ROH)	53 (27/26)
Response to chemotherapy	
Good	8
Poor	24
Unknown	21
Gender	
Female	30
Male	23
Mean/median age in years	25/17
Mean/median size (cm)	11/10
Site	
Humerus	12
Femur	11
Pelvis	9
Ribs	8
Tibia	4
Other	9
Histology	
Osteoblastic	24
Mixed	6
Chondroblastic	4
Telangiectatic	3
Fibroblastic	1
Unknown	15
Radiotherapy	
Yes	14
No	35
Unknown	4

not include a formal recommendation, whilst consideration of postoperative radiotherapy was recommended in the EURAMOS study.^{2,3} Whether re-excision should be performed is unknown, and data supporting its use comes from mixed cohorts of patients where the primary surgery may also have entailed incomplete macroscopic removal of the tumor, for example, during unplanned surgery or open biopsy, or from low-grade OS.^{4,5} Primary amputation in the case of extremity tumors may also be a theoretical option to optimize local control, although it has not been shown to improve overall patient survival.⁶

We investigated the clinical outcome of patients treated with surgery and chemotherapy for high-grade OS, where the surgical resection resulted in a contaminated (intralesional) surgical margin, focusing on the local control of the disease and patient survival.

2 | PATIENTS AND METHODS

The study cohort was retrieved from two major prospectively collected databases, the Scandinavian Sarcoma Group registry and the database of the Royal Orthopaedic Hospital in Birmingham. Inclusion criteria were patients with high-grade OS of the trunk or extremities, without any evidence of metastases at presentation, and with a minimum of 1 year of follow-up for patients that were alive. The study population consisted of 53 patients (30 female) treated between 1990 and 2017. The characteristics of the cohort are shown in Table 1. Oncological treatment was with cisplatin/doxorubicin/methotrexate-based schemes (EURAMOS/SSG II/SSG VIII) for patients below 40 years of age, and Euroboss (or equivalent) for the others. Follow-up was according to the ESMO guidelines. The median duration of follow-up for patients alive at the last follow-up was 7 years (mean 8 years).

Details about the extent of the positive margin and whether the tumor had been inadvertently cut through and the whole area later excised, or whether the finding of the positive margin was only identified on analysis of the resected specimen were not available.

The study was in accordance with the Helsinki Declaration (1975, revised 1983). Survival analysis was done in the SPSS (version 25, SPSS Inc), using the Kaplan–Meier technique and comparisons between groups were done using the log-rank test. Competing risk survival analysis was done in SAS (version 9.4, www.sas.com) using the Fine and Gray model. Pearson's χ^2 test was used for comparisons between categorical variables. All tests were double-sided, a p value of ≤ 0.05 was considered as statistically significant.

3 | RESULTS

3.1 | Local recurrence rate and overall patient survival

Of the 53 patients in the cohort, 13 (25%) experienced a local recurrence of the tumor. The median time to local recurrence was 20 months (range: 5–42). The local recurrence rate was 20% at 2 years and 31% at 5 years after the primary surgery (Figure 1).

At final follow-up, 22 patients were alive. Overall patient survival was 71% at 2 years and 40% at 5 years after the primary surgery (Figure 2A). Survival for the patients who experienced local recurrence was 32% at 2 years and 11% at 5 years after the event of local recurrence (Figure 2B).

3.2 | Effect of chemotherapy response on the local recurrence rate

Chemotherapy response could be retrieved for 32 patients. Of these, only eight patients displayed a good chemotherapy response, with

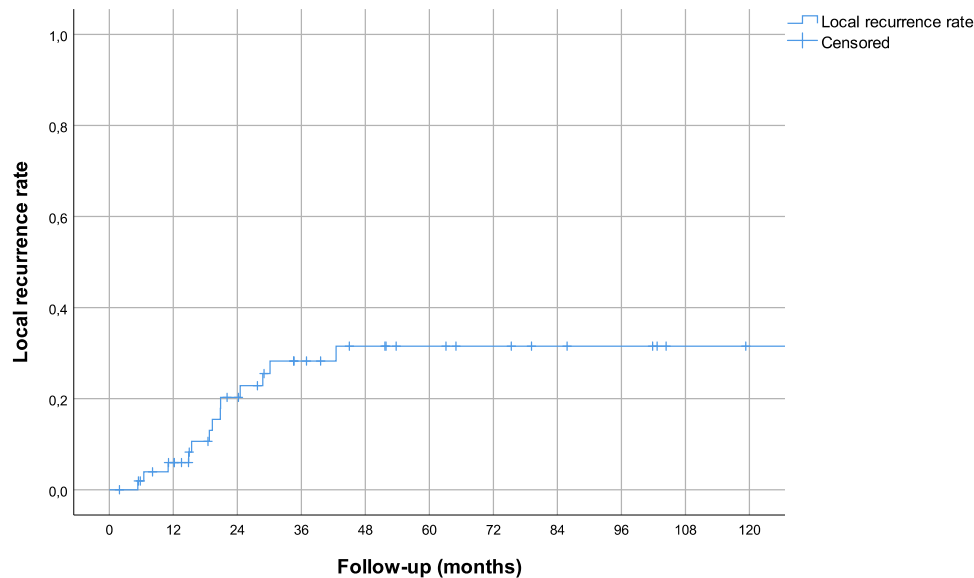


FIGURE 1 Local recurrence rate for patients with high-grade osteosarcomas of the trunk and the extremities where the surgical margin was intralesional.

necrosis of at least 90%. Of these, none suffered a local tumor recurrence. Of the remaining 24 who had poor response, 9 (39%) experienced a local recurrence. There were four local recurrences in cases where the chemotherapy response rate could not be retrieved.

The association of chemotherapy response on local control of the disease was also obvious in the survival analysis, where good responders had a significantly superior local recurrence-free survival rate ($p = 0.001$) and disease-free survival rate ($p = 0.003$; Figure 3). Using competing risk survival analysis, with death as a competing event for local recurrence, the association of a good response to radiotherapy with local control of the disease remained significant ($p = 0.042$).

3.3 | Effect of adjuvant radiotherapy and re-excision surgery

Data about adjuvant radiotherapy were known for 48 patients. Of these, 14 had postoperative radiotherapy treatment, with a dose of 60–66 Gy. Postoperative radiotherapy was not associated with an improved local control rate in poor responders ($p = 0.156$) or the whole cohort ($p = 0.324$).

Re-excision after the initial operation was attempted in only seven patients. All of these were local re-excisions, and none underwent an amputation. Surgical margins after the last operation were intralesional in two patients, marginal in two, and wide in three. Two of these seven patients suffered a local recurrence (one who had a marginal margin at last operation and one who had wide margin). Re-excision had no effect on the local recurrence rate of the disease for poor responders to chemotherapy ($p = 0.656$) or the whole cohort ($p = 0.814$).

4 | DISCUSSION

The primary aim of the orthopedic oncologist when treating a patient with an OS is to remove the tumor with a good surgical margin. Intralesional margins have been shown to be associated with a higher risk of local tumor recurrence in previous studies.^{7–10} There are, however, data from challenging locations such as the proximal fibula supporting that it may not be as detrimental as thought.^{11,12} Furthermore, what to do when this happens is largely unexploited.

This may clearly depend on the extent of the positive margin and whether it is identified during the operation or is only later found on histological analysis of the specimen. In the former situation, most surgeons would probably consider taking a “wider” margin at the time and possibly considering postoperative radiotherapy, whilst in the latter situation, the decision is likely to be made by the whole multidisciplinary team. In this scenario, the treating team face a dilemma: Should they suggest re-excision, or even more radical surgery such as amputation, should they administer radiotherapy, or should they just rely on the adjuvant effect of chemotherapy? We recognize that none of these questions can be safely answered even in our study, which to our knowledge reports on the largest cohort of OS in patients where the margins were contaminated, given the rarity of the condition and the general limitations of a retrospective study where there is heavy treatment bias. Yet, we believe we provide valuable information on the oncological outcome in this context, which hopefully helps physicians, patients, and their families in informed decision-making. Another limitation is that we have no detailed information on the quality of the margins, that is, the extent of tumor contamination. Theoretically, most margin violations would be at the microscopical level. Furthermore, missing information on chemotherapy response in many patients is a further shortcoming of this study.

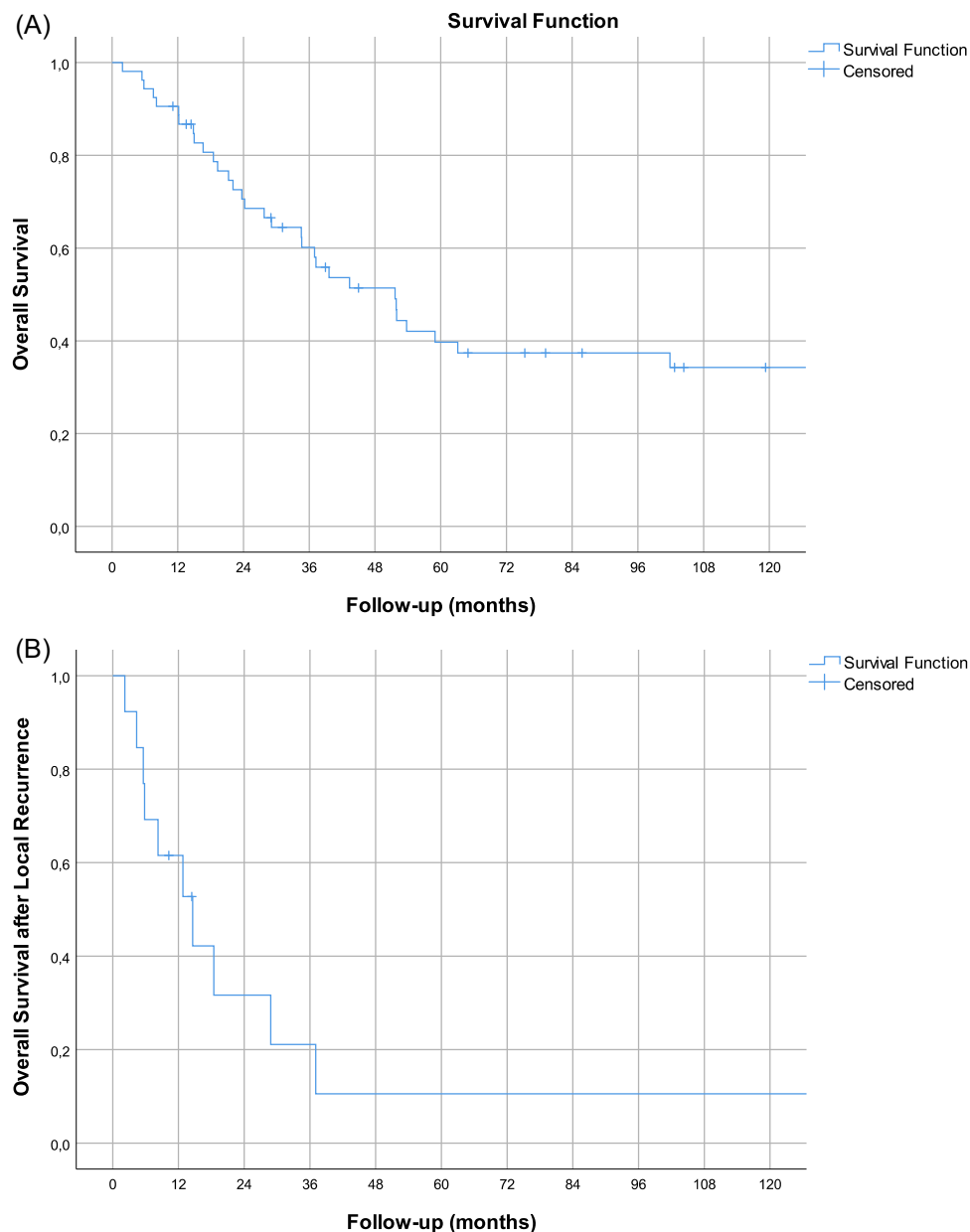


FIGURE 2 Overall survival rate for patients with high-grade osteosarcomas of the trunk and the extremities where the surgical margin was intralesional (A). Overall survival rate after local recurrence of the tumor (B).

We have also not been able to retrospectively identify the reasons why there was a positive margin and whether this was a failure of surgical planning or an unexpected finding. Certainly, in some cases, particularly poor responders, there may have been tumor progression between the time of the latest scan and the date of surgery, and this emphasizes the importance of timely scans, especially in patients who do not appear to be responding to chemotherapy.

Our first observation was that poor responders to chemotherapy were clearly overrepresented in this cohort, which implies that a good response to chemotherapy can facilitate the surgeon in achieving a tumor-free margin. The major finding in this study, however, was that good response to adjuvant chemotherapy could compensate for a

poor margin. Indeed, in our cohort, there were no local relapses in the group of patients who were good responders to chemotherapy. This should by no means give the surgeon the false impression that chemotherapy can be the remedy for bad surgery, and the primary goal should always be for a wide margin. Even in our cohort, the surgical intention was for a wide margin, and this as a rule results in better oncological outcome even if the final surgical result was inferior to the one expected. On the other hand, this observation supports the notion that surgery should be performed even in cases where there is a risk for microscopically contaminated margins, especially when the clinical and radiological data during neoadjuvant chemotherapy suggest that the patient is a good responder. This means that decisions where patients are deemed to be inoperable

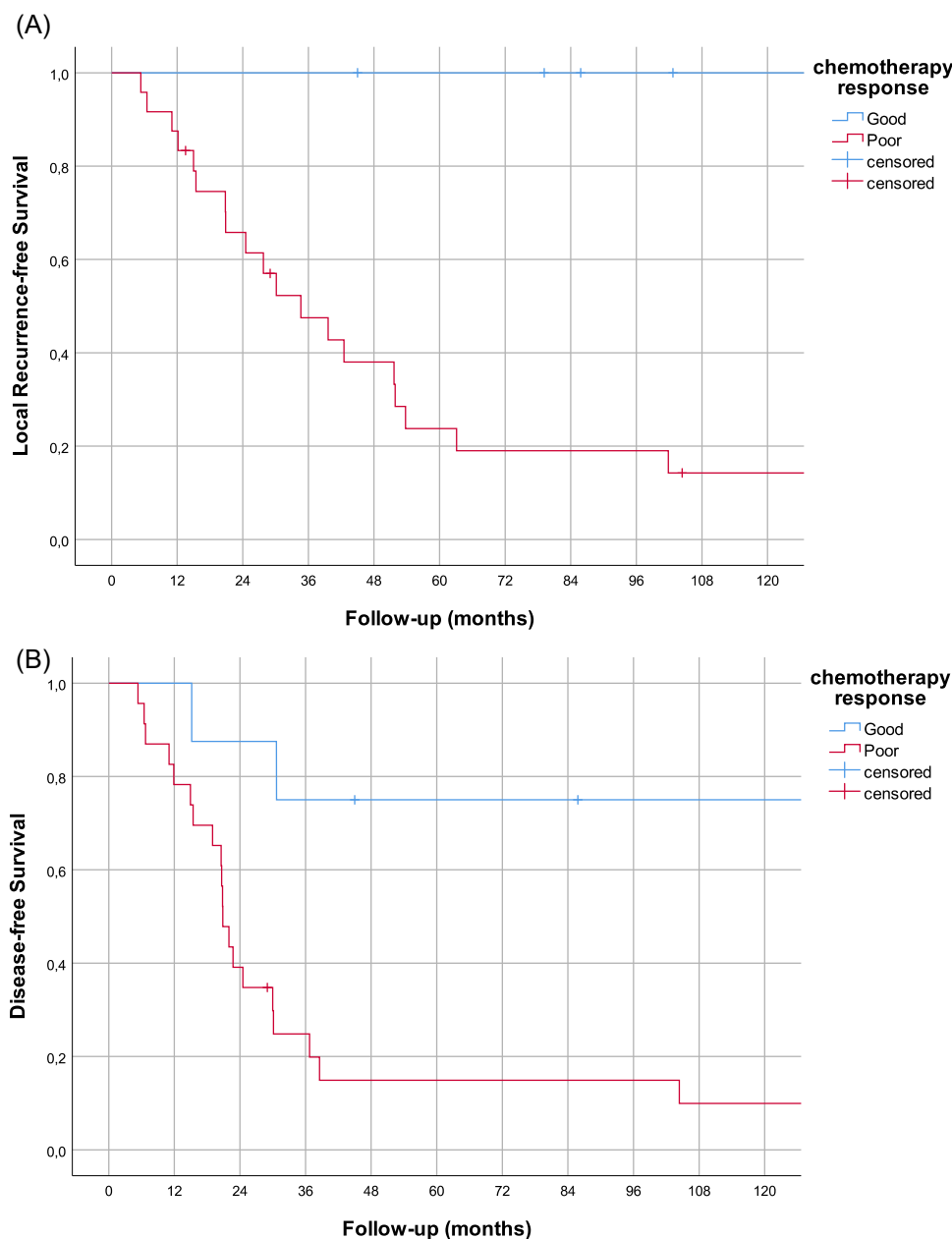


FIGURE 3 Local recurrence-free survival rate for patients with high-grade osteosarcomas of the trunk and the extremities where the surgical margin was intralesional, depending on the chemotherapy response (A). Disease-free survival rate of the same cohort (B).

due to the size and extension of the primary tumor should be carefully considered.

Even our cohort is not large enough to draw conclusion regarding the value of adjuvant radiotherapy or re-excision/amputation regarding local control of the disease. It should however be noted that re-excision was performed in very few cases. This probably reflects the nature of the intralesional margin, which is often at the microscopical level. Re-excision may be useful in cases of gross tumors left behind.¹³ Regarding the use of postoperative radiotherapy, we cannot draw any firm conclusions, and our data support the notion that its effect is probably marginal, if any at all. Given the lack of data to support any treatment recommendations, we believe it

may be considered in selected cases of poor responders where there are not any significant side effects associated with its use and when a possible local recurrence is expected to be very difficult to address surgically.

Finally, the overall oncological outcome in this cohort of patients did not differ significantly from the expected overall survival of OS patients. Furthermore, poor responders who had a local tumor recurrence had similar overall survival to the ones who did not. This fact strengthens the view that response to chemotherapy is the major treatment-associated factor determining patient survival, while the quality of surgery has an impact primarily on the local control of the disease.¹⁴

5 | CONCLUSIONS

In adequately planned surgery, even when the surgeon fails and violates the tumor margin, a good response to chemotherapy is apparently able to rescue the outcome and prevent a surgical catastrophe. In these cases, a careful watch-and-wait policy seems reasonable. When there is a poor response to chemotherapy, treatment decisions are more difficult and should be taken in an individualized basis recognizing the lack of evidence. They should take into account the expected morbidity of additional surgical excision, the feasibility of giving high-dose radiotherapy, and the operability of a potential local recurrence vis-a-vis the expected survival, overall condition, and expectations of the patient.

CONFLICTS OF INTEREST

The authors declare no conflicts of interest.

DATA AVAILABILITY STATEMENT

The (anonymized) data that support the findings of this study are available upon reasonable request from the corresponding author

ORCID

Panagiotis Tsagkozis  <https://orcid.org/0000-0002-6631-2053>

REFERENCES

- Bacci G, Forni C, Longhi A, et al. Local recurrence and local control of non-metastatic osteosarcoma of the extremities: a 27-year experience in a single institution. *J Surg Oncol*. 2007;96(2):118-123.
- Casali PG, Bielack S, Abecassis N, et al. Bone sarcomas: ESMO-PaedCan-EURACAN Clinical Practice Guidelines for diagnosis, treatment and follow-up. *Ann Oncol*. 2018;29(Suppl 4):iv79-iv95.
- Smeland S, Bielack SS, Whelan J, et al. Survival and prognosis with osteosarcoma: outcomes in more than 2000 patients in the EURAMOS-1 (European and American Osteosarcoma Study) cohort. *Eur J Cancer*. 2019;109:36-50.
- Ogihara Y, Sudo A, Fujinami S. Inadvertent tumor violation during musculoskeletal sarcoma surgery and risk of recurrence. *Jpn J Clin Oncol*. 1992;22(4):264-269.
- Song WS, Jeon DG, Kong CB, Cho WH, Lee SY. Outcome of re-excision for intralesionally treated parosteal osteosarcoma. *J Surg Oncol*. 2011;103(3):264-268.
- Reddy KI, Wafa H, Gaston CL, et al. Does amputation offer any survival benefit over limb salvage in osteosarcoma patients with poor chemonecrosis and close margins? *Bone Joint J*. 2015;97-B(1):115-120.
- Bertrand TE, Cruz A, Binitie O, Cheong D, Letson GD. Do surgical margins affect local recurrence and survival in extremity, nonmetastatic, high-grade osteosarcoma? *Clin Orthop Relat Res*. 2016;474(3):677-683.
- He F, Zhang W, Shen Y, et al. Effects of resection margins on local recurrence of osteosarcoma in extremity and pelvis: systematic review and meta-analysis. *Int J Surg*. 2016;36(Pt A):283-292.
- Bielack SS, Kempf-Bielack B, Delling G, et al. Prognostic factors in high-grade osteosarcoma of the extremities or trunk: an analysis of 1,702 patients treated on neoadjuvant cooperative osteosarcoma study group protocols. *J Clin Oncol*. 2002;20(3):776-790.
- Bacci G, Longhi A, Versari M, Mercuri M, Briccoli A, Picci P. Prognostic factors for osteosarcoma of the extremity treated with neoadjuvant chemotherapy: 15-year experience in 789 patients treated at a single institution. *Cancer*. 2006;106(5):1154-1161.
- Kanazawa Y, Tsuchiya H, Nonomura A, Takazawa K, Yamamoto N, Tomita K. Intentional marginal excision of osteosarcoma of the proximal fibula to preserve limb function. *J Orthop Sci*. 2003;8(6):757-761.
- Schneiderbauer MM, Gullerud R, Harmsen WS, Scully SP. Fibular osteosarcomas: contaminated margins may not impact survival. *Clin Orthop Relat Res*. 2007;456:182-187.
- Shankar GM, Clarke MJ, Ailon T, et al. The role of revision surgery and adjuvant therapy following subtotal resection of osteosarcoma of the spine: a systematic review with meta-analysis. *J Neurosurg Spine*. 2017;27(1):97-104.
- Mankin HJ, Hornicek FJ, Rosenberg AE, Harmon DC, Gebhardt MC. Survival data for 648 patients with osteosarcoma treated at one institution. *Clin Orthop Relat Res*. 2004;429:286-291.

How to cite this article: Tsagkozis P, Gaston CL, Styling E, Haglund F, Grimer R. Intralesional margin after excision of a high-grade osteosarcoma: Is it a catastrophe? *J Surg Oncol*. 2022;126:787-792. doi:10.1002/jso.26926