



Case report

A case of ovarian mucinous cystadenoma in a child that recurred 1 year after surgery

Ayaka Fujishima^{*}, Yukiyo Kumazawa, Kazue Togashi, Hiromitsu Shirasawa, Wataru Sato, Yukihiro Terada

Department of Obstetrics and Gynecology, Akita University Graduate School of Medicine, Akita, Japan



ARTICLE INFO

Keywords:

Mucinous cystadenoma
 Recurrence
 Children
 Laparoscopy
 Case report

ABSTRACT

Introduction and importance: In children, mature cystic teratomas are the most common ovarian tumors. Mucinous cystadenomas are rarely seen. Further, the recurrence of mucinous cystadenomas is very rare. This report describes a case of ovarian mucous cystadenoma in an adolescent that recurred 1 year after surgery.

Case presentation: A 13-year-old patient, with a sizable ovarian tumor underwent laparoscopic-assisted cystectomy. On histopathology, the tumor was diagnosed to be an ovarian mucinous cystadenoma. The mucinous cystadenoma recurred 13 months after surgery and subsequently laparoscopic right adnexectomy was performed. **Clinical discussion:** It has been reported that intraoperative cyst rupture and cystectomy instead of adnexectomy are risk factors for mucinous cystadenoma recurrence. Close follow-up is required for post-cystectomy patients because of the possibility of recurrence.

Conclusion: The risk of recurrence and the preservation of fertility should be carefully considered when deciding on treatment in young patients with a mucinous cystadenoma.

1. Introduction

Ovarian tumors in children are relatively rare, occurring at a rate of 2.6 per 100,000 girls per year. Most ovarian tumors in children are benign [1–3]. Ovarian tumors in children are more common in the 10–15-year age group, with mature cystic teratoma being the most common [2,3]. Mucinous cystadenoma accounts for 12–15% of all ovarian tumors in Europe and the United States, 20–23% in Japan, and up to 75–80% of all mucinous tumors. The peak incidence of mucinous cystadenoma occurs between 30 and 50 years of age; however, they rarely occur in children and adolescents [4,5]. Recurrent mucinous cystadenoma is rare [6,7]. This report describes a case of ovarian mucous cystadenoma in an adolescent that recurred 1 year after surgery. This report has been reported in line with the SCARE 2020 criteria [8].

2. Presentation of case

A 13-year-old presented to our hospital as a referral. She experienced menarche at age 11, and her menstrual cycle was irregular. No medical history, medication history, or allergies were noted. At age 12, she had

presented to another hospital with complaints of abdominal distension for 6 months duration. Computed tomography and magnetic resonance imaging (MRI) showed a 30 cm polycystic ovarian tumor (Fig. 1). Levels of the tumor markers CA125, CA19-9, carcinoembryonic antigen (CEA), alpha fetoprotein, and lactate dehydrogenase were within the normal range.

Laparoscopic-assisted cystectomy was performed. A 3-cm transverse incision was made in the lower abdomen. The contents of the ovarian tumor were aspirated and some of the tumor was moved out of the body through the incision, and the tumor was enucleated. The same procedure was repeated. The tumor originated from the right ovary and contained 5,575 mL of clear yellow serous and mucinous fluid. The tumor and a thin portion of the ovarian cortex were removed. Some contents leaked into the abdominal cavity during surgery. Three ports were inserted through the wound, and laparoscopic surgery was performed. The intra-abdominal space was washed with saline solution. The histopathological diagnosis was mucinous cystadenoma of the right ovary, with included normal ovarian tissue. Recovery was uneventful, and she was discharged from the hospital on the third postoperative day as usually and was scheduled for follow-up 1 year later.

Abbreviations: MRI, magnetic resonance imaging; CEA, carcinoembryonic antigen.

^{*} Corresponding author at: Department of Obstetrics and Gynecology, Akita University Graduate School of Medicine, 1-1-1 Hondo, Akita 010-8543, Japan.

E-mail address: fujishimaayaka@med.akita-u.ac.jp (A. Fujishima).

<https://doi.org/10.1016/j.ijscr.2021.106006>

Received 20 April 2021; Received in revised form 11 May 2021; Accepted 16 May 2021

Available online 20 May 2021

2210-2612/© 2021 The Author(s). Published by Elsevier Ltd on behalf of IJS Publishing Group Ltd. This is an open access article under the CC BY-NC-ND license

(<http://creativecommons.org/licenses/by-nc-nd/4.0/>).

At 13 months after surgery, she visited her previous doctor because of abdominal pain. She was referred to our hospital because MRI revealed a 24 cm mass that was suspected to be recurrence of mucinous cystadenoma of the right ovary (Fig. 1). CA125 levels were slightly elevated: 56.4 U/mL, CA19-9 and CEA were within the normal range.

We gave the patient and her parents detailed explanations and psychological counseling about the procedure, the risk of recurrence, and the associated fertility on several occasions. The patient finally opted for adnexectomy, did not wish to undergo oocyte cryopreservation. Right adnexectomy was performed by a single incision laparoscopic surgery at the navel (Fig. 2).

The tumor contained 2950 mL of mucinous fluid. The histopathological diagnosis was ovarian mucinous cystadenoma (Fig. 3). She was discharged from the hospital on the third postoperative day. We follow her up every 3 to 6 months, with consultation and counseling, to check for tumor recurrence in the contralateral healthy ovary and to monitor ovarian function.

3. Discussion

There is limited data on the recurrence of ovarian mucinous cyst adenomas. A literature search resulted in 10 cases from the first report in 2001 to the present [3,6,7,9–13] with 3 patients aged less than 20 years. The time to recurrence was less than 1 year in seven patients and less than 2 years in nine patients. Cystectomy was performed in all but one patient for which details were not available. Cowan et al. reported 14 cases of mucinous cyst adenoma in children and adolescents, but no recurrence [14].

Ben-Ami et al. revealed that recurrence after ovarian mucinous cystadenoma enucleation is significantly higher than with adnexectomy and that the risk of recurrence is related to intraoperative tumor rupture. Factors that may contribute to the risk of intraoperative tumor rupture include surgical procedure, surgeon proficiency, tumor size, and technical difficulties associated with pelvic adhesions from previous or concomitant surgeries [6]. On the contrary, Mizrachi et al. suggest that intraoperative cyst rupture and spillage of its content may not be associated with recurrence [15]. It is unclear whether recurrence is related

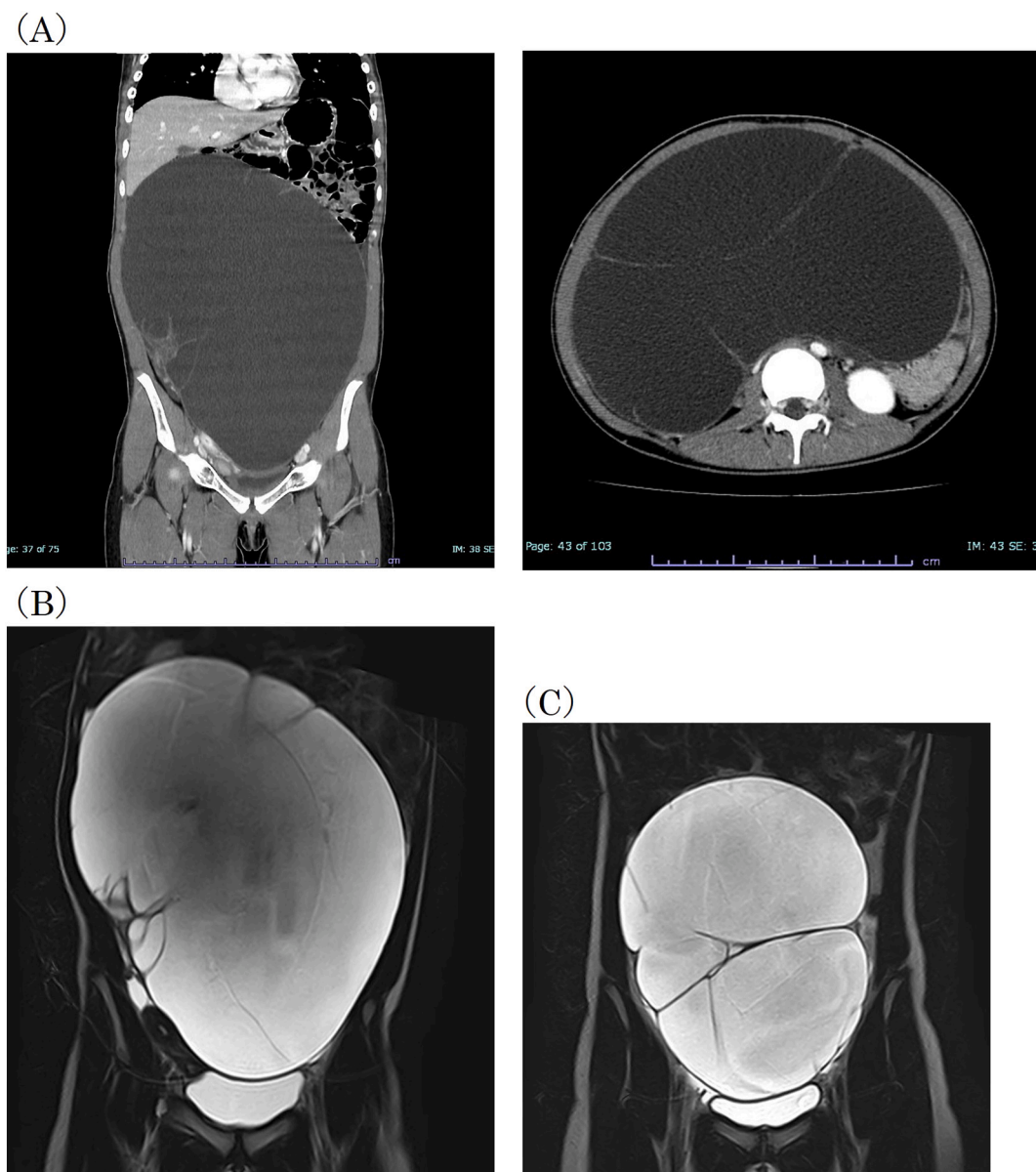


Fig. 1. (A, B) At the time of initial diagnosis, CT and MRI showed a large polycystic mass occupying the abdominopelvic cavity. (C) When the mucinous cystadenoma recurred, CT and MRI revealed a polycystic mass in the abdominopelvic cavity. CT: computed tomography, MRI: magnetic resonance imaging.

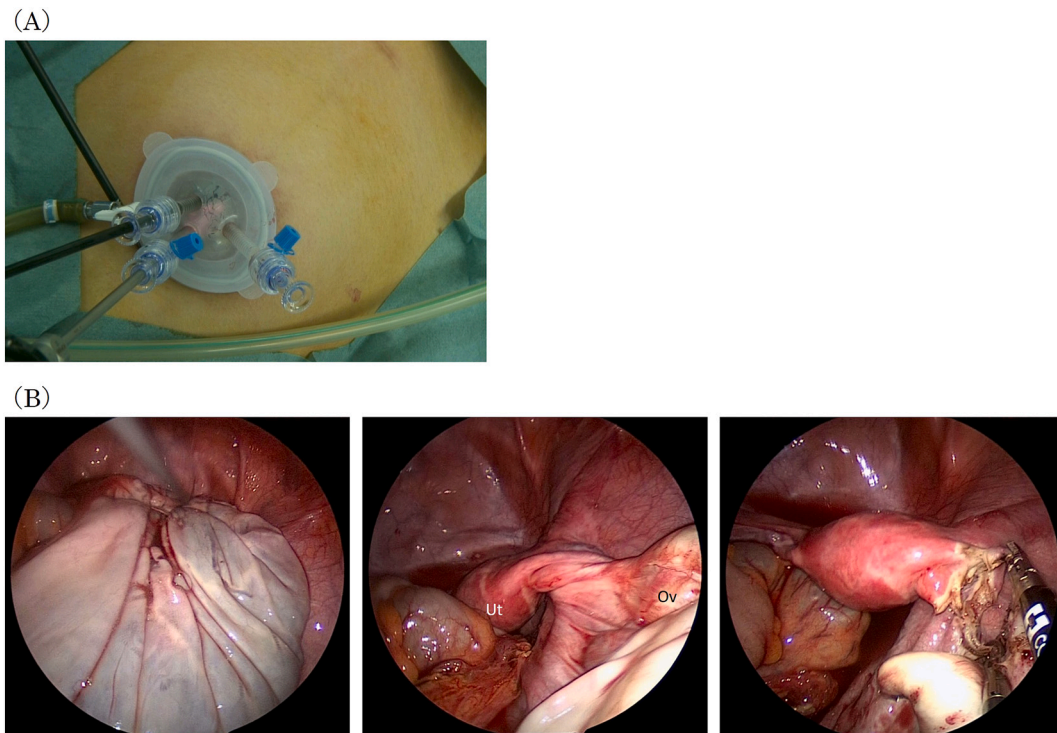


Fig. 2. (A) Three trocars were inserted into a small incision at the navel. (B) Laparoscopic view. Ut: uterus, Ov: Ovary.

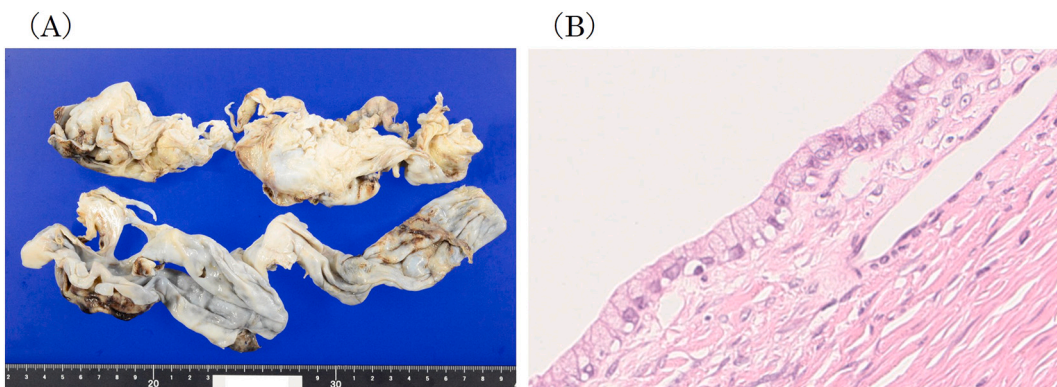


Fig. 3. (A) Macroscopic image of the adnexectomy specimen. (B) Microscopically, the cystic structure was lined with mucinous epithelium (hematoxylin and eosin, $\times 40$).

to rupture of the cyst and spillage of contents during surgery.

Another important factor related to recurrence of mucinous cystadenomas is whether the first surgical procedure included sufficient surgical excision. In our case, pathological examination of the initial surgical specimen revealed ovarian mucinous cystadenoma with normal ovarian tissue. Tumor retraction is one hypothesis for recurrence, but this did not occur in the present case. It may be possible that intra-operative tumor rupture contributed to recurrence.

The surgical approach for ovarian cysts depends on the patient's age, parity, cyst size and structure [16]. Since our patient had recurrence within 1 year of surgery and the tumor was growing rapidly, the risk of recurrence was considered to be high. Thus, we performed adnexectomy. If she wanted to preserve her ovary, she would need stricter follow-up. Recurrence in the contralateral ovary has also been reported in the past [3,7]. Regular follow-up was recommended in this case. At the time of recurrence in the contralateral ovary, the choice of surgical technique and oocyte cryopreservation for preservation of fertility should be considered.

4. Conclusion

In conclusion, post-cystectomy patients require close follow-up regardless of tumor type, due to the possibility of recurrence. In particular, the risk of recurrence and preservation of fertility should be comprehensively considered when deciding on a course of treatment for ovarian mucinous cystadenoma in young patients.

Sources of funding

This publication received no funding or grant support.

Ethical approval

According to the stipulations of Ethics Committee of Akita University, case reports that do not involve personal identification, research activities, and gene retrieval can be published "without review and approval".

Consent

The patient and her parents provided written informed consent for the publication of this case report and accompanying images. The report does not contain any personal information that could lead to patient identification.

CRedit authorship contribution statement

Ayaka Fujishima contributed to writing the paper, data collection and analysis.

Yukiyo Kumazawa contributed to conceptualization, data analysis and interpretation.

Kazue Togashi contributed to data collection.

Hinomitsu Shirasawa contributed to data analysis.

Wataru Sato contributed to data interpretation.

Yukihiro Terada contributed to project administration.

Research registration

None. This case report is not a 'First in Man' study.

Guarantor

Dr. Yukiyo Kumazawa accepts full responsibility for the work and/or study process. This author had access to the data, and controlled the decision to publish. Dr. Kumazawa would serve as the guarantor for the study.

Provenance and peer review

Not commissioned, externally peer-reviewed.

Declaration of competing interest

None.

Acknowledgments

We would like to thank Editage (www.editage.com) for English language editing.

References

- [1] O. Lindfors, Primary ovarian neoplasms in infants and children. A study of 81 cases diagnosed in Finland and Sweden, *Ann. Chir. Gynaecol. Fenn. Suppl.* 177 (1971) 1–66.
- [2] D.L. Cass, E. Hawkins, M.L. Brandt, M. Chintagumpala, R.S. Bloss, A.L. Milewicz, et al., Surgery for ovarian masses in infants, children, and adolescents: 102 consecutive patients treated in a 15-year period, *J. Pediatr. Surg.* 36 (2001) 693–699, <https://doi.org/10.1053/jpsu.2001.22939>.
- [3] T. Jimbo, H. Uchida, H. Kawashima, Y. Tanaka, K. Sato, S.Y. Takazawa, et al., A review of 58 ovarian tumors treated at a single children's hospital, *J. Jpn. Soc. Pediatr. Surg.* 47 (2011) 943–947.
- [4] V. Kumar, A.K. Abbas, N. Fausto, J.C. Aster, Robbins and Cotran Pathologic Basis of Disease. Professional ed E-Book 1026–1027, Elsevier Health Sciences, Philadelphia, 2014, pp. 1022–1023.
- [5] T. Sri Paran, A. Mortell, D. Devaney, A. Pinter, P. Puri, Mucinous cystadenoma of the ovary in perimenarchal girls, *Pediatr. Surg. Int.* 22 (2006) 224–227, <https://doi.org/10.1007/s00383-005-1624-1>.
- [6] I. Ben-Ami, N. Smorgick, J. Tovbin, N. Fuchs, R. Halperin, M. Pansky, Does intraoperative spillage of benign ovarian mucinous cystadenoma increase its recurrence rate? *Am. J. Obstet. Gynecol.* 202 (2010) e1–e5, <https://doi.org/10.1016/j.ajog.2009.10.854>, 142.
- [7] A.S. El-Agwany, Recurrent bilateral mucinous cystadenoma: laparoscopic ovarian cystectomy with review of literature, *Indian J. Surg. Oncol.* 9 (2018) 146–149, <https://doi.org/10.1007/s13193-018-0726-x>.
- [8] R.A. Agha, T. Franchi, C. Sohrabi, G. Mathew, for the SCARE Group, The SCARE 2020 guideline: updating consensus surgical CAse REport (SCARE) guidelines, *Int. J. Surg.* 84 (2020) 226–230.
- [9] H. Olesen, A.K. Eisum, Recurrent mucineous cystadenoma in an 11-year-old premenarchal girl, *Ugeskr. Laeger* 163 (2001) 6601–6602 [Danish].
- [10] T. Gotoh, N. Hayashi, S. Takeda, S. Itoyama, M. Takano, Y. Kikuchi, Synchronous mucinous adenocarcinoma of the endometrium and mucinous cystadenoma of bilateral ovaries presenting during fertility therapy, *Int. J. Gynecol. Cancer* 14 (2004) 169–171, <https://doi.org/10.1111/j.1048-891x.2004.014168.x>.
- [11] B. Baksu, A. Akyol, I. Davas, A. Yazgan, J. Ozgul, C. Tanik, Recurrent mucinous cystadenoma in a 20-year-old woman: was hysterectomy inevitable? *J. Obstet. Gynaecol. Res.* 32 (2006) 615–618, <https://doi.org/10.1111/j.1447-0756.2006.00453.x>.
- [12] S. Mittal, N. Gupta, A.K. Sharma, V. Dadhwal, Laparoscopic management of a large recurrent benign mucinous cystadenoma of the ovary, *Arch. Gynecol. Obstet.* 277 (2008) 379–380, <https://doi.org/10.1007/s00404-007-0556-5>.
- [13] E. Turkyilmaz, U. Korucuoglu, F. Kutlusoy, T. Efturk, H.T. Dogan, A. Onan, et al., Recurrent mucinous cystadenoma: a laparoscopic approach, *Arch. Gynecol. Obstet.* 279 (2009) 387–389, <https://doi.org/10.1007/s00404-008-0718-0>.
- [14] R.A. Cowan, E.N. Haber, F.R. Faucz, C.A. Stratakis, V. Gomez-Lobo, Mucinous cystadenoma in children and adolescents, *J. Pediatr. Adolesc. Gynecol.* 30 (2017) 495–498, <https://doi.org/10.1016/j.jpap.2017.02.001>.
- [15] Y. Mizrahi, E. Weiner, R. Keidar, R. Kerner, A. Golan, R. Sagiv, Intraoperative rupture of benign mucinous cystadenoma does not increase its recurrence rate, *Arch. Gynecol. Obstet.* 291 (2015) 1135–1139, <https://doi.org/10.1007/s00404-014-3543-7>.
- [16] J. Salat-Baroux, P. Merviel, F. Kuttann, Management of ovarian cysts, *BMJ* 313 (1996) 1098, <https://doi.org/10.1136/bmj.313.7065.1098>.