


3D Cube FLAIR plus HyperSense compressed sensing is superior to 2D T2WI FLAIR scanning regarding image quality, spatial resolution, detection rate for cortical microinfarcts

Tiefang Liu, MM^a, Yonghao Wang, MM^b, Zhengyang Xu, MM^a, Tao Wu, MM^c, Xiao Zang, MM^a, Meng Li, MM^a, Jinfeng Li, MD^{a,*} 

Abstract

3-dimension (3D) Cube isotropic volumetric magnetic resonance imaging (MRI) facilitates comprehensive recognition of microinfarcts while it takes long scanning time. HyperSense compressed sensing is an emerging technique for accelerating MRI acquisition to reduce scanning time, while its application along with 3D Cube MRI for microinfarcts is seldom reported. Therefore, this study aimed to investigate the efficiency of 3D Cube FLAIR plus HyperSense compressed sensing technique versus conventional 2-dimension (2D) FLAIR scanning in the detection of cortical microinfarcts (CMIs).

Totally 59 patients with cerebrovascular disease were enrolled then scanned by 3D Cube FLAIR plus HyperSense compressed sensing and 2D T2WI FLAIR sequences. The image quality scores, signal-to-noise ratio (SNR) for gray matter (GM), SNR for white matter (WM), their contrast-to-noise ratio (WM-to-GM CNR), detected number of CMIs were evaluated.

3D Cube FLAIR plus HyperSense showed a dramatically increased scores of uniformity, artifact, degree of lesion displacement, and overall image quality compared to 2D T2WI FLAIR. Meanwhile, it exhibited similar SNR_{wm} and SNR_{gm}, but a higher WM-to-GM contrast-to-noise ratio compared with 2D T2WI FLAIR. Furthermore, the scanning time of 3D Cube FLAIR plus HyperSense and 2D T2WI FLAIR were both set as 2.5 minutes. Encouragingly, 244 CMIs were detected by 3D Cube FLAIR plus HyperSense, which was higher compared to 2D T2WI FLAIR (106 detected CMIs).

3D Cube FLAIR plus HyperSense compressed sensing is superior to 2D T2WI FLAIR scanning regarding image quality, spatial resolution, detection rate for CMIs; meanwhile, it does not increase the scanning time. These findings may contribute to early detection and treatment of stroke.

Abbreviations: 2D = 2-dimension, 3D = 3-dimension, ARC = auto-calibrating reconstruction for cartesian, CMIs = cortical microinfarcts, CNR = contrast-to-noise ratio, ETL = echo train length, FA = flip angles, FSE = fast spin echo sequence, GM = gray matter, MRI = magnetic resonance imaging, SNR = signal-to-noise ratio, WM = white matter.

Keywords: 2D T2WI FLAIR, 3D Cube FLAIR, cortical microinfarcts, HyperSense compressed sensing, magnetic resonance imaging

1. Introduction

Stroke is a serious disease with high incidence, disability, mortality rates that threatens human health, which brings about potentially serious socioeconomic burdens and attracts increasing attentions globally.^[1] Recently, stroke management such as stroke workflow standardization, thrombolytic therapy, post-stroke rehabilitation, etc has been improved to a certain degree, which facilitates a better prognosis of stroke patients^{[2-4];}

however, the prevention and early identification of stroke risk is still a critical issue that affects stroke development and outcomes.^[5,6] Cortical infarcts are reported to be relatively prevalent in stroke patients, which contributes to increased disease risk, poststroke complications, and decreased cognitive dysfunction.^[7,8] Furthermore, along with the advancement of technology, the recognition of cortical microinfarcts (CMIs) is accessible, which correlates with delayed cognitive recovery and worse overall prognosis of cerebrovascular diseases such as

TL and YW contributed equally to this work.

The authors have no funding and conflicts of interest to disclose.

All data generated or analyzed during this study are included in this published article [and its supplementary information files].

Supplemental Digital Content is available for this article.

^a Department of Radiology, The First Medical Center of PLA General Hospital, Beijing, China, ^b Department of Ultrasound, The Eighth Medical Center of PLA General Hospital, Beijing, China, ^c GE Healthcare MR Enhanced Application Team, Beijing, China.

*Correspondence: Jinfeng Li, Department of Radiology, The First Medical Center of PLA General Hospital, No. 28 Fuxing Road, Haidian District, Beijing 100048, China (e-mail: lijing300184@163.com).

Copyright © 2022 the Author(s). Published by Wolters Kluwer Health, Inc. This is an open-access article distributed under the terms of the Creative Commons Attribution-Non Commercial License 4.0 (CCBY-NC), where it is permissible to download, share, remix, transform, and build up the work provided it is properly cited. The work cannot be used commercially without permission from the journal.

How to cite this article: Liu T, Wang Y, Xu Z, Wu T, Zang X, Li M, Li J. 3D Cube FLAIR plus HyperSense compressed sensing is superior to 2D T2WI FLAIR scanning regarding image quality, spatial resolution, detection rate for cortical microinfarcts. *Medicine* 2022;101:33(e28659).

Received: 5 February 2021 / Received in final form: 12 December 2021 / Accepted: 4 January 2022

<http://dx.doi.org/10.1097/MD.00000000000028659>

stroke.^[8-11] Therefore, early and accurate identification of CMIs may be in favor of the management of cerebrovascular diseases including stroke.

Magnetic resonance imaging (MRI) plays an irreplaceable role in routine brain examination because of its excellent soft tissue contrast and multi-sequence, multi-parameter, and multi-modal imaging; benefiting from which, MRI also plays an important role in identifying cerebrovascular diseases and brain space occupying lesions.^[12] Regarding microinfarcts recognition, conventional 2-dimension (2D) MRI is unable to display the microinfarcts precisely and comprehensively; so, 3-dimension (3D) Cube isotropic volumetric MRI technology is introduced, but its scanning time is much longer compared to conventional 2D MRI imaging, which has not been widely applied in clinical practice.^[13,14]

HyperSense compressed sensing is an emerging technique for accelerating MRI acquisition, it evacuates sampling scheme of the frequency domain and pseudo-random sampling scheme of the time domain, then utilizes non-linear iterative reconstruction technique to recover imaging data efficiently, to heavily decrease the scanning time; furthermore, it co-works with auto-calibrating reconstruction for cartesian (ARC), then high-frequency noise is filtered out to ensure high image quality.^[15,16] In a word, HyperSense compressed sensing reduces scanning time without affecting signal-to-noise ratio (SNR) and overcomes the shortage of 3D Cube MRI, while its application along with 3D Cube MRI for microinfarcts such as CMIs is seldom reported.

Therefore, the present study aimed to investigate the efficiency of 3D Cube FLAIR plus HyperSense compressed sensing technique versus conventional 2D FLAIR scanning in the detection of CMIs.

2. Methods

2.1. Subjects

A total of 59 patients with cerebrovascular disease who were admitted to our hospital from January to September 2019 were included in the study. There were 33 males and 26 females with a median age of 72.1years (range 59-89years). The study was approved by the Ethical Committee of our hospital, and written informed consent was obtained from each subject before the study. Patients who could not tolerate MRI were excluded.

2.2. Data acquisition

Magnetic resonance images were acquired using a 3.0 Tesla MR scanner (Discovery 750W 3.0T, GE Healthcare, Milwaukee) with a 32-channel head coil (GE Healthcare). The imaging parameters for coronal 3D Cube FLAIR plus HyperSense sequence were: reverse order, field of view = 220×198mm, matrix size = 256×256, slice thickness = 0.9mm, slice interval: 0mm, number of slice = 152, repetition time = 6302ms, echo time = 97.7ms, bandwidth = 150kHz, number of excitations = 1, acceleration factor = Asset2 + HS2, scan time = 2.5 minutes. The imaging parameters for coronal 2D T2WI FLAIR sequence were: reverse order, field of view=220×198mm, matrix size = 256×256, slice thickness = 5.0mm, slice interval: 1.0mm, number of slice = 24, repetition time = 9000ms, echo time = 138.4ms, bandwidth = 31.2kHz, number of excitations = 1, acceleration factor = Asset2, scan time = 2.5 minutes.

2.3. Assessments

After completing the scanning, all the images of coronal 3D Cube FLAIR plus HyperSense and coronal conventional 2D T2WI FLAIR sequences were transferred to an AW4.6 workstation. Subjective image quality evaluation was performed blinded by 2 radiologists with 10years of experience using a 5-point

scale to evaluate image uniformity, presence/absence of artifacts, the degree of small lesion displacement, and overall image quality, where higher score represented better quality, among which 0 indicated worse quality while 5. Objective image quality evaluation also was performed by 2 radiologists with 10 years of experience. The region of interests sized 10mm² were drawn within gray matter (GM), white matter (WM), and background noise regions on the 3D Cube FLAIR plus HyperSense and the 2D T2WI FLAIR images at the same level. Three region of interests were drawn in each area and averages were calculated. The SNR for WM and GM, and their contrast-to-noise ratio (CNR) were calculated according to the following formula: $SNR = SI/SDnoise$, $CNR = (SNR_{wm} - SNR_{gm})/SDnoise$, where SI_{wm} and SI_{gm} represents WM and GM signal intensity, respectively, and $SDnoise$ represents the standard deviation of the signal intensity of background noise.^[17] In addition, the number of CMIs detected by 3D Cube FLAIR plus HyperSense and the 2D T2WI FLAIR sequences were counted.

2.4. Statistical analysis

SPSS 17.0 (IBM) and GraphPad 7.01 (GraphPad) were used for statistical analysis and graph making, respectively. Data were presented as the mean ± standard deviation, and compared by paired t test. A kappa test was used to analyze the consistency in evaluations performed by 2 radiologists. $P < .05$ was considered as significant and marked as * in the images.

3. Results

3.1. Subjective evaluation

Generally, 3D Cube FLAIR plus HyperSense showed a dramatically higher overall image quality score compared to 2D T2WI FLAIR (Fig. 1). In subscales, 3D Cube FLAIR plus HyperSense also exhibited increased scores of uniformity, artifact, and degree of lesion displacement compared to 2D T2WI FLAIR (Fig. 1). Besides, the kappa value of image scores evaluated by 2 experienced radiologists was 0.892, which indicated good consistency.

3.2. Objective evaluation

3D Cube FLAIR plus HyperSense disclosed similar SNR_{wm} and SNR_{gm} compared to 2D T2WI FLAIR. However, encouragingly, 3D Cube FLAIR plus HyperSense achieved a higher WM-to-GM CNR compared with 2D T2WI FLAIR (Fig. 2). Furthermore,

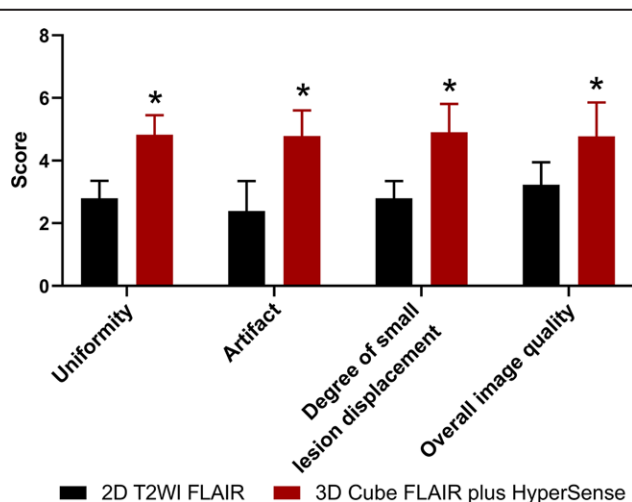


Figure 1. Scores of image quality. Scores of overall image quality, uniformity, artifact, and degree of small lesion displacement between 3D Cube FLAIR plus HyperSense and 2D T2WI FLAIR. 2D = 2-dimension, 3D = 3-dimension.

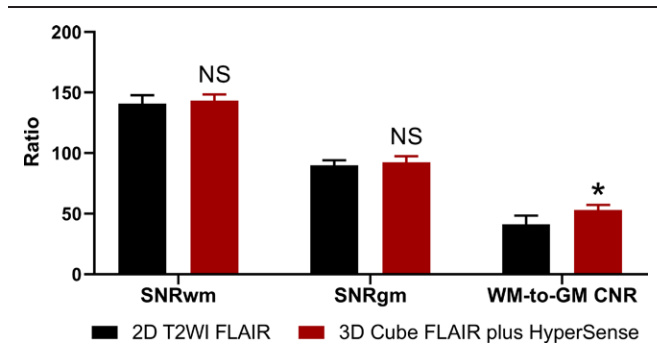


Figure 2. SNR and CNR. SNR_{wm}, SNR_{gm}, and WM-to-GM CNR between 3D Cube FLAIR plus HyperSense and 2D T2WI FLAIR. 2D = 2-dimension, 3D = 3-dimension, CNR = contrast-to-noise ratio, GM = gray matter, SNR = signal-to-noise ratio, WM = white matter.

the scanning time of 3D Cube FLAIR plus HyperSense and 2D T2WI FLAIR were both set as 2.5 minutes, indicating similar time cost.

3.3. CMIs detection

A total of 244 CMIs were detected by 3D Cube FLAIR plus HyperSense, which was higher compared to 2D T2WI FLAIR (106 detected CMIs), indicating 3D Cube FLAIR plus HyperSense was more sensitive in identifying CMIs. For instance: CMI was detected by 3D Cube FLAIR plus HyperSense (Fig. 3A), while was not identified by 2D T2WI FLAIR (Fig. 3B) in a patient; similarly, CMI was detected by 3D Cube FLAIR plus HyperSense (Fig. 3C), while was not identified by 2D T2WI FLAIR (Fig. 3D) in another patient.

3.4. Subgroup analyses

In females, scores of uniformity, artifact, degree of lesion displacement, and overall image quality were increased in 3D Cube FLAIR plus HyperSense group compared to 2D T2WI FLAIR group; meanwhile SNR_{wm} and WM-to-GM CNR were elevated, while SNR_{gm} was similar in 3D Cube FLAIR plus HyperSense group compared to 2D T2WI FLAIR group (Figure S1A-B, Supplemental Digital Content, <http://links.lww.com/MD/G637>). As in males, similar trends were observed as those in females, expect for that SNR_{wm} was of no difference between 3D Cube FLAIR plus HyperSense group and 2D T2WI FLAIR group (Figure S1C-D, Supplemental Digital Content, <http://links.lww.com/MD/G637>).

4. Discussion

CMIs are common findings in patients with stroke, and have attracted increasing attention. CMIs are closely related to dementia and cognitive decline. Studies have shown that CMIs contribute to cognitive impairment, gait disturbance and falls, abnormal movements, decline in executive and attention functions, slowing of information processing, depression, reduced speech fluency, deficits of delay recall, which ultimately affect the quality of life of patients. If cortical CMIs located in the frontal lobe can damage the pathway that connect the frontal lobe with cortical area, this pathway is considered to be related to executive and cognitive functions.^[18-20] At present, CMIs are classified in 2 subtypes, 1 type of CMIs presents as acute cognitive impairment with acute onset, and is accompanied by sensory, movement disorders, and ataxia syndrome. Another type of CMIs presents as progressive cognitive impairment with slow onset, speech and memory impairment, and even personality and mood changes can occur gradually, eventually leading to vascular dementia, which is often accompanied by skeletal

muscle and sphincter dysfunction, and seriously affects patients' quality of life. And the above clinical symptoms are related to the location and number of cortical infarcts.^[21] Therefore, early identification of the number and location of microinfarcts is particularly important for early diagnosis and treatment to slow disease progression.

MRI performed using conventional sequences, such as the 2D T2WI FLAIR sequences mentioned in this study, are the most important sequences used in brain imaging, which have the following advantages: fast imaging speed: fast spin echo sequence (FSE) with an echo train length (ETL) can greatly shorten scanning time in comparison with the spin echo sequence; RELATIVELY high SNR. However, there are several disadvantages of 2D T2WI FLAIR imaging: image blurring and low contrast ratio: a long ETL is associated with a decrease in contrast ratio because the later echoes are weaker, which are used to fill the periphery of the K space, directly resulting in image blurring, and lower contrast ratio^[22]; higher specific absorption rate: unlike the spin echo sequence, the FSE sequence uses successive 180° rephasing pulses to rephase the phases, multiple echoes are produced, which results in higher specific absorption rate; low spatial resolution: considering the scanning time, the size of phase-encoding matrix cannot be increased, and higher resolution cannot be achieved. In addition, due to the limits of hardware and interlayer interference, 2D slice thickness is difficult to reduce, if the slice thickness is excessively reduced, performance of gradients that used for slice selection needs to be greatly improved, and some MRI scanners do not meet the requirements. Furthermore, improved performance of slice select gradient will be subject to lower SNR and increase the appearance of peripheral nerve stimulations in patients. Therefore, the limits of 2D slice thickness may easily cause missed diagnosis of microinfarcts, especially the lesions with the maximum diameter that less than the slice thickness; significant artifacts: 2D imaging is prone to artifacts caused by CSF and vascular pulsation and phase errors.

Cube isotropic volumetric imaging technology is a new 3D FSE sequence with an extended echo train that has been developed in recent years. 3D FSE sequence with an extended echo train uses variable flip angles (FA) to extend the useable duration of an echo train, and minimize the blurring caused by long ETL for conventional 2D FSE sequence. At the beginning of the echo chain, the FA decreases rapidly, and the remaining longitudinal magnetization vector is decreased in the phase encoding direction. In the subsequent stage, the decreased longitudinal magnetization vector is flipped into the transverse plane by slowly increasing FA, which provide higher signal for the use of longer ETL.^[23,24] In addition, Cube is volumetric scanning, which can avoid the limits of 2D slice thickness. In our study, images were acquired with an isotropic voxel size of 0.9×0.9×0.9cm, and the spatial resolution is greatly improved. However, the increase in resolution also increases the scanning time. Cube sequence is compatible with a various acceleration technique, such as ARC, Cube sequence with ARC lead to the acceleration in both phase encoding direction and slice-selection direction. However, increased acceleration factor can cause reduction in SNR. Therefore, to ensure image quality, the scanning times of 3D FSE-Cube imaging is still longer than 2D imaging. Compressed sensing technique is a new imaging acceleration method can solve the above contradiction. HyperSense is a compressed sensing technique uses sparse sampling scheme in the frequency domain and pseudo-random sampling scheme in the time domain and uses non-linear iterative reconstruction technique to effectively recover imaging data, which can greatly reduce the scanning time. HyperSense can be compatible with ARC, high-frequency noise is filtered out to ensure high image quality.^[15] In our study, the scanning time of 3D Cube FLAIR plus HyperSense sequence was 2.5minutes, which is equal to the conventional 2D T2WI FLAIR sequence. 3D Cube FLAIR plus HyperSense sequence

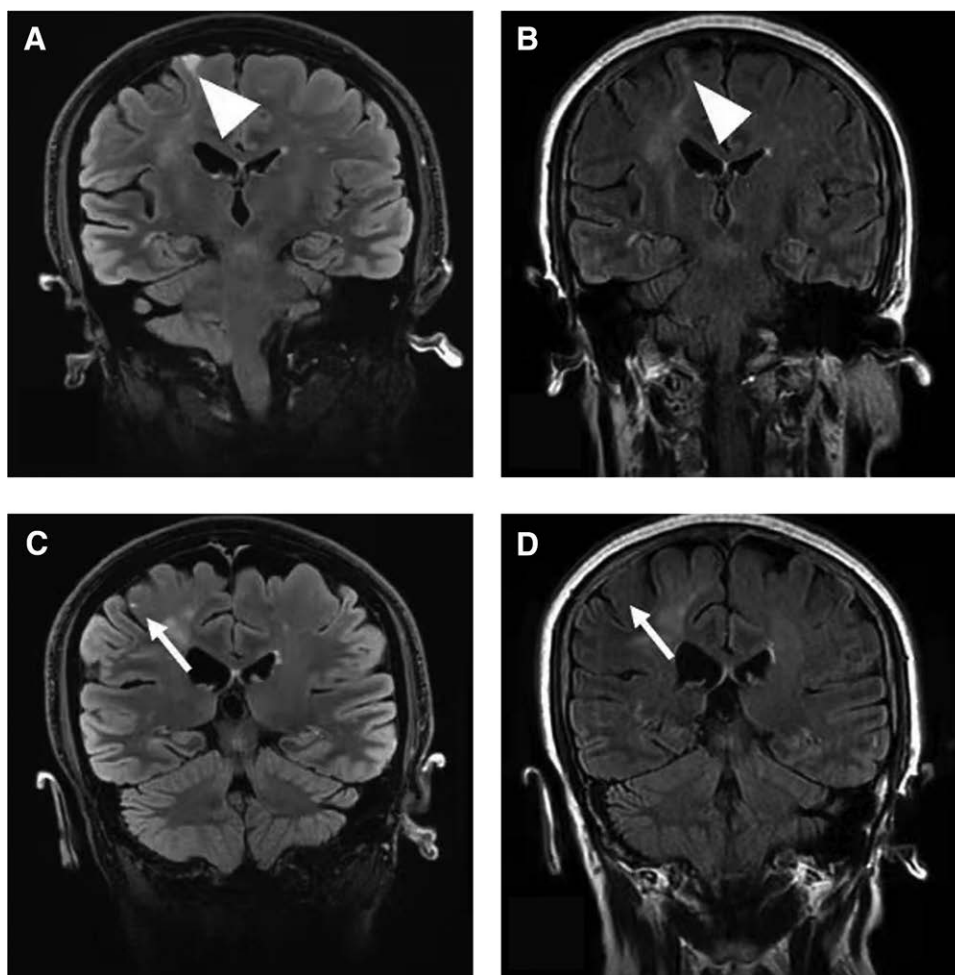


Figure 3. Detected CMIs. CMI was detected by 3D Cube FLAIR plus HyperSense (A), while was not identified by 2D T2WI FLAIR (B) in a patient. Similarly, CMI was detected by 3D Cube FLAIR plus HyperSense (C), while was not identified by 2D T2WI FLAIR (D) in another patient. These indicated 3D Cube FLAIR plus HyperSense was more sensitive to detect CMIs. 2D = 2-dimension, 3D = 3-dimension, CMI = cortical microinfarct.

with an isotropic voxel size of $0.9 \times 0.9 \times 0.9$ cm can reduce the missed diagnosis of CMI. Therefore, 3D Cube FLAIR plus HyperSense sequences have been replaced conventional 2D T2WI FLAIR sequences, and serve as routine MR sequences in our hospital.

There were some limitations in our study. Firstly, the sample size was relatively small, which reduced the statistical power, thus further larger sample-sized study could be performed to validate the findings. Secondly, only patients with cerebrovascular diseases were included in the current study, thus the findings could not be extended to other patients, which needed further exploration. Thirdly, inevitable patient movement during the examination might cause motion artifacts, thereby increasing unavoidable error. Fourthly, whether false positives and/or artifacts occurred between the 2 techniques in normal patients was not performed, which needed further exploration.

5. Conclusion

In summary, 3D Cube FLAIR plus HyperSense compressed sensing is superior to 2D T2WI FLAIR scanning regarding image quality, spatial resolution, detection rate for CMIs; meanwhile, it does not increase the scanning time.

Author contributions

Conceptualization: Tiefang Liu, Yonghao Wang, Jinfeng Li.

Data curation: Tiefang Liu, Yonghao Wang, Jinfeng Li.

Formal analysis: Tiefang Liu, Yonghao Wang, Zhengyang Xu, Jinfeng Li.

Investigation: Tiefang Liu, Yonghao Wang, Zhengyang Xu, Tao Wu, Xiao Zang, Meng Li, Jinfeng Li.

Methodology: Tiefang Liu, Yonghao Wang, Zhengyang Xu, Tao Wu.

Project administration: Tiefang Liu, Yonghao Wang, Jinfeng Li.

Resources: Tiefang Liu, Yonghao Wang, Zhengyang Xu, Tao Wu, Xiao Zang, Meng Li, Jinfeng Li.

Software: Tiefang Liu, Yonghao Wang, Zhengyang Xu, Xiao Zang, Meng Li, Jinfeng Li.

Supervision: Tiefang Liu, Yonghao Wang, Zhengyang Xu, Tao Wu, Meng Li, Jinfeng Li.

Validation: Tiefang Liu, Yonghao Wang, Zhengyang Xu, Tao Wu, Xiao Zang, Meng Li, Jinfeng Li.

Visualization: Tiefang Liu, Yonghao Wang, Zhengyang Xu, Tao Wu, Xiao Zang, Meng Li, Jinfeng Li.

Writing - original draft: Tiefang Liu, Yonghao Wang, Zhengyang Xu, Tao Wu, Xiao Zang, Meng Li, Jinfeng Li.

Writing - review & editing: Tiefang Liu, Yonghao Wang, Zhengyang Xu, Jinfeng Li.

References

- [1] Phipps MS, Cronin CA. Management of acute ischemic stroke. *BMJ* 2020;368:16983.

- [2] Hinsenfeld WH, de Ridder IR, van Oostenbrugge RJ, et al. Workflow intervals of endovascular acute stroke therapy during on- versus off-hours: the MR CLEAN Registry. *Stroke* 2019;50:2842–2850.
- [3] Shibata K, Hashimoto T, Miyazaki T, Miyazaki A, Nobe K. Thrombolytic therapy for acute ischemic stroke: past and future. *Curr Pharm Des* 2019;25:242–250.
- [4] Zhang T, Zhao J, Li X, et al. Chinese Stroke Association guidelines for clinical management of cerebrovascular disorders: executive summary and 2019 update of clinical management of stroke rehabilitation. *Stroke Vasc Neurol* 2020;5:250–259.
- [5] Chen YH, Sawan M. Trends and challenges of wearable multimodal technologies for stroke risk prediction. *Sensors (Basel)* 2021;21:460.
- [6] Jordan LC, Kassim AA, Wilkerson KL, Lee CA, Waddle SL, Donahue MJ. Using novel magnetic resonance imaging methods to predict stroke risk in individuals with sickle cell anemia. *Hematol Oncol Stem Cell Ther* 2020;13:76–84.
- [7] Heiss WD, Sobesky J, Smekal U, et al. Probability of cortical infarction predicted by flumazenil binding and diffusion-weighted imaging signal intensity: a comparative positron emission tomography/magnetic resonance imaging study in early ischemic stroke. *Stroke* 2004;35:1892–1898.
- [8] Jia J, Zhou A, Wei C, et al. The prevalence of mild cognitive impairment and its etiological subtypes in elderly Chinese. *Alzheimers Dement* 2014;10:439–447.
- [9] Wang Z, van Veluw SJ, Wong A, et al. Risk factors and cognitive relevance of cortical cerebral microinfarcts in patients with ischemic stroke or transient ischemic attack. *Stroke* 2016;47:2450–2455.
- [10] Sagnier S, Okubo G, Catheline G, et al. Chronic cortical cerebral microinfarcts slow down cognitive recovery after acute ischemic stroke. *Stroke* 2019;50:1430–1436.
- [11] Wei Y, Pu Y, Pan Y, et al. Cortical microinfarcts associated with worse outcomes in patients with acute ischemic stroke receiving endovascular treatment. *Stroke* 2020;51:2742–2751.
- [12] Putz F, Mengling V, Perrin R, et al. Magnetic resonance imaging for brain stereotactic radiotherapy: a review of requirements and pitfalls. *Strahlenther Onkol* 2020;196:444–456.
- [13] Takasugi J, Miwa K, Watanabe Y, et al. Cortical cerebral microinfarcts on 3T magnetic resonance imaging in patients with carotid artery stenosis. *Stroke* 2019;50:639–644.
- [14] Ueda Y, Satoh M, Tabei K, et al. Neuropsychological features of microbleeds and cortical microinfarct detected by high resolution magnetic resonance imaging. *J Alzheimers Dis* 2016;53:315–325.
- [15] Dafni H, Ronen SM. Dynamic nuclear polarization in metabolic imaging of metastasis: common sense, hypersense and compressed sensing. *Cancer Biomark* 2010;7:189–199.
- [16] Toledano-Massiah S, Sayadi A, de Boer R, et al. Accuracy of the compressed sensing accelerated 3D-FLAIR sequence for the detection of MS plaques at 3T. *AJNR Am J Neuroradiol* 2018;39:454–458.
- [17] Nowinski WL, Gupta V, Chan WY, Sitoh YY, Sim K. Use of normative distribution of gray to white matter ratio in orthogonal planes in human brain studies and computer-assisted neuroradiology. *Int J Comput Assist Radiol Surg* 2011;6:489–505.
- [18] Hartwell KJ, Hanlon CA, Li X, et al. Individualized real-time fMRI neurofeedback to attenuate craving in nicotine-dependent smokers. *J Psychiatry Neurosci* 2016;41:48–55.
- [19] Buetefisch CM. Role of the contralesional hemisphere in post-stroke recovery of upper extremity motor function. *Front Neurol* 2015; 6:214.
- [20] Diciotti S, Orsolini S, Salvadori E, et al. Resting state fMRI regional homogeneity correlates with cognition measures in subcortical vascular cognitive impairment. *J Neurol Sci* 2017;373:1–6.
- [21] Yan T, Yu JR, Zhang YP, Li T. Analysis on correlation of white matter lesion and lacunar infarction with vascular cognitive impairment. *Int J Clin Exp Med* 2015;8:14119–22.
- [22] Horiuchi S, Nozaki T, Tasaki A, et al. Comparison between isotropic 3-dimensional fat-suppressed T2-weighted fast spin echo (FSE) and conventional 2-dimensional fat-suppressed protonweighted FSE shoulder magnetic resonance imaging at 3-T in patients with shoulder pain. *J Comput Assist Tomogr* 2018;42: 559–565.
- [23] Busse RF, Hariharan H, Vu A, Brittain JH. Fast spin echo sequences with very long echo trains: design of variable refocusing flip angle schedules and generation of clinical T2 contrast. *Magn Reson Med* 2006;55:1030–1037.
- [24] Li ML, Xu YY, Hou B, et al. High-resolution intracranial vessel wall imaging using 3D CUBE T1 weighted sequence. *Eur J Radiol* 2016;85:803–807.