

Case Report

DUAL-energy computed tomography findings in a case of COVID-19

Hiromu Okano,^{ID} Ryosuke Furuya, Sena Mishima, Kosuke Shimada, Sayo Umeda, Takahiro Michishita, Sakura Minami,^{ID} Naoya Suzuki, Sho Hayakawa, Tsuyoshi Otsuka, and Hiroshi Miyazaki

Department of Emergency and Critical Care Medicine, National Hospital Organization Yokohama Medical Center, Yokohama-shi, Kanagawa, Japan

Background: COVID-19 pneumonia has lesions with a decreased blood flow. Dual-energy computed tomography is suitable to elucidate the pathogenesis of COVID-19 pneumonia because it highlights the blood flow changes in organs. We report the dual-energy computed tomography findings of a successfully treated case of COVID-19 pneumonia.

Case Presentation: An obese 49-year-old man with COVID-19 pneumonia was transferred from another hospital on day 11 after onset of illness. Although he was hypoxemic ($\text{PaO}_2/\text{FiO}_2 = 100$), tracheal intubation was not performed after anticipating difficulty in weaning from mechanical ventilation. Prone position therapy and nasal high flow therapy were administered, and the patient was discharged after his condition improved. Dual-energy computed tomography was performed three times during hospitalization, and it revealed improvement in the blood flow defect, unlike plain computed tomography that did not show much improvement.

Conclusion: Dual-energy computed tomography can assess perfusion in COVID-19 pneumonia in real time and may be able to predict its severity.

Key words: Computed X-ray tomography, COVID-19, COVID-19 diagnostic testing, dual-energy computed tomography, nasal high flow therapy

INTRODUCTION

COVID-19 pneumonia is associated with progressive respiratory failure despite maintenance of lung compliance. Processes other than alveolar damage have been suggested as the cause of this respiratory failure. The pathophysiology of the severe hypoxemia in COVID-19 pneumonia is gradually becoming clearer, and the involvement of microvascular thrombi in the lung because of coagulation disorders specific to SARS-CoV2 is attracting attention.¹

Corresponding: Hiromu Okano, MD, Department of Emergency and Critical Care Medicine, National Hospital Organization Yokohama Medical Center, 3-60-2 Harajyuku, Totsuka-ku, Yokohama-shi, Kanagawa, 245-8575, Japan. E-mail: okanohiromu0121@gmail.com

Received 4 Mar, 2021; accepted 6 Jun, 2021

Funding Information

No funding information provided.

Dual-energy computed tomography (DECT) has been suggested to be effective in visualizing the pathogenesis of COVID-19 pneumonia because of its ability to highlight changes in the blood flow in organs. In the present case, we report the clinical course of COVID-19 pneumonia using DECT.

CASE PRESENTATION

A 49-year-old man with a diagnosis of COVID-19 pneumonia was transferred to our hospital from another hospital on day 11 (day 1 after admission) for treatment of severe COVID-19 pneumonia. He was obese, with a body mass index (BMI) of 33, and had a history of cerebral infarction and hypertension. After admission, the patient was treated with nasal high flow therapy (NHFT), antiviral drugs (favipiravir, 3,600 mg/day on day 4 and 1,600 mg/day on days 5–14; remdesivir, 200 mg/day on day 15 and 100 mg/day on days 16–19), steroids (mPSL, 1,000 mg/day on days 11–13, 500 mg/day on days 14–16, and 250 mg/day on days 17–19; dexamethasone, 8 mg on

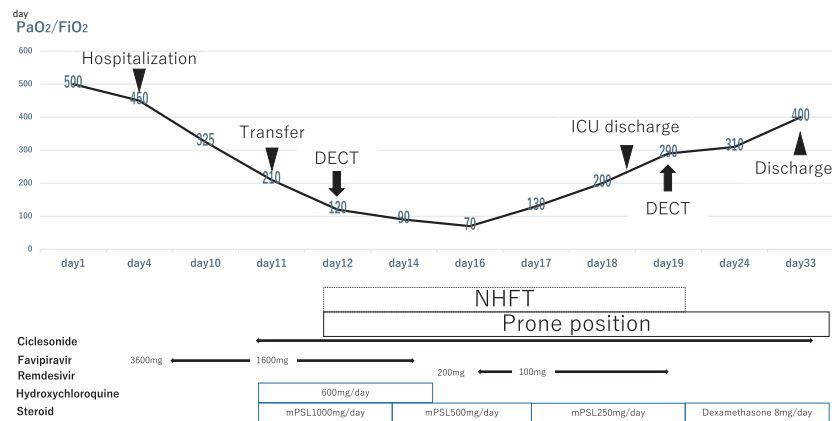


Figure 1. Clinical course of COVID-19 in our patient. The PaO₂/FiO₂ values at different time points are depicted. Dual-energy computed tomography (DECT) was performed on days 12 and 19 of the onset of the disease. The figure also presents the timeline of the administered therapies. NHFT, nasal high flow therapy.

days 20–33), hydroxychloroquine, 600 mg/day on days 11–15, and low-molecular-weight heparin 75 U/kg/day. On the day of admission, the PaO₂/FiO₂ (P/F ratio) was 210, but by day 12 after the onset of symptoms, the P/F ratio had worsened to 100. The course of treatment after admission and the findings of DECT are shown in Figures 1 and 2, respectively. On day 12 after the onset of the disease, plain CT showed diffuse frosted shadows, and DECT showed hypoperfusion consistent with the lesion. Based on the findings of DECT, we predicted that the possibility of further decrease in oxygen saturation was low. We did not choose tracheal intubation for respiratory management on considering the obesity of the patient and the anticipated difficulty in weaning the patient from artificial respiration. Thereafter,

oxygenation improved over time, the patient was discharged from the intensive care unit (ICU) on day 18, and oxygen therapy was completed on day 21. Follow-up DECT imaging was performed on day 19 (day 9 after admission) after the onset of the disease, and although the lesion did not improve on plain CT, DECT findings on days 12 and 19 showed apparent improvement in the blood flow deficit (Fig. 2). The patient's condition improved and he was discharged from the hospital on day 33.

The percentage of lesions on plain CT was calculated using the scientific image analysis program Image J (NIH, Bethesda, MD).^{2,3}

CT scans were obtained via a second-generation dual-source CT scanner (SOMATOM Definition Flash; Siemens

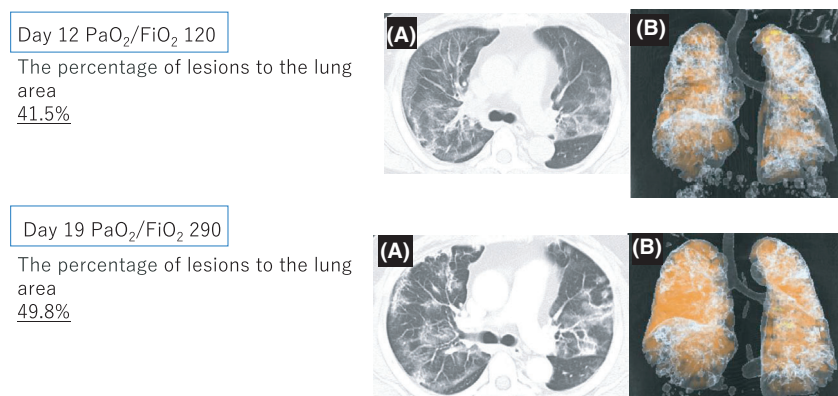


Figure 2. Series of (A) images obtained with plain computed tomography of the lung and (B) perfused blood volume images generated using dual-energy computed tomography, both performed on days 12 and 19 after onset of disease. The orange area in the figure indicates the presence of blood flow.

Healthcare, Forchheim, Germany) using the dual-energy scan mode. The following CT parameters were applied: detector collimation, 32 mm × 0.6 mm; 285 ms rotation time; pitch, 0.55; and tube voltage, 140 kV with a Tin (Sn) filter, and 100 kV. The slice thickness and increment were set to 2.0 and 1.4 mm, respectively. For all images, a medium-soft convolution kernel with iterative reconstruction (Q33 Iterative strength 2) was used.

DISCUSSION

DECT USES AN iodine contrast agent to acquire both low-energy and high-energy X-ray data, which increases tissue resolution and enables accurate tissue evaluation. In addition, noise can be minimized and artifacts can be reduced. The volume of perfused blood can be quantified and the presence or absence of perfusion injury can be investigated by material decomposition and generation of lung iodine distribution maps. The decrease in pulmonary perfusion can be visualized as decreased iodine uptake in the affected area and has been used to detect myocardial ischemia and to diagnose pulmonary embolism.⁴ In our hospital, contrast-enhanced CT is used for the evaluation of thrombosis, such as for pulmonary embolism in COVID-19 pneumonia.⁵ DECT, which is used to diagnose small pulmonary emboli that are difficult to identify on conventional contrast-enhanced CT, was used in this study for COVID-19 pneumonia. A previous DECT study in a COVID-19 patient has shown that pulmonary blood flow is severely reduced because of pulmonary vascular disease and thrombosis.⁶ However, it is not known how the DECT imaging changes relate to the clinical course. This is the first case report in Japan that evaluates the trends of perfusion of COVID-19 pneumonia using DECT and discusses its clinical considerations.

First, we consider the imaging findings. Several studies^{5,7} on COVID-19 using DECT have shown that the regions with ground-glass opacity have increased perfusion, whereas the consolidative and mixed opacity regions have low perfusion. It has been reported that pulmonary vascular injury because of COVID-19 causes loss of auto-regulation of perfusion as well as thrombosis *in situ*. In our case, among the features of COVID-19 pneumonia described above, only low perfusion findings were observed. It has been reported that the finding of segmental increased perfusion in DECT is suggestive of bacterial infection.⁸ However, blood and sputum cultures were negative in our case. This suggests that the autoregulation of blood vessels was maintained, which may have resulted in a favorable outcome and avoided tracheal intubation.

Second, we discuss the change in imaging findings: comparing the CT images from day 12 and day 19, DECT showed a decrease in blood flow deficit despite an increase in the percentage of lesions in plain CT (Fig. 2). The improvement in the clinical course of the patient's respiratory condition was consistent with the changes on DECT imaging.

The important inference drawn from this case was that the extent of the lesion visualized on a plain CT may not indicate the severity of COVID-19 pneumonia. DECT was useful for depicting the blood flow in the lung fields, because the degree of blood flow defect in the lung fields may be related to the severity of the disease.

CONCLUSION

IN THIS REPORT, we presented the DECT findings of a patient with COVID-19. Our observations suggest that DECT may be used to assess perfusion in COVID-19 pneumonia in real time and predict its severity.

DISCLOSURES

Approval of the research protocol: Not applicable.

Informed Consent: Written informed consent was obtained from the patient for publication.

Registry and the Registration No. of the study/trial: Not applicable.

Animal Studies: Not applicable.

Conflict of Interest: None declared.

ACKNOWLEDGEMENTS

WE WOULD LIKE to thank Editage (<http://www.editage.jp>) for English language editing.

REFERENCES

- 1 Connors JM, Levy JH. COVID-19 and its implications for thrombosis and anticoagulation. *Blood* 2020; 135: 2033–40.
- 2 Collins TJ. ImageJ for microscopy. *Biotechniques* 2007; 43: 25–30.
- 3 Schneider CA, Rasband WS, Eliceiri KW. NIH Image to ImageJ: 25 years of image analysis. *Nat. Methods*. 2012; 9: 671–5.
- 4 De Santis D, Eid M, De Cecco CN *et al*. Dual-energy computed tomography in cardiothoracic vascular imaging. *Radiol. Clin. North. Am.* 2018; 56: 521–34.
- 5 Lang M, Som A, Mendoza DP *et al*. Hypoxaemia related to COVID-19: vascular and perfusion abnormalities on dual-energy CT. *Lancet Infect. Dis.* 2020; 20: 1365–6.

- 6 Patel BV, Arachchilage DJ, Ridge CA *et al.* Pulmonary angiopathy in severe COVID-19: physiologic, imaging, and hematologic observations. *Am. J. Respir. Crit. Care. Med.* 2020; 202: 690–9.
- 7 Grillet F, Busse-Coté A, Calame P, Behr J, Delabrousse E, Aubry S. COVID-19 pneumonia: microvascular disease revealed on pulmonary dual-energy computed tomography angiography. *Quant. Imaging Med. Surg.* 2020; 10: 1852–62.
- 8 Otrakji A, Digumarthy SR, Lo Gullo R, Flores EJ, Shepard JA, Kalra MK. Dual-energy CT: spectrum of thoracic abnormalities. *Radiographics* 2016; 36: 38–52.